

Case report

## Transcatheter aortic valve replacement in a patient with renal cell carcinoma. A case report

**Marcel Pina Ciuffo Almeida<sup>1</sup>, Thalita Barbosa González<sup>1</sup>,  
Isabela Bispo Santos da Silva Costa<sup>1</sup>, Stéphanie Itala Rizk<sup>1</sup>,  
Bruna Morhy Borges Leal Assunção<sup>2</sup>, Henrique Barbosa Ribeiro<sup>2</sup>,  
Ludhmila Abrahão Hajjar<sup>1, 2</sup>**

<sup>1</sup> Department of Cardio-Oncology of the Cancer Institute of Sao Paulo, University of Sao Paulo

<sup>2</sup> Heart Institute of Sao Paulo, University of Sao Paulo

### Correspondence:

Ludhmila Abrahão Hajjar  
University of Sao Paulo  
Cancer Institute of Sao Paulo  
Dr Arnaldo avenue, 251  
Zip Code: 01246-000  
Sao Paulo, Brazil  
phone: +55 11 38933267  
fax: +55 11 38933274

### Received:

21.11.2019

### Accepted:

17.01.2020

DOI: 10.24292/01.OR.120210120

Copyright © Medical Education.

All rights reserved.

### ABSTRACT

The transcatheter aortic valve replacement (TAVR) is an important therapy for symptomatic patients with severe aortic stenosis who have an intermediate or high surgical risk. The profile of patients eligible for this therapy as first choice has changed over the last few years, with increasing indication even for patients who do not have surgical high risk. Severely ill and frail patients, elderly or patients with multiple clinical comorbidities, such as cancer might be considered for TAVR.

**Key words:** cardio-oncology, cancer, transcatheter aortic valve replacement

## INTRODUCTION

The average cancer patient survival has increased over the last decades, due to advances in cancer treatment. As a result, these patients are older and dealing with other health problems, especially cardiovascular disease [1]. In this context, severe aortic stenosis (AS) often represents a cause of concern, because its incidence rises with age and it is becoming more common to diagnose AS in cancer patients [2, 3].

## CASE PRESENTATION

A 72-year-old man was referred to the cardio-oncology service at the Cancer Institute due to dyspnea and chest pain a month ago. He was evaluated and classified according to his functional impairment in Karnofsky score 80 and the Eastern Cooperative Oncology Group (ECOG) grade 1. His past medical records revealed renal cell carcinoma (RCC) diagnosed in 2008 for which he was treated with a right radical nephrectomy. After 8 years of post-operative surveillance, metastatic lesions to bone, subcutaneous tissue and lymph nodes were diagnosed and treated with surgery, radiotherapy and sunitinib, a multi-targeted tyrosine kinase inhibitor with anti-VEGF (vascular endothelial growth factor) activity, according to clinical indication. In order to investigate the origin of the cardiovascular symptoms, a transthoracic echocardiography (TTE) was performed showing severe AS (fig. 1). A cardiac tomography was done to evaluate and measure vessels (fig. 2). Clinical risk scores were calculated for these patients: Euroscore II – mortality 1% and risk score of The Society of Thoracic Surgeons (STS) – mortality 1.22%. In this moment, the heart team decided to perform TAVR based on the presence of

FIGURE 1.

Baseline transthoracic echocardiography (TTE) measuring aortic transvalvular gradients and velocity. The mean gradient was 65 mmHg and aortic valve area by continuity equation was  $0.7 \text{ cm}^2$ .

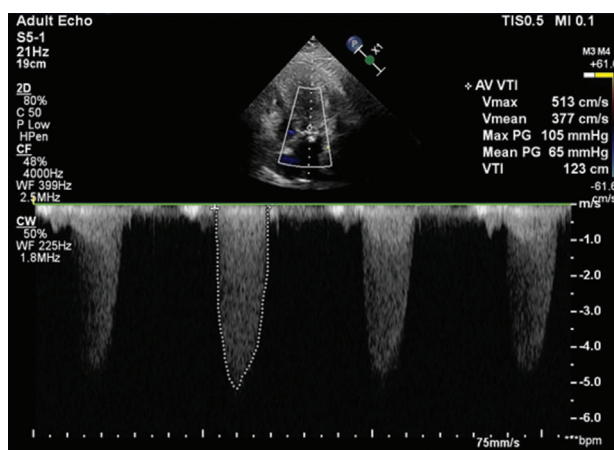
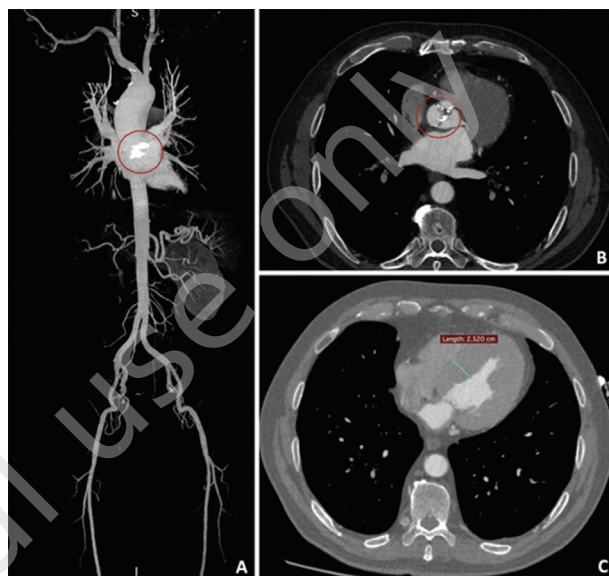


FIGURE 2.

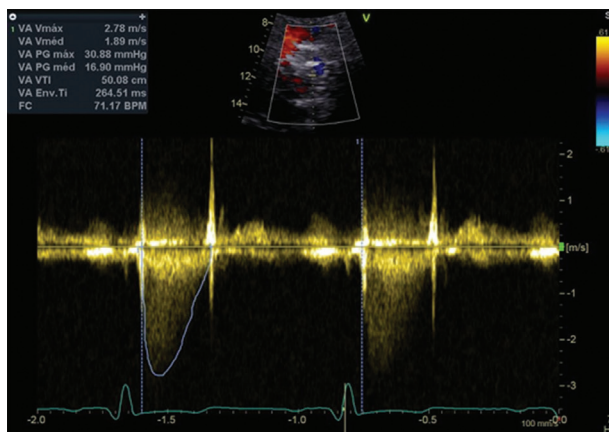
Computed tomography showing (A) 3D reconstruction; (B) calcified aortic valve; and (C) concentric hypertrophy of the left ventricle.



clinical comorbidities, and the procedure was successfully done on June 26<sup>th</sup>, 2019. A 26-mm Inovare valve was implanted under fluoroscopic guidance, using the transapical approach, without major complications. The patient was discharged 5 days after the procedure, just before a new TTE was conducted and revealed improvements in the aortic valve parameters (fig. 3).

FIGURE 3.

Transthoracic echocardiography post-TAVR showing a mean aortic valve gradient 16.9 mmHg.



## DISCUSSION

Surgical aortic valve replacement (SAVR) remains the gold standard therapy for symptomatic severe AS [4]. Fortunately, TAVR has been showing excellent results and reducing complication rates [5]. In the beginning, TAVR was indicated only for high-risk

surgical patients. Nowadays, advances in technology allowed the development of new evidence, expanding TAVR indications for a wider range of patients, regardless of their surgical risk, such as cancer patients, not unlike the case of the reported patient [6–8].

It is worth mentioning in this context that Watanabe et al. [6] evaluate midterm outcomes after TAVR in patients with severe AS and cancer concluding that this particular group of patients had similar outcomes and midterm survival rates compared with patients without cancer. In addition, Landes et al. [7] added data about long-term prognosis pointing out an increased 1-year mortality in cancer patients who underwent TAVR, mainly due to malignancy.

Therefore, TAVR has become an effective and non-inferior treatment option in comparison to SAVR with the advantage of being less invasive, allowing a shorter hospital length of stay and less cardiovascular events [5, 9]. For these reasons, one of the great advantages of performing TAVR in cancer patients is the possibility of early institution of aggressive cancer therapy in these

patients, which was often delayed or contraindicated without treatment of symptomatic and severe AS [6].

However, TAVR may have some limitations due to the risk of bleeding, thrombosis and infection [10]. In cancer patients we have special concerns about this, because generally they are immunocompromised and have a greater predisposition to develop thrombotic and hemorrhagic complications. Landes et al. [7] showed higher bleeding rates in cancer groups. Moreover, before performing TAVR we must take into account some particular features, for instance life expectancy, which should be more than 1 year after intervention, planned oncologic treatment (chemotherapy, radiotherapy or surgery), vascular access and functional status [11].

## CONCLUSION

TAVR is a recognized therapy for aortic stenosis. We report a success case of TAVR in a patient with advanced renal cancer. Due to the large and growing number of cancer survivors, more studies are warranted to better address the timing and best follow-up strategy for these patients.

## References

1. Schechter M, Balanescu DV, Donisan T et al. An update on the management and outcomes of cancer patients with severe aortic stenosis. *Catheter Cardiovasc Interv.* 2019; 94(3): 438-45.
2. Schofer N. Transcatheter Aortic Valve Replacement in Oncology Patients: Does it Make Sense? *JACC Cardiovasc Interv.* 2019; 12(1): 87-9.
3. Berkovitch A, Guetta V, Barbash IM et al. Favorable Short-Term and Long-Term Outcomes Among Patients With Prior History of Malignancy Undergoing Transcatheter Aortic Valve Implantation. *J Invasive Cardiol.* 2018; 30(3): 105-9.
4. Baumgartner H, Falk V, Bax JJ et al; ESC Scientific Document Group. 2017 ESC/EACTS Guidelines for the management of valvular heart disease. *Eur Heart J.* 2017; 38(36): 2739-91.
5. Mack MJ, Leon MB, Thourani VH et al; PARTNER 3 Investigators. Transcatheter Aortic-Valve Replacement with a Balloon-Expandable Valve in Low-Risk Patients. *N Engl J Med.* 2019; 380(18): 1695-705.
6. Watanabe Y, Kozuma K, Hioki H et al. Comparison of Results of Transcatheter Aortic Valve Implantation in Patients With Versus Without Active Cancer. *Am J Cardiol.* 2016; 118(4): 572-7.
7. Landes U, Iakobishvili Z, Vronsky D et al. Transcatheter Aortic Valve Replacement in Oncology Patients With Severe Aortic Stenosis. *JACC Cardiovasc Interv.* 2019; 12(1): 78-86.
8. Mangner N, Woitek FJ, Haussig S et al. Impact of active cancer disease on the outcome of patients undergoing transcatheter aortic valve replacement. *J Interv Cardiol.* 2018; 31(2): 188-96.
9. Reardon MJ, Van Mieghem NM, Popma JJ et al; SURTAVI Investigators. Surgical or Transcatheter Aortic Valve Replacement in Intermediate Risk Patients. *N Engl J Med.* 2017; 376(14): 1321-31.
10. Bourantas CV, Serruys PW. Evolution of transcatheter aortic valve replacement. *Circ Res.* 2014; 114(6): 1037-51.
11. Nishimura RA, Otto CM, Bonow RO et al. 2017 AHA/ACC Focused Update of the 2014 AHA/ACC Guideline for the Management of Patients With Valvular Heart Disease: A Report of the American College of Cardiology/American Heart Association Task Force on Clinical Practice Guidelines. *J Am Coll Cardiol.* 2017; 70(2): 252-89.

## Authors' contributions:

Marcel Pina Ciuffo Almeida, Isabela Bispo Santos da Silva Costa, Ludhmila Abrahão Hajjar: writing and reviewing. Thalita Barbosa González; Stéphanie Itala Rizk, Bruna Morhy Borges Leal Assunção, Henrique Barbosa Ribeiro: data collect. All the authors read and agreed to the submitted version.

## Conflict of interests:

None.

## Financial support:

None.

## Ethics:

The authors had full access to the data and take full responsibility for its integrity.

All authors have read and agreed with the content of the manuscript as written.

The paper complies with the Helsinki Declaration, EU Directives and harmonized requirements for biomedical journals.