

Case report

Seizure as first manifestation of endocarditis in a patient with metastatic pancreatic adenocarcinoma: a case report

Marcel Pina Ciuffo Almeida¹, Isabela Bispo Santos da Silva Costa¹, Maria Carolina Feres de Almeida¹, Cecília Beatriz Bittencourt Viana Cruz^{1,2}, Stéphanie Itala Rizk¹, Ludhmila Abrahão Hajjar^{1,2}

¹ Department of Cardio-Oncology of the Cancer Institute of São Paulo, University of São Paulo

² Heart Institute of São Paulo, University of São Paulo

Correspondence:

Ludhmila Abrahão Hajjar
University of São Paulo,
Cancer Institute of São Paulo and
Heart Institute of São Paulo
Dr Arnaldo avenue, 251 Zip Code:
01246-000, São Paulo, Brazil
phone: +55 11 38933267
fax: +55 11 38933274
e-mail: ludhmila@usp.br

Received:

24.11.2019

Accepted:

17.12.2019

DOI: 10.24292/01.OR.419171219

Copyright © Medical Education.

All rights reserved.

ABSTRACT

Nonbacterial thrombotic endocarditis is a potentially overlooked condition that involves the formation of sterile fibrin vegetations on heart valve leaflets in cancer patients. This condition can lead to valvular dysfunction, heart failure and systemic embolization. The pathogenesis depends on hypercoagulable states which are common in malignancy scenarios. Diagnosis requires the presence of valvular vegetations and the absence of infection.

Key words: nonbacterial thrombotic endocarditis, cancer, cardio-oncology

INTRODUCTION

Nonbacterial thrombotic endocarditis (NBTE) is a rare condition frequently associated with malignancy [1]. Cancer patients are usually immunocompromised and often need a central venous catheter for chemotherapy which increases their chances of acquiring endocarditis, both infectious and thrombotic. In addition, these patients can present atypical manifestations of endocarditis, making the diagnosis more challenging [2].

CASE REPORT

A 46-year-old man diagnosed with metastatic pancreatic adenocarcinoma, with Karnofsky Performance Status of 70 and Eastern Cooperative Oncology Group (ECOG) grade 2 presented to the emergency department with first episode of seizure just before chemotherapy with gemcitabine plus paclitaxel. After initial medical support, a brain computed tomography (CT) excluded intracranial bleeding. In addition, brain magnetic resonance images (MRI) were performed revealing ischemic lesions probably due to cardiac embolism (fig. 1). Hence, in order to investigate the origin of these lesions in central nervous system (CNS), a transesophageal echocardiogram (TEE) was requested and showed two slightly mobile echogenic foci in native mitral valve associated with moderate mitral regurgitation (fig. 2). Blood cultures were drawn and antibiotic treatment was initiated for suspected bacterial endocarditis. Blood cultures and serologic tests for fastidious and intracellular microorganisms were negative. Even though the histopathological examination was not performed, the hypothesis of NBTE was reinforced and the patient was kept under anticoagulation with low molecular weight heparin and antibiotics were withdrawn. Patient had a good clinical evolution without seizures, focal deficits or heart failure.

FIGURE 1.
Brain MRI.

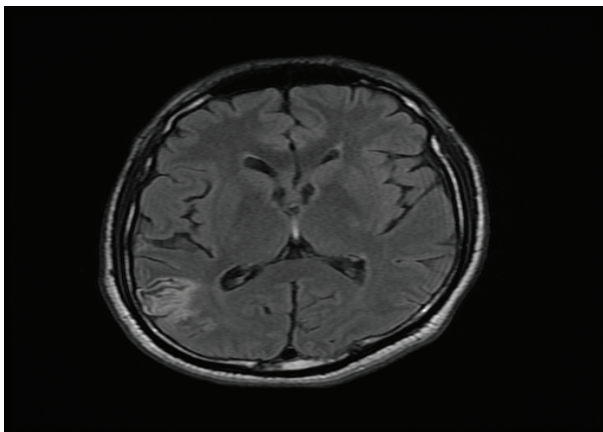
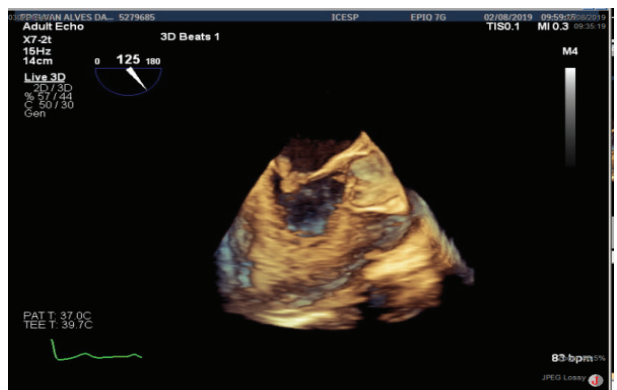
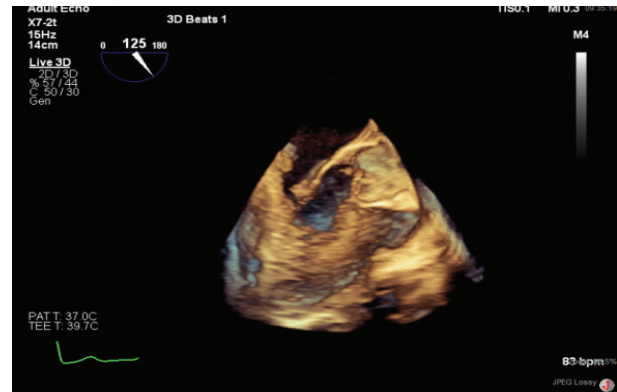


FIGURE 2.

Transesophageal echocardiogram showing a mobile echogenic foci in native mitral valve (A) opened and (B) closed.



DISCUSSION

Nonbacterial thrombotic endocarditis is commonly associated with hypercoagulability which may be part of the clinical spectrum of paraneoplastic syndrome and plays a critical role in patient outcome. From this perspective, we should emphasize the association between NBTE and cancer because it might be more frequent than expected [3]. Highlighting the tendency towards clot formation in the arterial part of cardiovascular system, Seok et al. performed transcranial Doppler and D-dimer analysis in cancer patients with cryptogenic stroke. Their results revealed not only higher embolic signals, but also increased D-dimer levels, reinforcing the prothrombotic condition in cancer scenario [4]. Of further note, Deppisch et al. reported an autopsy series performed during a 10-year period with 65 cases of NBTE and 51 of them were associated with malignancy, with adenocarcinoma as the most frequent histologic type identified [5].

Classically, the absence of bloodstream bacterial infection is the cornerstone of NBTE which affects mainly left-sided heart valves, specially mitral valve [1, 2, 6]. NBTE has been reported in patients with a wide age range and no gender distinction. Moreover, the incidence of systemic embolization also varies depending on the

population studied and features such as underlying malignancy [3, 5]. The clinical spectrum of these events and associated complications includes deep vein thrombosis, pulmonary embolism, CNS embolization, disseminated intravascular coagulation and thrombotic microangiopathy [7]. Once presented, these systemic embolic events are the main cause of mortality among patients [3, 8].

In terms of diagnosis, TEE is the preferred imaging modality to detect vegetations [2]. It's important to perform platelet count and coagulation tests, especially in those undergoing chemotherapy. In the presence of other clinical manifestations, some additional tests may be necessary such as chest and brain computed tomographies to evaluate systemic embolic events.

Indeed, in terms of thromboembolic complications, stroke is the main cause of concern due to its association with worse prognosis. As we know, the incidence of stroke is increased in cancer patients in comparison to overall population [9, 10]. In order to clarify the aforementioned relationship, a large population-based cohort study was performed including 52,089 patients with lung cancer and pointed out a higher risk of ischemic stroke in the cancer group (HR 1.4; CI 95% 1.3–1.5) [9, 10].

Concerning the treatment of NBTE, anticoagulation therapy is the most important intervention and surgical valve replacement should be considered only in selected cases [3, 5]. In cancer patients the anticoagulation therapy should be individualized since this population have a high risk for both thrombosis and bleeding [11, 12].

Considering oncology population, warfarin tends to show worse outcomes and unpredictable anticoagulation effects in comparison to non-cancer patients [13]. Poor oral intake, nausea and vomiting due to chemotherapy, coagulopathies and fluctuation in kidney and liver functions are some of the reasons for weak warfarin performance during cancer treatment [10].

On the other hand, therapy with direct oral anticoagulants (DOACs) have emerged as an alternative anticoagulation treatment to prevent thromboembolic complications in atrial fibrillation (AF). Nowadays, DOACs are extensively used as their efficacy over Warfarin has been proved in major trials (RE-LY, ARISTOTLE, ROCKET AF and ENGAGE AF) [14–17] and as laboratory monitoring is not required during treatment with these drugs.

Some recent studies suggest that on prevention of thromboembolic events in AF patients with malignancy, DOACs seem to be at least as effective and safe as conventional anticoagulant treatment with vitamin K antagonists (VKAs) [18, 19]. Moreover, drug-to-drug interactions during chemotherapy and higher rates of bleeding in the gastrointestinal cancers are some of the concerns with DOACs in need of further investigation.

SUMMARY

The prognosis of NBTE is often poor not only for the disease itself, but also due to its association with advanced malignancy. In order to increase detection rates, we should maintain a high level of clinical suspicion. Anticoagulation and control of the underlying disease are the pillars of the treatment.

References

1. Moțățăianu A, Maier S, Gothard A et al. Severe Fatal Systemic Embolism Due to Non-Bacterial Thrombotic Endocarditis as the Initial Manifestation of Gastric Adenocarcinoma: Case Report. *J Crit Care Med.* 2018; 4(2): 68-73.
2. Liu J, Frishman WH. Nonbacterial Thrombotic Endocarditis: Pathogenesis, Diagnosis, and Management. *Cardiol Rev.* 2016; 24(5): 244-7.
3. el-Shami K, Griffiths E, Streiff M. Nonbacterial thrombotic endocarditis in cancer patients: pathogenesis, diagnosis, and treatment. *Oncologist.* 2007; 12(5): 518-23.
4. Seok JM, Kim SG, Kim JW et al. Coagulopathy and embolic signal in cancer patients with ischemic stroke. *Ann Neurol.* 2010; 68(2): 213-9.
5. Deppisch LM, Fayemi AO. Non-bacterial thrombotic endocarditis: clinicopathologic correlations. *Am Heart J.* 1976; 92(6): 723-9.
6. Sia CH, Lim JS, Poh KK et al. A classical case of non-bacterial thrombotic endocarditis from pancreatic adenocarcinoma presenting as multiple strokes, myocardial infarction and acute limb ischaemia. *Oxf Med Case Reports.* 2016; 2016(11): omw084.
7. Goldenberg N, Kahn SR, Solymoss S. Markers of coagulation and angiogenesis in cancer-associated venous thromboembolism. *J Clin Oncol.* 2003; 21(22): 4194-9.
8. Chen X, Chen SD, Dong Y et al. Patent foramen ovale closure for patients with cryptogenic stroke: A systematic review and comprehensive meta-analysis of 5 randomized controlled trials and 14 observational studies. *CNS Neurosci Ther.* 2018; 24(10): 853-62.
9. Chen PC, Muo CH, Lee YT et al. Lung cancer and incidence of stroke: a population-based cohort study. *Stroke.* 2011; 42(11): 3034-9.
10. Fitzpatrick T, Carrier M, Le Gal G. Cancer, atrial fibrillation, and stroke. *Thromb Res.* 2017; 155: 101-5.
11. Short NJ, Connors JM. New oral anticoagulants and the cancer patient. *Oncologist.* 2014; 19(1): 82-93.
12. Prandoni P, Lensing AW, Piccioli A et al. Recurrent venous thromboembolism and bleeding complications during anticoagulant treatment in patients with cancer and venous thrombosis. *Blood.* 2002; 100(10): 3484-8.
13. Mery B, Guichard JB, Guy JB et al. Atrial fibrillation in cancer patients: Hindsight, insight and foresight. *Int J Cardiol.* 2017; 240: 196-202.
14. Connolly SJ, Ezekowitz MD, Yusuf S et al. RE-LY Steering Committee and Investigators. Dabigatran versus warfarin in patients with atrial fibrillation. *N Engl J Med.* 2009; 361(12): 1139-51.
15. Granger CB, Alexander JH, McMurray JJ et al. ARISTOTLE Committees and Investigators. Apixaban versus warfarin in patients with atrial fibrillation. *N Engl J Med.* 2011; 365(11): 981-92.

16. Patel MR, Mahaffey KW, Garg J et al; ROCKET AF Investigators. Rivaroxaban versus warfarin in nonvalvular atrial fibrillation. *N Engl J Med.* 2011; 365(10): 883-91.
17. Giugliano RP, Ruff CT, Braunwald E et al; ENGAGE AF-TIMI 48 Investigators. Edoxaban versus warfarin in patients with atrial fibrillation. *N Engl J Med.* 2013; 369(22): 2093-104.
18. Russo V, Bottino R, Rago A et al. Atrial Fibrillation and Malignancy: The Clinical Performance of Non-Vitamin K Oral Anticoagulants-A Systematic Review. *Semin Thromb Hemost.* 2019; 45(2): 205-14.
19. Melloni C, Dunning A, Granger CB et al. Efficacy and Safety of Apixaban Versus Warfarin in Patients with Atrial Fibrillation and a History of Cancer: Insights from the ARISTOTLE Trial. *Am J Med.* 2017;130(12): 1440-8.e1.

Authors' contributions:

Marcel Pina Ciuffo Almeida, Isabela Bispo Santos da Silva Costa, Ludhmila Abrahão Hajjar: writing and reviewing.
Maria Carolina Feres de Almeida, Cecília Beatriz Bittencourt Viana Cruz, Stéphanie Itala Rizk: data collect.
All the authors read and agreed to the submitted version.

Conflict of interests:

None.

Financial support:

None.

Ethics:

The authors had full access to the data and take full responsibility for its integrity.
All authors have read and agreed with the content of the manuscript as written.
The paper complies with the Helsinki Declaration, EU Directives and harmonized requirements for biomedical journals.