

Case report

## Stomach metastasis from breast cancer- -mimicking linitis plastica

**Katarzyna Czerko<sup>1</sup>, Michał Ostrowski<sup>2</sup>, Lubomir Bodnar<sup>1,3</sup>**

<sup>1</sup> Oncology Center in Siedlce, Mazovian Provincial Hospital in Siedlce

<sup>2</sup> ALAB plus, Laboratory of Pathomorphology, Warsaw

<sup>3</sup> Faculty of Medical and Health Sciences, Siedlce University of Natural Sciences and Humanities, Siedlce, Poland

### Correspondence:

Katarzyna Czerko  
Oncology Center in Siedlce,  
Mazovian Provincial Hospital in Siedlce  
08-110 Siedlce, ul. Poniatowskiego 26  
e-mail: k.czerko@interia.pl

### Received:

15.09.2022

### Accepted:

30.09.2022

DOI: 10.24292/01.OR.123300922

Copyright © Medical Education.

All rights reserved.

### ABSTRACT

We report a rare case of metastatic gastric cancer from invasive carcinoma of the breast (BC) as the first symptom of disease-mimicking primary gastric linitis plastica.

**Key words:** breast cancer, gastric metastases

Breast cancer is a heterogeneous disease [1]. It includes many histological subtypes, which differ in their course and prognosis [2]. Correctly made histopathological diagnosis plays a key role. We report a rare case of metastatic gastric cancer from invasive carcinoma of the breast (BC) as the first symptom of disease-mimicking primary gastric linitis plastica.

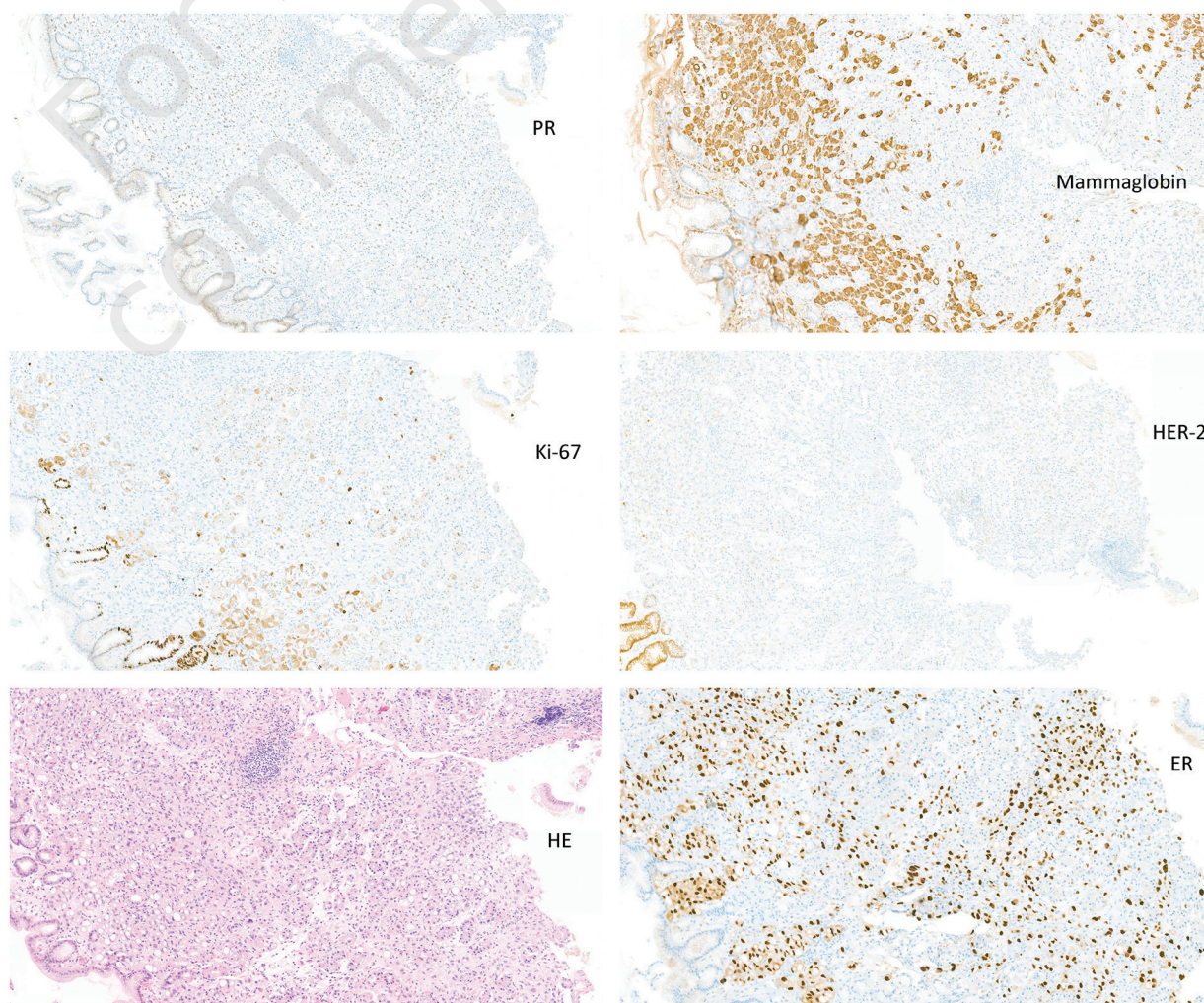
A 64-year-old woman reported to the outpatient clinic in January 2022 due to gastric cancer. She was diagnosed in the department of surgery at the district hospital, where she was admitted for vomiting and abdominal pain. The gastroscopy described a rigid stomach and the fundus mucosa had numerous ulcerations. The histopathological examination revealed G3 adenocarcinoma, diffuse type, HER2-negative.

13 years ago she had undergone a mastectomy and axillary lymphadenectomy for invasive ductal carcinoma after neoadjuvant

chemotherapy (six courses of docetaxel + doxorubicin in standard doses). Primary disease stage was cT4N0M0, and the histopathological report showed invasive ductal carcinoma G2 with expression: 70% oestrogen receptor (ER), 80% progesterone receptor (PR), and no human epidermal growth factor receptor 2 (HER2). She then received adjuvant radiotherapy, followed by 5 years of tamoxifen, with no signs of recurrence.

In the outpatient clinic, she reported fever of unknown origin, lack of appetite, and abdominal pain. Eastern Cooperative Oncology Group (ECOG) performance status (PS) was 2. Physical exam showed a tumour near the nipple of the left breast, about 1 cm in diameter, without regional lymph node enlargement. Mammography of the left breast showed 10 × 17 mm diameter lesions (BI-RADS4). Computed tomography (CT) scan revealed 15 × 5 mm thickening of the pleura on the left side, with a small amount of fluid in both pleural cavities, as well as a thick 10 mm stiff wall

**Figure 1.** HE (haematoxylin and eosin) staining and immunohistochemistry analysis of the gastric infiltration (positive for mammaglobin, Ki-67, ER, PR and negative for HER2).



in the stomach, significant ascites, and single, small osteolytic changes – suspicious for metastases in the pelvic bones.

The patient was admitted to the Department of Clinical Oncology, where due to symptoms of sub-obstruction at a ECOG PS 2, she received the first cycle of the FOLFOX 6 regimen (oxaliplatin + 5-fluorouracil + leucovorin) in standard doses.

The patient was readmitted for the second course of chemotherapy at ECOG PS 3. We obtained a histopathological report of the left breast biopsy that revealed infiltrating BC, NOS, luminal B, and HER2-negative subtypes (ER 3+ in 100% of cells, PR 1+ in single cells, HER2-negative, Ki-67 < 15%). With all the patient's clinical data available (except data on previously diagnosed BC), the primary histopathological diagnosis of gastric infiltration was verified based on metastatic BC, luminal B, and HER2-negative. The patient qualified for palliative hormone therapy with letrozole.

After one month of therapy, ECOG PS improved to 1 and a partial regression of the left breast tumour was observed. An improvement in well-being was also observed, and fever and abdominal pain subsided. After 3 months of letrozole therapy, CT showed a reduction in changes measurable within the limits of disease stabilization according to RECIST 1.1.

In the autopsy material of patients who died due to metastatic BC, 11% to 35% of metastases to the gastrointestinal tract were found, most often to the stomach, with a frequency of 3% to 18% [3–5]. In the described case, an attempt was made to use chemotherapy, which did not bring the expected effect. Thanks to the vigilance of the pathologist and the cooperation with the oncologist, the original diagnosis was verified, which significantly influenced further therapeutic procedures and the fate of the patient.

## References

1. Budny A, Starosławska E, Budny B et al. Epidemiology and diagnosis of breast cancer. *Pol Merkur Lekarski*. 2019; XLVI(275): 195-204.
2. Oraczewski R, Czerniawska-Meler M, Korzeniewicz M et al. Prognostic value of lymphocyte-related systemic inflammatory biomarkers in triple negative breast cancer. *OncoReview*. 2022; 2(46): 25-4.
3. Reiman T, Butts CA. Upper gastrointestinal bleeding as a metastatic manifestation of breast cancer: a case report and review of the literature. *Can J Gastroenterol*. 2001; 15: 67-71.
4. Yagi Y, Sasaki S, Yoshikawa A et al. Metastatic gastric carcinoma from breast cancer mimicking primary linitis plastica: A case report. *Oncol Lett*. 2015; 10: 3483-7.
5. Ricciuti B, Leonardi GC, Ravaioli N et al. Ductal Breast Carcinoma Metastatic to the Stomach Resembling Primary Linitis Plastica in a Male Patient. *J Breast Cancer*. 2016; 19: 324-9.

## Authors' contributions:

All authors actively participated in writing this work. All authors have read and accepted the manuscript.

## Conflict of interests:

Authors declare to have no conflict of interest.

## Financial support:

This research has not been funded by a third party.

## Ethics:

The authors had full access to the data and take full responsibility for its integrity.

All authors have read and agreed with the content of the manuscript as written.

The paper complies with the Helsinki Declaration, EU Directives and harmonized requirements for biomedical journals.