

Case report

Asymptomatic bladder leiomyoma: a report of three cases treated with minimal invasive techniques and a review of literature

Maciej Przudzik, Maria Derkaczew, Mirosław Łesiów, Marek Roslan

Department of Urology, Faculty of Medicine, University of Warmia and Mazury, Olsztyn, Poland

ABSTRACT

Introduction: Bladder leiomyoma is a very rare neoplasm and are estimated at about < 0.5% of all urinary bladder tumors. Most patients complain of lower urinary track symptoms. In 20% of cases patients remain asymptomatic.

Objective: The aim of this study was to investigate the topic of bladder leiomyomas, present our experience in the management of this neoplasm and review the published data concerning this rare entity.

Material and methods: From March 2018 to February 2021 three patients (2 females, 1 male) aged 39 to 58 years (mean 49.3 years) were treated for bladder leiomyoma in our center.

Results: Two patients underwent en bloc transurethral resection of bladder tumor and one had laparoscopic partial cystectomy. Tumors were located in favourable positions with the mean diameter of 37.67 mm. The mean operative time was 46.67 min (range from 15 to 95 min). At the mean follow-up time of 36 months. None of our patients had a recurrence of bladder leiomyoma.

Conclusions: Properly performed removal of bladder leiomyoma gives satisfactory results. Transurethral resection of bladder tumor is the gold standard of treatment, highly valued for its safety and minimal invasiveness, however in cases of unfavourable located or large tumors laparoscopic approach or EBRT with defragmentation or morcellation may be preferred.

Key words: bladder, leiomyoma, EBRT, laparoscopic partial cystectomy

Correspondence:

Maciej Przudzik
Department of Urology, Faculty
of Medicine, University of Warmia
and Mazury, Olsztyn, Poland
10-228 Olsztyn, al. Wojska Polskiego 37
e-mail: przudzik@gmail.com

Received:

15.09.2022

Accepted:

30.09.2022

DOI: 10.24292/01.OR.123301922

Copyright © Medical Education.

All rights reserved.

INTRODUCTION

Leiomyoma is a common benign tumor generally located in the uterus [1]. Tumors found in the urinary bladder are usually epithelial in origin and mesenchymal neoplasms are significantly less frequent and estimated at 1% to 5% of all tumors reported in this location [2–4]. The occurrence of leiomyoma in the bladder is quite a rare phenomenon, although it is the most common benign mesenchymal neoplasm of this organ, estimated at about < 0.5% of all bladder tumors and one-third of all mesenchymal ones [1, 4–6].

These tumors are most frequently found in young and middle-aged patients [7].

Leiomyomas are asymptomatic in approximately 20% of cases. Symptomatic patients often complain of lower urinary tract symptoms (LUTS) and obstructive or irritative symptoms [2, 8–10].

Methods used for the detection of lesions located in the urinary bladder consist in cystoscopy, ultrasound, computed tomography (CT) and magnetic resonance imaging (MRI) [5, 8].

The ultrasound image of leiomyoma is characteristic, i.e., it shows a homogenous regular smooth lesion with peripheral hyper-echogenicity [8, 11, 12]. The cystoscopic image is also very distinctive, showing a moveable, smooth submucosal mass [4, 8].

The location of leiomyomas is the basis for their classification into three types: endovesical, intramural and extravesical [1]. Contrary to endovesical tumors, the intramural and extravesical types are rarely symptomatic [2].

Complete tumor removal is the best therapeutic method which is associated with good outcomes [3, 10].

Considering the location and size of lesion, the most advantageous operative method may be selected. Smaller tumors, which do not obstruct the entry to the bladder may be removed via transurethral resection, while open surgery is the best option in bigger lesions situated in unfavorable locations [11].

We present three cases of bladder leiomyomas and a review of related literature.

OBJECTIVE

The aim of this study was to investigate the topic of bladder leiomyomas, present our experience in the management of this

neoplasm and review the published data concerning this rare entity.

MATERIAL AND METHODS

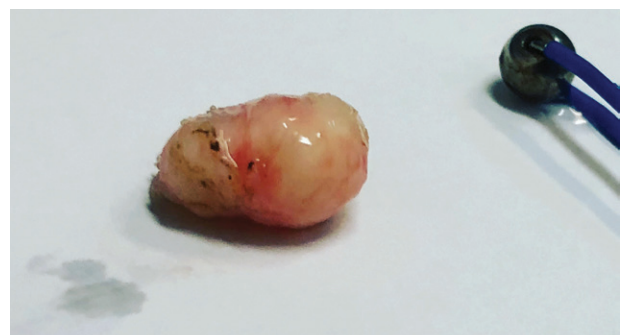We analyzed the medical records of three patients with the diagnosis of urinary bladder leiomyomas. They were treated in our clinic and the analyses were conducted between March 2018 and February 2021. We collected data including the patient's age, sex, symptoms, performed diagnostic examinations, location and size of the mass found in the urinary bladder, type of surgery selected, operating time, occurrence of possible complications, postoperative hospitalization time, follow-up time and the possible recurrence of the disease. PubMed and Google Scholar databases were used in order to search for literature concerning this issue.

RESULTS

Case report 1

A 58-year-old woman was admitted to our urology department due to the incidental finding of bladder tumor during a routine ultrasound examination. The lesion was 1.5 cm in diameter. The patient had no symptoms and the test results were normal. Cystoscopy showed a protruding fragment of the mucosa near the left ureteric orifice. The lesion was about 15 mm in length. The tumor presented as a moveable submucosal mass. The patient underwent en bloc transurethral resection of bladder tumor (EBRT) with the complete removal of leiomyoma (fig. 1). The operation time was 15 minutes and the tumor was removed intact. The patient was discharged 8 hours after the procedure. During the 4-year follow-up there was no evidence of recurrence.

Figure 1. Case 1. Specimen of the bladder leiomyoma after EBRT.



Case report 2

A 51-year-old woman was referred to our urology department for elective surgery. She denied having any irritative or obstructive

voiding symptoms. Her surgical history analysis revealed laparoscopic uterine fibroid removal in 2001 and hysterectomy in 2007. A lesion was detected incidentally during a routine ultrasound examination. CT and MRI showed a 40 × 26 × 28 mm mass located on the anterior bladder wall (fig. 2). The mass was removed by laparoscopic partial cystectomy in January 2019 (fig. 3). The operating time was 95 minutes. The patient was discharged 24 hours after the procedure. No recurrence was observed within the follow-up of 3 years.

Figure 2. Case 2. CT scan of the bladder mass of the anterior wall of the bladder.

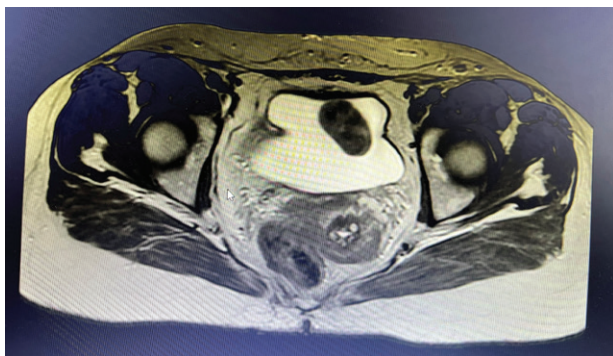
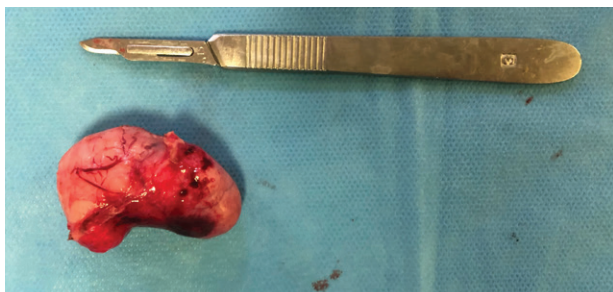


Figure 3. Case 2. Specimen of the Bladder leiomyoma after partial cystectomy.



Case report 3

A 39-year-old patient with seminoma pT1N0 was found to have an asymptomatic urinary bladder mass. The mass was detected on control CT scan which showed a 30 × 18 × 18 mm lesion in the urinary bladder (fig. 4). Cystoscopy revealed a submucosal mass, 4 cm in diameter, which was located on the anterior wall of the bladder (fig. 5). The patient was asymptomatic. He was qualified for elective EBRT. In February 2021, en bloc transurethral resection was conducted. Due to the large size of the tumor and the inability to remove the whole mass intact, defragmentation was performed (fig. 6). The operating time was 30 minutes. The patient was discharged 5 hours after the surgery. No post-operative recurrence of the disease was detected in the patient.

Figure 4. Case 3. CT scan of the bladder mass of the anterior wall of the bladder.

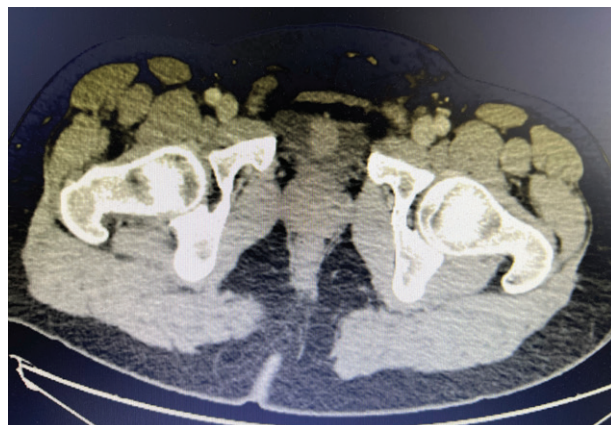


Figure 5. Case 3. Cystoscopic view of the leiomyoma of the anterior wall of the bladder.

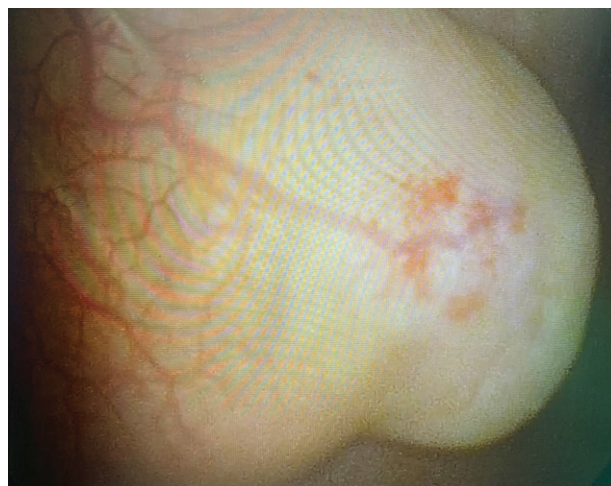
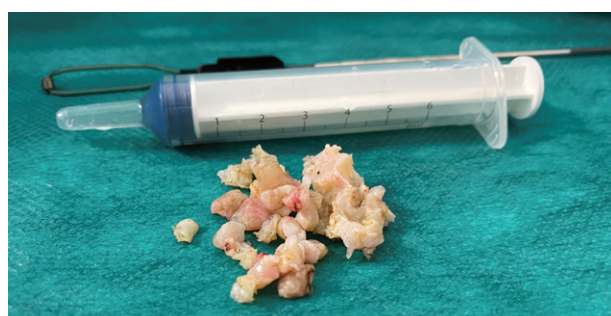
Figure 6. Case 3. Specimen of the bladder mass of the anterior wall of the bladder.



DISCUSSION

Leiomyoma of the bladder is still a rare entity, although it is the most common type of all benign mesenchymal neoplasms found in this organ [2, 4, 7]. Only a low number of cases were reported and, to date, it has been estimated at approximately 300 cases

worldwide [1]. Leiomyomas are usually located in the uterus, but they can also be found throughout the whole urinary tract, with the most common location being the renal capsule [3, 13, 14].

Age and gender had been considered irrelevant in the incidence of leiomyoma in patients [2] until 1994, when Goluboff et al. [4] presented a case of a woman with leiomyoma and analyzed 37 available cases reported at that time. They concluded that there was a strong middle-aged female preponderance. In our study, two out of three patients were women (67%) and their mean age was 54.5 years, which is consistent with the reports of other researchers [3, 4, 15].

Leiomyomas may cause obstructive voiding symptoms (49%), irritative symptoms (38%) or be completely asymptomatic (19%) [4]. It depends on the location in the bladder and size of the tumor. Masses located near natural bladder orifices may cause obstructive symptoms, such as incomplete bladder emptying and increased urinary frequency when they are placed close to the bladder neck, or hydronephrosis when their location is adjacent to one of the ureteric orifices [3, 7, 16]. Urinary tract infections are the most common observations among irritative symptoms [9]. Hematuria is another symptom associated with leiomyomas, also mentioned by other authors. However, it is seen in patients much less frequently, i.e., approximately in 11% [4, 17–19]. Dyspareunia is a symptom which was the least commonly mentioned in the literature. It was reported in only a few cases [20, 21]. According to Park et al. asymptomatic patients had tumor diameters of 3 cm or less, while patients with larger tumors presented with symptoms [3]. Leiomyomas may range in size from less than 1 cm to 30 cm [14]. Our patients were asymptomatic, which was closely related to the size of their lesions, as the largest of them was 54 mm in diameter and, in addition, was located in a favorable place away from the anatomical openings of the urinary bladder.

Leiomyomas may be divided by their distribution in the bladder wall into three types: endovesical (63%), intramural (7%) and extravescical (30%) ones. Endovesical tumors most often cause obstructive symptoms, as they protrude into the lumen of the bladder which may result in closing its natural openings [1, 3, 4]. Diagnostic imaging tests are essential for the detection of leiomyoma. Ultrasonography is a very sensitive tool and, in most cases, it is the first stage of diagnostics in patients. The ultrasound image of leiomyoma is very distinctive, showing a homogenous submucosal solid mass with peripheral hyperechogenicity [15, 22]. Cystoscopy is a basic procedure performed in urologic pa-

tients and it also shows very characteristic features of leiomyoma [8]. Computed tomography and magnetic resonance imaging are used in extended diagnostics to determine the precise location of the tumor in the bladder. MRI may also help to differentiate mesenchymal tumors from transitional cell carcinomas, which account for 95% of bladder cancers [23, 24]. The definitive diagnosis may only be confirmed by histopathological examination of the excised lesion [19]. In our study, all patients had their tumors found during routine diagnostic examinations, which were associated with their previous medical history in two cases. The incidental findings were made during ultrasound examination in two patients and during a control CT scan in one patient.

The surgical management of leiomyoma depends on the size and location of tumor. Smaller endovesical lesions may be removed by means of EBRT, while larger and intramural or extravescical tumors require open surgery or laparoscopy [25]. We performed EBRT in two cases. Only one patient underwent laparoscopic partial cystectomy, due to the larger size of the tumor (5 cm in diameter).

Follow-up visits are an essential element of post-operative patient care. Reoperation rates are relatively low in leiomyomas, which indicates an overall good prognosis in the treatment of this type of neoplasm. However, in some cases, especially after the EBRT procedure, the residual tumor may be found in the urinary bladder due to the incomplete removal of the entire tumor mass. Goluboff et al. reported that none of the patients operated by open surgery needed reoperation. However, 18% of patients who had undergone the transurethral resection of the bladder tumor had to be reoperated [4]. We performed EBRT in two cases, with complete tumor removal achieved in both of them. All of our patients remain under regular control at the urology clinic and, to date, no tumor recurrence has been detected.

CONCLUSIONS

Leiomyoma is a rare finding in the bladder, but with a very characteristic cystoscopic image. It is a benign neoplasm and a properly performed excision of this lesion gives satisfactory results. In this case leiomyoma was asymptomatic, which might be related to the location and size of the tumor. Masses located close to the bladder neck or significantly larger may contribute to urgency or pain. EBRT is the gold standard of treatment, because of the minimal invasiveness and the best cosmetic effect. However, in cases of larger tumors, it is worth considering laparoscopy or EBRT with defragmentation or morcellation.

Table 1. Demographic data.

Case	Age [years]	Sex	Symptoms	Distribution
1	58	female	asymptomatic	endovesical
2	51	female	asymptomatic	endovesical
3	39	male	asymptomatic	endovesical

Table 2. Treatment outcomes.

Case	Diameter [mm]	Location	Surgery type	Operating time [min]	Complications	Follow-up [months]	Recurrence
1	18 mm	Left ureteric orifice	EBRT	15	None	50	No
2	54 mm	Anterior wall	Laparoscopic partial cystectomy	95	None	40	No
3	41 mm	Anterior wall	EBRT	30	none	15	No

EBRT – en bloc resection of bladder tumor.

References

- Jain S, Dahiya P, Dahiya K et al. Bladder Leiomyoma: A Diagnostic Challenge. *J Gynecol Surg.* 2019; 35(4): 276-8. <http://doi.org/10.1089/gyn.2018.0065>.
- Knoll LD, Segura JW, Scheithauer BW. Leiomyoma of the bladder. *J Urol.* 1986; 136(4): 906-8. [http://doi.org/10.1016/S0022-5347\(17\)45124-X](http://doi.org/10.1016/S0022-5347(17)45124-X).
- Park JW, Jeong BC, Seo S II et al. Leiomyoma of the urinary bladder: A series of nine cases and review of the literature. *Urology.* 2010; 76(6): 1425-9. <http://doi.org/10.1016/j.urology.2010.02.046>.
- Goluboff ET, O'Toole K, Sawczuk IS. Leiomyoma of bladder: Report of case and review of literature. *Urology.* 1994; 43(2): 238-41. [http://doi.org/10.1016/0090-4295\(94\)90053-1](http://doi.org/10.1016/0090-4295(94)90053-1).
- He L, Li S, Zheng C et al. Rare symptomatic bladder leiomyoma: case report and literature review. *J Int Med Res.* 2018; 46(4): 1678-84. <http://doi.org/10.1177/0300060517752732>.
- Singh O, Gupta SS, Hastir A. Laparoscopic enucleation of leiomyoma of the urinary bladder: A case report and review of the literature. *Urol J.* 2011; 8(2): 155-8. <http://doi.org/10.22037/uj.v8i2.1030>.
- Ahmed SA, Al-Shaheen AJ, Khudher ZS. Leiomyoma of the urinary bladder – a case report and review of literature. *Ann Coll Med Mosul.* 2018; 40(2): 74-6. <http://doi.org/10.33899/mmed.2018.160006>.
- Khater N, Sakr G. Bladder leiomyoma: Presentation, evaluation and treatment. *Arab J Urol.* 2013; 11(1): 54-61. <http://doi.org/10.1016/j.aju.2012.11.007>.
- Bai SW, Jung HJ, Jeon MJ et al. Leiomyomas of the female urethra and bladder: A report of five cases and review of the literature. *Int Urogynecol J.* 2007; 18(8): 913-7. <http://doi.org/10.1007/s00192-006-0257-9>.
- Mendes JE, Ferreira AV, Coelho SA et al. Bladder leiomyoma. *Urol Ann.* 2017; 9(3): 275. http://doi.org/10.4103/UA.UA_164_16.
- Rey Valzacchi GM, Pavan LI, Bourguignon GA et al. Transvesical laparoscopy for bladder leiomyoma excision: a novel surgical technique. *Int Urogynecol J.* 2020; 3-4. <http://doi.org/10.1007/s00192-020-04557-1>.
- Cornella JL, Larson TR, Lee RA et al. Leiomyoma of the female urethra and bladder: Report of twenty-three patients and review of the literature. *Am J Obstet Gynecol.* 1997; 176(6): 1278-85. [http://doi.org/10.1016/S0002-9378\(97\)70346-6](http://doi.org/10.1016/S0002-9378(97)70346-6).
- Brunocilla E, Pultrone CV, Schiavina R et al. Renal leiomyoma: Case report and literature review. *Can Urol Assoc J.* 2012; 6(2): 87-90. <http://doi.org/10.5489/cuaj.11159>.
- Goldman HB, McAchran SE, MacLennan GT. Leiomyoma of the Urethra and Bladder. *J Urol.* 2007; 177(5): 1890. <http://doi.org/10.1016/j.juro.2007.02.017>.
- Li A, Zhang P, Zhang M et al. Transurethral enucleation of bladder leiomyoma: A series of six cases and review of the literature. *Urol Int.* 2019; 102(1): 69-76. <http://doi.org/10.1159/000493150>.
- Yin FF, Wang N, Wang YL et al. Transvaginal Resection of a Bladder Leiomyoma Misdiagnosed with a Vaginal Mass: A Case Report and Literature Review. *Case Rep Obstet Gynecol.* 2015; 2015: 1-4. <http://doi.org/10.1155/2015/981843>.
- Moawad M, Ben Ghazir N, Rustum Q et al. Rare case presentation of leiomyoma of bladder neck with tuberculous pelvic lymphadenitis in a young female patient. *Urol Case Reports.* 2021; 34: 101436. <http://doi.org/10.1016/j.eur.2020.101436>.
- Silva-Ramos M, Massó P, Versos R et al. Bladder leiomyoma. A pooled analysis of 90 cases. *Actas Urol Esp.* 2003; 27(8): 581-6. [http://doi.org/10.1016/s0210-4806\(03\)72979-9](http://doi.org/10.1016/s0210-4806(03)72979-9).
- Pramod SV, Safriadi F, Hernowo BS et al. A large bladder leiomyoma. *Urol Case Rep.* 2020; 32: 101211. <http://doi.org/10.1016/j.eur.2020.101211>.
- Xin J, Lai HP, Lin SK et al. Bladder leiomyoma presenting as dyspareunia: Case report and literature review. *Med (United States).* 2016; 95(28): 26-9. <http://doi.org/10.1097/MD.0000000000003971>.
- Kim IY, Sadeghi F, Slawin KM. Dyspareunia: an unusual presentation of leiomyoma of the bladder. *Rev Urol.* 2001; 3(3): 152-4.
- Illescas FF, Baker ME, Weinerth JL. Bladder leiomyoma: Advantages of sonography over computed tomography. *Urol Radiol.* 1986; 8(1): 216-8. <http://doi.org/10.1007/BF02924110>.
- Sundaram CP, Rawal A, Saltzman B. Characteristics of bladder leiomyoma as noted on magnetic resonance imaging. *Urology.* 1998; 52(6): 1142-3. [http://doi.org/10.1016/S0090-4295\(98\)00333-1](http://doi.org/10.1016/S0090-4295(98)00333-1).

24. Andreassen BK, Aagnes B, Gislefoss R et al. Incidence and Survival of urothelial carcinoma of the urinary bladder in Norway 1981-2014. *BMC Cancer*. 2016; 16(1). <http://doi.org/10.1186/s12885-016-2832-x>.
25. Kabalin JN, Freiha FS, Niebel JD. Leiomyoma of bladder report of 2 cases and demonstration of ultrasonic appearance. *Urology*. 1990; 35(3): 210-2. [http://doi.org/10.1016/0090-4295\(90\)80032-l](http://doi.org/10.1016/0090-4295(90)80032-l).

Authors' contributions:

Maciej Przudzik: 35%; Maria Derkaczew: 35%; Mirosław Łesiów: 15%;
Marek Roslan: 15%.

Conflict of interests:

The authors declare no conflict of interest.

Financial support:

None.

Ethics:

The authors had full access to the data and take full responsibility for its integrity.

All authors have read and agreed with the content of the manuscript as written.

The paper complies with the Helsinki Declaration, EU Directives and harmonized requirements for biomedical journals.