

Case report

Vertical rectus abdominis myocutaneous flap inguinal reconstruction combined with lymphatic venous anastomosis after oncological resection – a case report and literature review

Julia Radziszewska¹, Natalia Krześniak², Marcin Radziszewski¹, Piotr Gierej²

¹ Faculty of Medicine, Medical University of Warsaw

² Department of Plastic Surgery, Centre of Postgraduate Medical Education, Prof. W. Orłowski Memorial Hospital

ABSTRACT

Introduction: The vertical rectus abdominis myocutaneous (VRAM) flap is one of the possible solutions to cover large tissue defects after oncological resection in the inguinal region. Its efficacy can be impaired due to recipient site tissue damage following radiotherapy as well as due to lymphadenectomy, often resulting in lymphoedema and persistent lymphatic leakage.

Case report: Contralateral VRAM reconstruction was performed in a 50-year-old male patient with a nonhealing inguinal wound following right thigh sarcoma excision and radiotherapy. To improve the flap performance, we combined VRAM surgery with lymphatic venous anastomosis (LVA) to the contralateral inferior epigastric vein. An immediate stoppage of the lymphatic leakage occurred as well as after the surgery a lower extremity edema reduction was observed (varying from 2 to 7 cm of leg circumference, depending on the level of the measurement).

Discussion: It is possible that LVA enabled proper flap healing and improved lymphatic drainage; however, it is also probable that a similar effect could have been achieved with the VRAM flap alone.

Conclusion: This case report indicates that LVA could improve VRAM flap performance in inguinal reconstruction procedures and reduce lymphedema and lymphorrhea; however, further research is needed.

Key words: sarcoma, inguinal reconstruction, vertical rectus abdominis myocutaneous flap, lymphatic venous anastomosis

Correspondence:

Marcin Radziszewski
Faculty of Medicine, Medical
University of Warsaw
02-091 Warszawa,
ul. Żwirki i Wigury 61
e-mail:
marcinradziszewski00@gmail.com

Received:

1.12.2023

Accepted:

29.12.2023

DOI: 10.24292/01.OR.134311223

Copyright © Medical Education.

All rights reserved.

INTRODUCTION

Large tissue defects in the inguinal region resulting from oncological resection are challenging to treat because not only does the size of the lesion require a flap that is significant in size, but other components of oncological treatment also impede the function of the surrounding tissues and vessels. Damage caused by radiotherapy makes wound-surrounding tissue fragile, rendering local anastomoses very difficult to perform or even preventing ipsilateral flap transposition [1]. Regional lymphadenectomy, often needed to achieve higher oncological completeness, can lead to lymphedema and lymphatic leakage within the wound, jeopardizing the healing capabilities of the flap [2]. Furthermore, these complications can also occur following tumor excision in the proximal medial thigh, where the lymphatic network is very elaborate.

After oncological inguinal resections, if primary closure is not achievable, myocutaneous flaps are favored for tissue defect reconstruction [3]. One of the possibilities for large defect coverage in this region is a vertical rectus abdominis myocutaneous (VRAM) flap [4]. Its major advantages are broad skin paddle and robust blood supply, which are especially important when impaired recipient site vessel function is encountered. Nevertheless, morbidity rates following VRAM reconstruction remain considerably high [5].

To improve the likelihood of flap survival and its better healing effect, lymphatic venous anastomosis (LVA) can be performed. It consists of a supermicrosurgical anastomosis between a lymphatic vessel and a nearby vein, connecting the lymphatic flow and systemic circulation within the affected tissues [6]. In this case report, we combined VRAM inguinal reconstruction with LVA for nonhealing wound treatment.

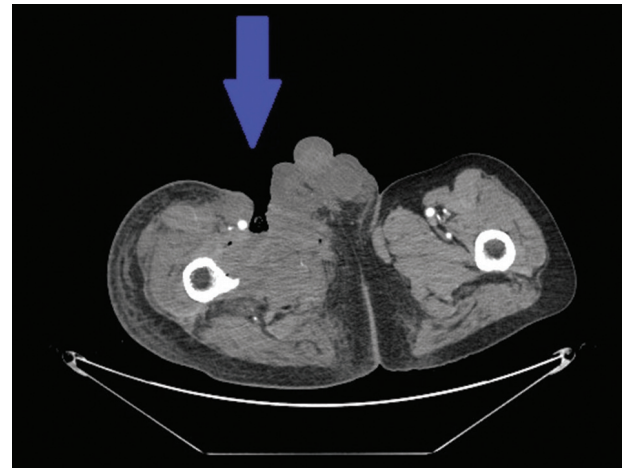
CASE REPORT

A 50-year-old male patient was admitted to the Plastic Surgery Department due to a vast nonhealing wound on the anteromedial surface of the right thigh accompanied by lymphedema and lymphorrhea following sarcoma (G3) excision, chemotherapy, and radiotherapy. During the primary operation, the longitudinal part of the right superficial femoral vein was excised, leading to venous thrombosis above the knee level. Moreover, prior to admission, a filter was inserted endovascularly into the inferior *vena cava* to prevent pulmonary embolism.

The wound initiated at the level of the inguinal ligament and covered an area of 12 × 15 cm below, with a profound recess en-

tering the pelvis minor along the inguinal vessels (fig. 1). Within the wound, lymph collection as well as pulsation of the femoral artery was visible. Due to the size of the defect and coexisting complications, we decided to perform VRAM flap reconstruction combined with LVA. Indocyanine green lymphography was performed to identify and mark the lymphatic pathways.

Figure 1. Computed tomography showing the profundity of the defect. Within the wound, pulsation of the femoral artery was observed.



During the two-team-approach surgery, under general anesthesia, simultaneous flap harvesting and donor site preparation were conducted. The contralateral VRAM flap supplied by the left inferior epigastric artery was rotated to cover the defect, with the muscular part of the flap filling the recess above the femoral vessels. We modified the VRAM technique by adding a triangular part to cover the defect along the inguinal ligament, and during the harvesting procedure, we spared the lateral sides of the rectus abdominis muscle (fig. 2).

Following methylene blue vessel targeting, a lymphatic trunk in the lateral part of the wound was anastomosed with a branch of the left inferior epigastric vein (from the rotated flap) using a venous bypass (derived from the superficial epigastric vein) (fig. 3). An immediate stoppage of the lymphatic leakage within the defect was observed. The wound was closed with a delayed primary suture.

On the second day after the surgery, a reduction in lower extremity lymphedema was noticed. During the next months, the decrease reached from 2 to 7 cm of leg circumference depending on the level of measurement (fig. 4). No further development of lymphedema was observed during a 2-year follow-up period, and there were no signs of oncological disease relapse.

Figure 2. Preoperative (A) and postoperative (B) view of the wound in the right inguinal region. We modified the VRAM technique by adding a triangular part to the flap to cover the defect along the inguinal ligament, and we spared the lateral parts of the rectus abdominis muscle during harvesting.

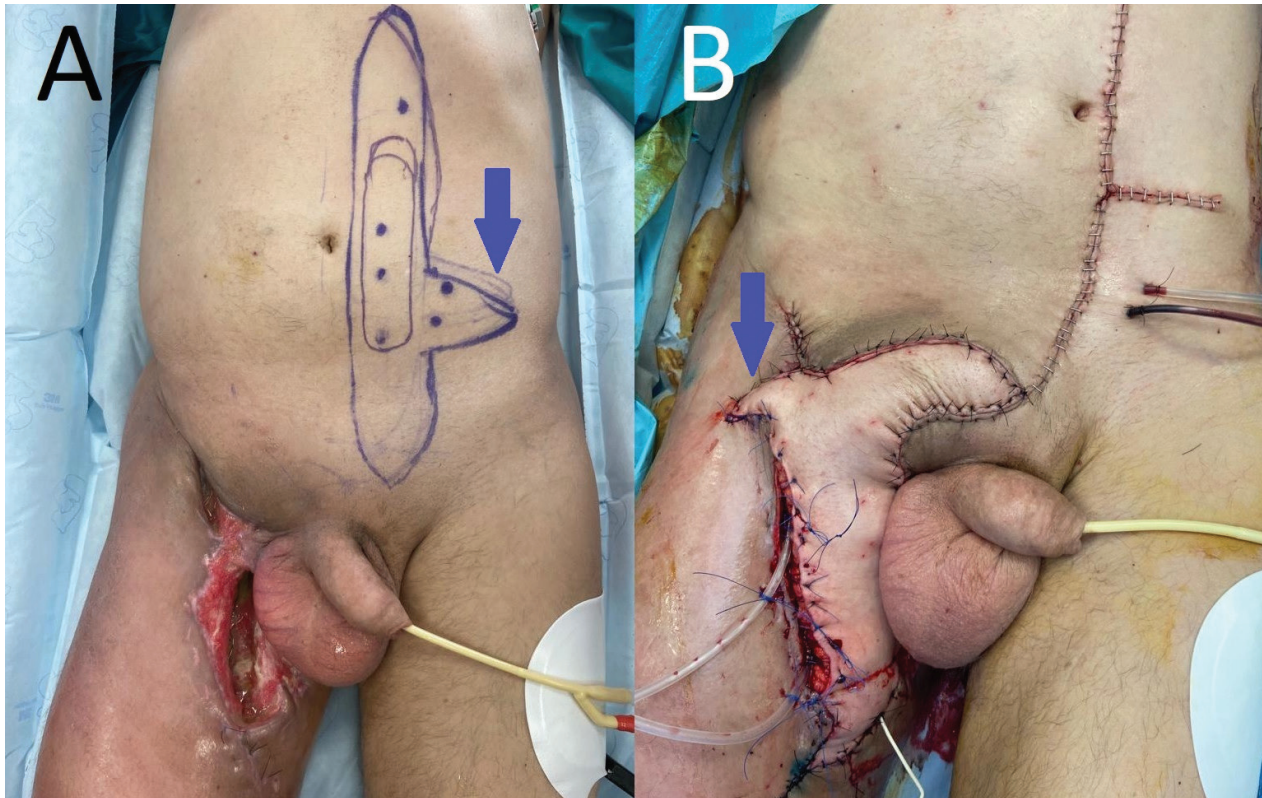
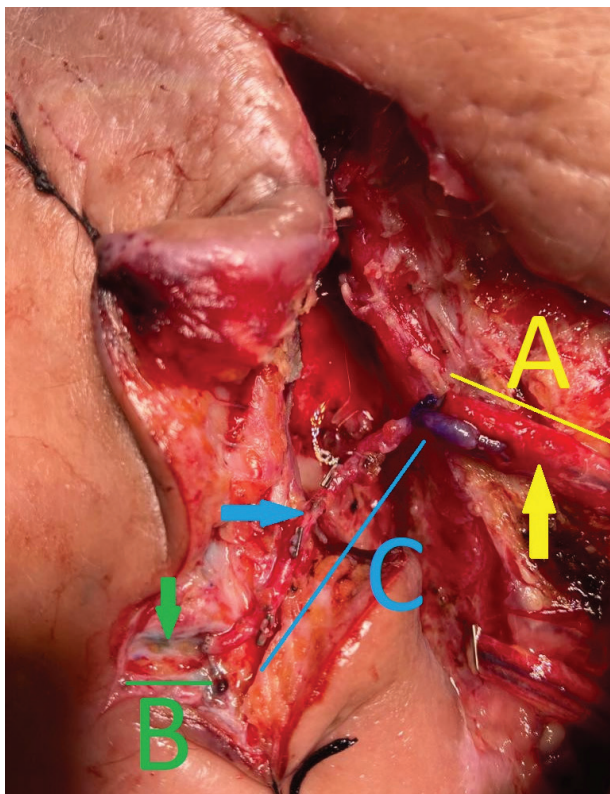


Figure 3. Lymphatic venous anastomosis between the lymphatic trunk (B) and a branch of the left inferior epigastric vein (A) using venous bypass (C) derived from the superficial epigastric vein.



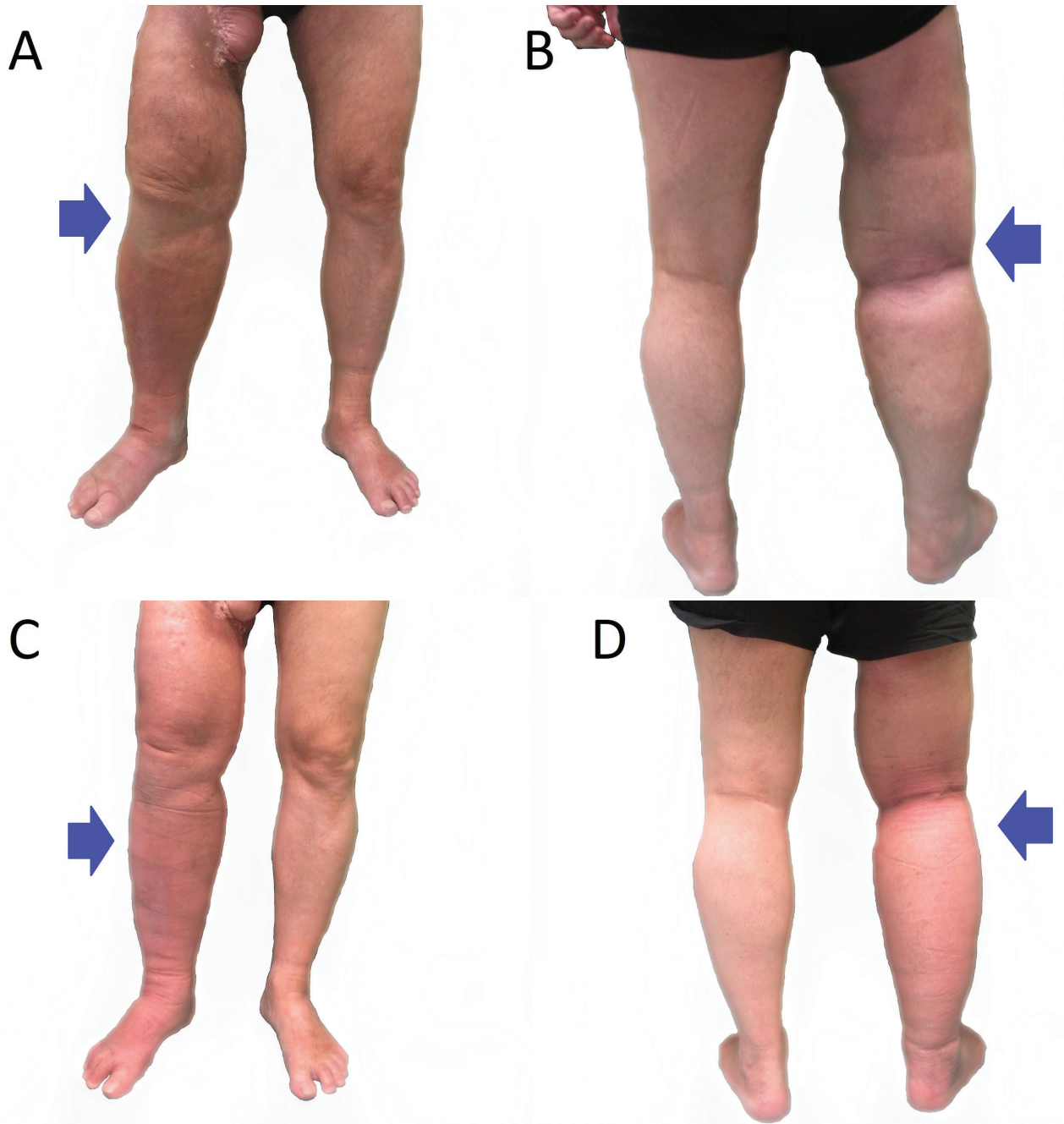
DISCUSSION

Treatment of soft tissue sarcoma (STS), which mainly affects the extremities (60%), relies on radical surgical excision of the tumor combined with radiotherapy and often results in a large tissue defect. Furthermore, resection of a lesion located in the proximal medial thigh or near the inguinal fossa can impede lymphatic drainage in the extremity since the lymphatic network in this location is robust [6]. Although lymph node metastases are not common in patients with STS, their occurrence in a sentinel node biopsy requires a lymphadenectomy, which renders further lymphatic flow disruption [7].

Impaired lymph drainage can cause lymphedema of the extremity, which not only decreases the quality of life of the patient but can also prevent the proper wound healing process. Moreover, lymphatic leakage into the wound renders regeneration even less likely, resulting in a nonhealing wound occurrence. Coverage of such defects is difficult because the aforementioned conditions decrease the flap efficacy as well as its survival rate. Furthermore, radiotherapy following lesion resection renders the procedure even more complicated [8].

Recent studies have revealed that lymphatic venous anastomoses (LVAs) are efficient in the treatment of lymphedema as well

Figure 4. Right lower extremity lymphedema decreases 3 months (A and B) and 6 months (C and D) after surgery. During a 2-year follow-up period, no further development of edema was observed.



as recurrent lymphocele and severe lymphorrhea. A systematic review performed by Scaglioni et al. showed that objective reduction in circumference measurement following LVA was achieved in 100% of articles included (n = 18), and subjective symptom relief was found in 50–100% of the patients (n = 939) [9]. Giacalone et al. achieved complete lymphocele and lymphorrhea subsidence by performing from 1 to 4 LVA in 13 patients (100%) within the follow-up period varying from 6 to 44 months [10].

There are already attempts to combine LVA with flap-derived reconstruction of a large inguinal defect following STS excision; however, they are mainly performed as a precaution of lymphedema or lymphorrhea prior to the occurrence of complications. Nonetheless, their outcome is very promising. In a group of 7 patients after proximal medial thigh sarcoma excision treated with a superficial circumflex artery perforator (SCIP) flap combined with LVA, no lymphatic complications occurred during the mean 7.3-month follow-up period [6].

In this case report, we describe the application of LVA combined with VRAM flap reconstruction in a patient already suffering from major complications, including nonhealing wounds, lymphorrhea, and lymphedema of the lower extremity. We observed a leg circumference reduction and lymphorrhea stoppage, and the flap healed without further complications. It is probable that these outcomes were achievable due to LVA, which reduced lymphedema by improving lymphatic drainage as well as by lymphorrhea stoppage, which prevented lymphocele development and rendered flap healing and angiogenesis possible. The immediate termination of the lymphatic leakage that followed the LVA strongly supports this idea.

On the other hand, we cannot exclude the possibility of a similar outcome in a VRAM reconstruction without the additional LVA. In this scenario, the lymphedema decrease would be secondary to the presence of the VRAM flap, acting as a vascularized lymph node transplant (VLNT) without the lymph nodes, since recent research shows that the active therapeutic component of the

LVNT are lymphatic vessels, not the lymph nodes [11]. It has also been observed that in some cases, tissue transfers without the lymphatic component can improve the lymphatic circulation [12]. Therefore, further research is needed to assess the efficacy of LVA in inguinal reconstruction.

CONCLUSION

LVA may significantly improve the performance of a myocutaneous flap in inguinal reconstruction and reduce lymphedema and lymphorrhea. VRAM flap combined with LVA can be applied to cover large tissue defects in the inguinal region with coexisting lymphatic leakage and lower extremity edema; however, further research on the role of LVA is needed.

ORCID

Marcin Radziszewski – ID – <http://orcid.org/0000-0002-9664-3099>

References

1. Gürlek A, Miller MJ, Amin AA et al. Reconstruction of complex radiation-induced injuries using free-tissue transfer. *J Reconstr Microsurg.* 1998; 14(5): 337-40. <http://doi.org/10.1055/s-2007-1000187>.
2. Jeanne-Julien A, Bouchot O, De Vergie S et al. Morbidity and risk factors for complications of inguinal lymph node dissection in penile cancer. *World J Urol.* 2023; 41(1): 109-18. <http://doi.org/10.1007/s00345-022-04169-y>.
3. Söreljus K, Schiraldi L, Giordano S et al. Reconstructive Surgery of Inguinal Defects: A Systematic Literature Review of Surgical Etiology and Reconstructive Technique. *In Vivo.* 2019; 33(1): 1-9. <http://doi.org/10.21873/invivo.11431>.
4. Sánchez-García A, García Moreno MÁ, Salmerón-González E et al. Inguinal Reconstruction Using Pedicled Rectus Abdominis Flap: A Useful Option for the Application of Radiotherapy. *Plast Surg Nurs.* 2019; 39(2): 41-3. <http://doi.org/10.1097/PSN.0000000000000256>
5. Radwan RW, Tang AM, Harries RL et al. Vertical rectus abdominis flap (VRAM) for perineal reconstruction following pelvic surgery: A systematic review. *J Plast Reconstr Aesthet Surg.* 2021; 74(3): 523-9. <http://doi.org/10.1016/j.bjps.2020.10.100>.
6. Scaglioni MF, Meroni M, Fritsche E et al. Combined pedicled superficial circumflex iliac artery perforator (SCIP) flap with lymphatic tissue preservation and lymphovenous anastomosis (LVA) for defect reconstruction and lymphedema-lymphocele prevention in thigh sarcoma surgery: Preliminary results. *J Surg Oncol.* 2021; 123(1): 96-103. <http://doi.org/10.1002/jso.26228>.
7. Witt RG, Cope B, Erstad DJ et al. Sentinel Lymph Node Biopsy and Formal Lymphadenectomy for Soft Tissue Sarcoma: A Single Center Experience of 86 Consecutive Cases. *Ann Surg Oncol.* 2022; 29(11): 7092-100. <http://doi.org/10.1245/s10434-022-11803-x>.
8. Tasch C, Pattiss A, Maier S et al. Free Flap Outcome in Irradiated Recipient Sites: A Systematic Review and Meta-analysis. *Plast Reconstr Surg Glob Open.* 2022; 10(3): e4216. <http://doi.org/10.1097/GOX.0000000000004216>.
9. Scaglioni MF, Fontein DBY, Arvanitakis M et al. Systematic review of lymphovenous anastomosis (LVA) for the treatment of lymphedema. *Microsurgery.* 2017; 37(8): 947-53. <http://doi.org/10.1002/micr.30246>.
10. Giacalone G, Yamamoto T, Hayashi A et al. Lymphatic supermicrosurgery for the treatment of recurrent lymphocele and severe lymphorrhea. *Microsurgery.* 2019; 39(4): 326-31. <http://doi.org/10.1002/micr.30435>.
11. Miranda Garcés M, Pons G, Mirapeix R et al. Intratissue lymphovenous communications in the mechanism of action of vascularized lymph node transfer. *J Surg Oncol.* 2017; 115(1): 27-31. <http://doi.org/10.1002/jso.24413>.
12. Slavin SA, Upton J, Kaplan WD et al. An investigation of lymphatic function following free-tissue transfer. *Plast Reconstr Surg.* 1997; 99(3): 730-43. <http://doi.org/10.1097/00006534-199703000-00020>.

Authors' contributions:

J.R. conceived the idea and wrote the manuscript. N.K. and M.R. collected and analysed the data. P.G. provided critical feedback and shaped the manuscript.

Conflict of interests:

Authors declare to have no conflict of interest.

Financial support:

This research has not been funded by a third party.

Ethics:

The authors had full access to the data and take full responsibility for its integrity. All authors have read and agreed with the content of the manuscript as written. The paper complies with the Helsinki Declaration, EU Directives and harmonized requirements for biomedical journals.