

# Remote consequences of polychemical and radiation therapy: cardiac valve disease complicated by infective endocarditis. Diagnostic and management problems

*Prof. Marina F. Ballyuzek, MD PhD<sup>1,2,3,4</sup>, Anna K. Ionova, MD<sup>1</sup>,  
Maria V. Mashkova, MD<sup>1</sup>, Irina G. Semenova, MD PhD<sup>1</sup>,  
Irina V. Sukhova, MD PhD<sup>5</sup>*

<sup>1</sup> St. Petersburg Hospital of Russian Academy of Sciences

<sup>2</sup> Medical Director of St. Petersburg Hospital of Russian Academy of Sciences

<sup>3</sup> Chief of Cardiology Department of Russian Academy of Sciences

<sup>4</sup> Professor at the Therapy Department of St. Petersburg State University

<sup>5</sup> Federal Almazov Heart, Lung and Endocrinology Center



## ABSTRACT

One of the quite frequent long-term effects of radiation therapy of malignant tumors, such as breast cancer and Hodgkin's lymphoma primarily, when the irradiation of the mediastinum is performed, is the development of radiation-induced valvular disease. It is noted that the clinical manifestation of valve dysfunction can typically arise approximately 5 years after a course of anticancer radiotherapy. Thereafter in these patients increases the risk of infective endocarditis. However, in therapeutic and oncological clinical practice the difficulty of identifying and making the differential diagnosis of endocarditis in patients with "cancer" history is still quite common. At the moment cases of infective endocarditis after polychemotherapy and radiation therapy are not widely covered for cardiologists and internists in the medical literature. In addition before starting specific treatment due to the possible threat of infectious complications, including endocarditis, in oncology guidelines it is recommended to patients to make a thorough oral cavity sanitation, while the internists are little aware of this need, both at the stage of antitumor therapy and at late period. Today, with the increasing number of patients who are healed or achieved long-term remission after the anticancer treatment, including elderly people, it is necessary to raise the awareness among internists about occurrence options of comorbid disease in these group.

**KEY WORDS:** radiation-induced heart disease, radiation-induced valvular disease, infective endocarditis, prevention of endocarditis after anticancer therapy

It has already been proved that one of the common remote consequences of malignant tumor radiation therapy, particularly that of mammary gland cancer and Hodgkin's lymphoma, which require mediastinum irradiation, is development of Radiation-Induced Heart Disease (RIHD) [1]. Radiation-induced inflammatory reaction of various cardiac tissues can lead to the development of endocardiac, miocardiac and pericardiac fibrosis, as well as cause radiation-induced valvular disease (RIVD) and radiation-induced coronary disease (RICD) [2]. Concerning RIVD, it has been shown that the pathomorphological changes in cardiac valves, most often the aortic and mitral ones, cause the valve leaflets to become fibrotic, with focal dystrophic calcification and marked thickening [3]. The more common left heart valve involvement is explained by the technique used for irradiating the mediastinum, whereby these elements get the maximum radiation load [4, 5].

It has been noted that clinical presentations of valvular dysfunction usually become apparent 5 years after the radiation treatment; however, after treating lymphoma in children, when clinically relevant degenerative valvular changes and early symptoms of serious coronary disease become evident only 20 to 30 years later, these are also interpreted as RIHD [5].

Due to these facts antibiotic prophylaxis were included in dental standards for infective endocarditis and bacteremia in patients receiving anticancer treatment [6].

However, there are still many problems with diagnosing endocarditis in patients, who have had "cancer" in their past medical history. According to our classification [7] of medical problems arising during the treatment of cancer patients not only by oncologists, but also by internists, this problem can be included into the group of pathological states arising as a consequence of tumor treatment. However, the same problem can be classified as a background state having no direct connection with the oncological disease; because of a certain "dependence" of all medicals on the oncological diagnosis, it can be treated as redevelopment of tumor and, consequently, the patient may not get timely and adequate treatment [7].

These problems have received little coverage in medical literature, both oncological and cardiological, so the difficulties in diagnosing and managing patients having oncological medical history can be of great clinical interest. To illustrate, we would like to give the following clinical example.

H.L.V. (63-year-old), was admitted to the cardiology department of RAS Clinical Hospital in St. Petersburg on 03.10.2013. She was complaining of dyspnea at rest, oedema of pelvic limbs, pronounced weakness, tachycardia and a cough with mucoid sputum.

It was revealed that in 2005 the patient had undergone combined treatment including left-side mastectomy, as well as polychemical and radiation therapy for left breast cancer. During the following 5 years she had been dynamically observed by oncologists, but the disease did not recur. In autumn 2012 her state deteriorated: she started experiencing bouts of pain in the chest, progressing dyspnea and blood pressure instability, and was consequently admitted into one of the city hospitals diagnosed with deteriorating hypertension, coronary heart disease, angina pectoris and chronic cardiac decompensation. In hospital, the echocardiogram also revealed hemodynamically relevant sclera-degenerative 2 degree aortic stenosis. After discharge from hospital on 08.02.2013, the patient started experiencing recurrent temperature rise of up to 38°C, as well as bouts of pain in the right-side iliac area. 12 days later, on 20.02.2013, she was taken to another hospital with symptoms of left-side monoparesis, and on 21.02.2013 she was diagnosed with ischemic stroke in basin of right middle cerebral artery. Given her breast-cancer history and fever, the paraneoplastic syndrome and brain metastases were to be excluded. From the examination results including positron emission tomography, no data was obtained to support the disease recurrence. Blood analysis showed pronounced inflammation symptoms, which were interpreted as resulting from exacerbation of chronic pyelonephritis; so the patient was treated with antibiotics. In the treatment process the temperature fell to normal, and the patient's general condition improved. Nevertheless, after discharge, supervision was recommended to exclude breast cancer recurrence, the paraneoplastic syndrome.

According to the decision of 02.04.2013, ambulatory PET/CT of the patient's head and neck, chest, peritoneal cavity and retroperitoneal space showed some symptoms of fluorodeoxyglucose hypermetabolism in chest lymph glands and the right-side transverse process of vertebra Th7, which could be considered secondary to the condition after left-side mastectomy; there were no results obtained suggesting local disease recurrence.

In August 2013 the patient was urgently hospitalized on account of gastrointestinal hemorrhage, which was considered to be the presentation of gastric ulcer.

After discharge, her condition deteriorated sharply in late September 2013, when dyspnea intensified, edema of pelvic limbs and waist area became more pronounced and abdominal volume increased. The patient was consulted by a internist, who thought the condition was caused by exacerbation of the light-form bronchial asthma that the patient was suffering from. The prescribed parenteral hormonal treatment, which was conducted from

20.02.2013 till 03.10.2013, resulted in rapid progress of the symptoms mentioned above. On 03.10.2013, the patient was admitted into St. Petersburg RAS Clinical Hospital.

It was known that since 2006 the patient had also been suffering from diabetes mellitus type 2 and since 2000 from hypertension. Besides, in 2006 she had erysipelatous inflammation on her left arm alongside post-operative lymphostasis.

On preliminary examination her condition proved grave, characterized by diffuse cyanosis, orthopnea, with the temperature of 36.8°C. The patient was 167 cm tall, weighed 87 kg, with body mass index of 32 and 2<sup>nd</sup> degree obesity.

The hypertension was characterized by the blood pressure of 80/60 mmHg, and 104 heartbeats per minute. During auscultation, in all points rough systolic murmur could be heard, with the maximum on the aorta pulse and passing on to the cervical vessels. Short blowing diastolic murmur on the aorta also seemed present, passing on to the aortic arch and cervical vessels. The patient's respiratory rate was 22–24 per minute, breathing was hard, with sharp reduction in the lower departments; over the whole of the lung surface rales could be discerned. Oedema of pelvic limbs was also registered, with shin dimensions S > D.

Given the patient's medical history, the comorbidity, results of examination and the patient's complaints, the suggested diagnosis was pulmonary embolism (PE). The patient's condition was

evaluated according to Geneva Score (11 points) and Wells Scale (8.5 points), which allowed us to include her into the high risk group for PE development [8] and determined the algorithm for further examination.

The results of laboratory tests revealed medium-degree asiderotic anemia (with hemoglobin amounting to 89.2 g/l, iron of 30 mm/hr, while the leftward stab shift reached 20, with erythrocyte sedimentation rate of 30 mm/hr. Other significant results included hypoproteinemia with hypoalbuminemia (with albumin ratio of 33 g/l), increased CA 125 oncomarker amounting to 605.6 (with the normal rate of 0–35); however, D-dimer was not significantly high (514 ng/ml), while troponin I rate corresponded to normal (0.016 ng/ml).

According to the CT results (with no contrastive substance, as when admitted the patient showed increased creatinine rate of up to 210 µmol/l and decreased rate of glomerular filtration of up to 21 ml/min/1.73 m<sup>2</sup> according to MDRD), bilateral hydrothorax (Figure 1) was identified (more pronounced on the right), as well as hypoventilation, partial compressive pulmonary collapse in the inferior lobe of left lung (C 7, 8) and CT-signs of embolism of pulmonary artery branches with infarction pneumonia (Figure 2); besides, they showed fibrous pulmonary changes and local fibrosis in upper left lung. The condition following left-side mastectomy was identified including lymphadenopathy of chest

FIGURE 1.  
Chest CT of patient H.L.V.: bilateral hydrothorax.

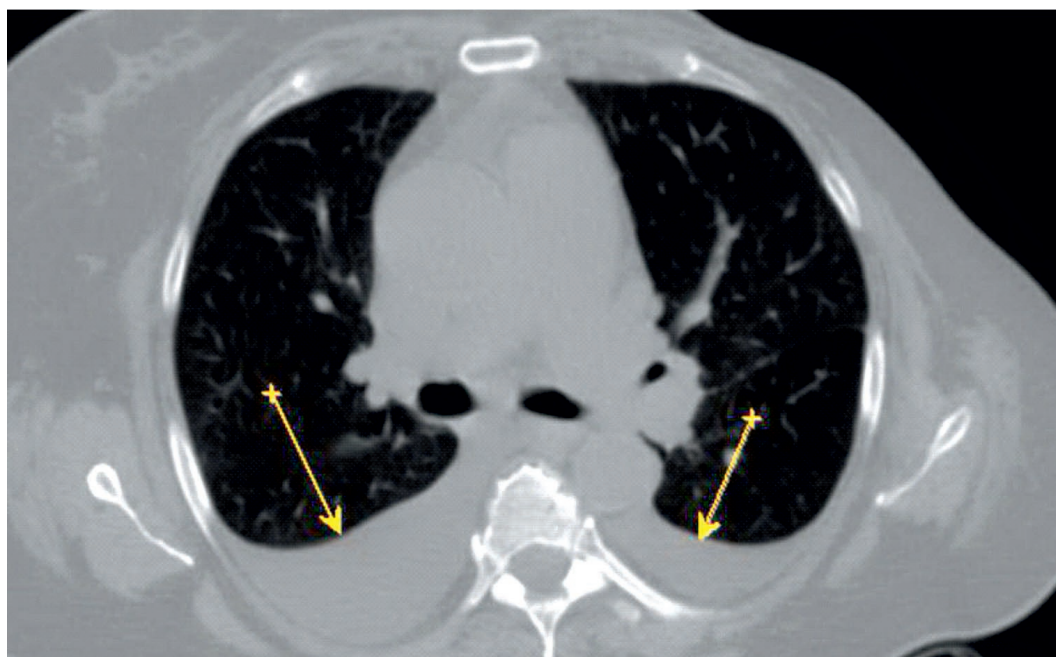
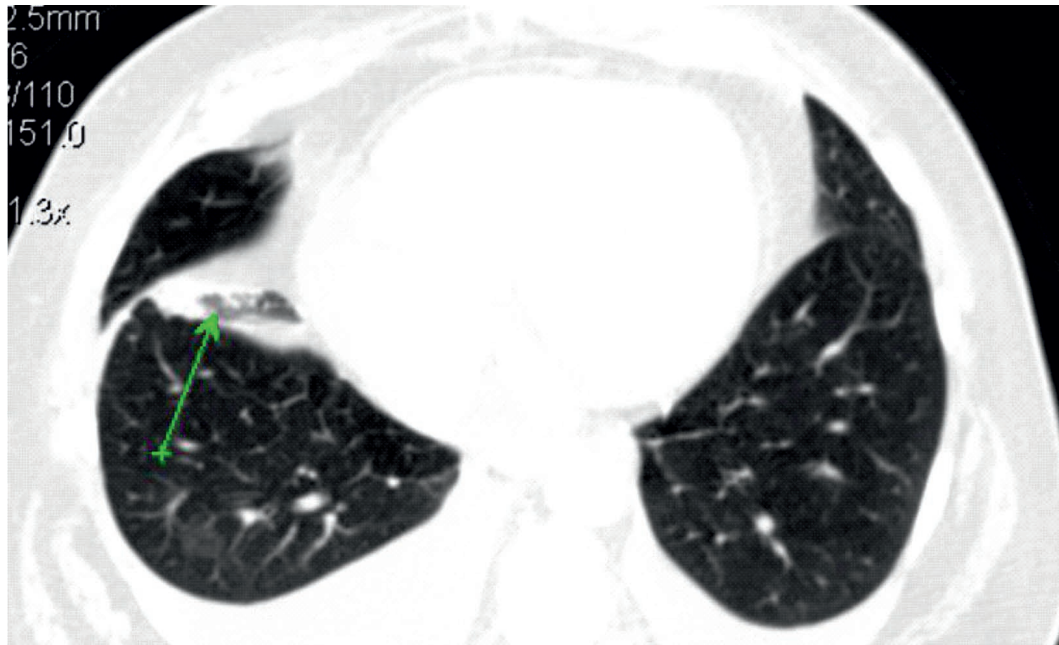


FIGURE 2.

Chest CT of patient H.L.V.: partial compressive pulmonary collapse in the inferior lobe of left lung C7, C8; likely infarction pneumonia.



lymph glands, cardiomegaly and hydropericardium. Dilation of pulmonary artery and its branches was registered, as well as atherosclerosis of aorta and coronary arteries.

Duplex examination of pelvic limb veins did not show any signs of thrombosis.

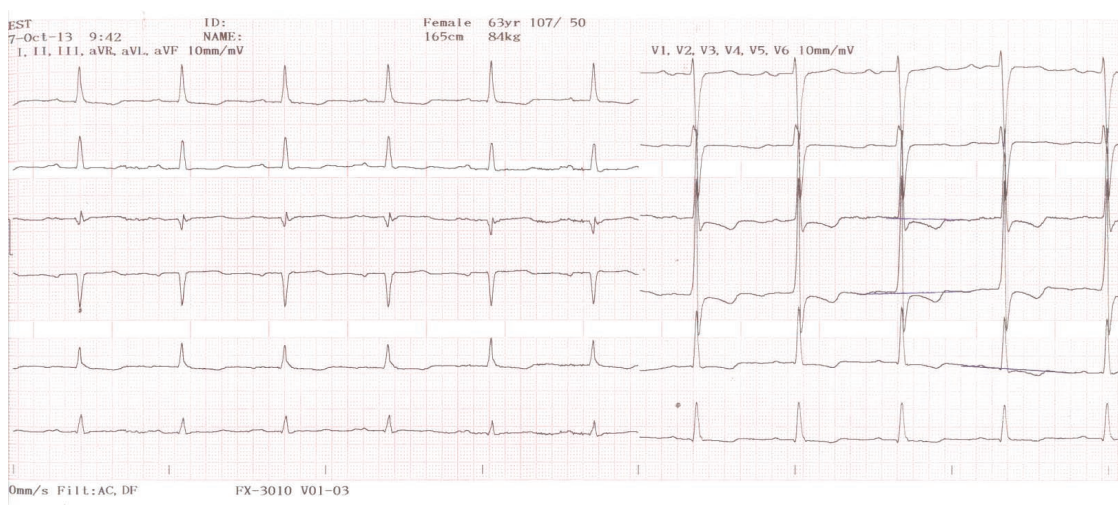
On instrumental examination of the coronary system on ECG, on 04.10.13, coronary deficiency on the anterior lateral left ventricular wall was observed alongside sinus tachycardia (Figure 3).

The results of 12-channel all-day monitoring showed ventricular extrasystoles, grade 5 according to Lown-Ryan.

The results of echocardiography of 07.10.2013, as compared to those of the previous examination of 20.02.2013, showed more intensive changes in cardiac valve tissues: severe aortic stenosis (Figure 4–8), sharp progress in aortic deficiency reaching medium-severe degree, onset of severe mitral insufficiency. Also severe pulmonary hypertension, decreased global contractibility and hypokinesia of left ventricular lateral wall were registered. Based on

FIGURE 3.

H.L.V.'s electrocardiogram when admitted on 03.10.2013.



the examination results, as well as on the patient's medical history and results of laboratory tests it was for the first time suggested that she was suffering from infective endocarditis, although the presence of vegetations was not reliably determined, and test re-

sults for procalcitonin were negative. Triple blood collection with incubation in aerobic and anaerobic environments did not produce any hemoculture. Also a patient didn't remember undergoing any minor invasive procedures, including dentist surgery.

FIGURE 4.

ECHO-CG of patient H.L.V.: view of aortic valve from parasternal position. Opening practically indiscernible.

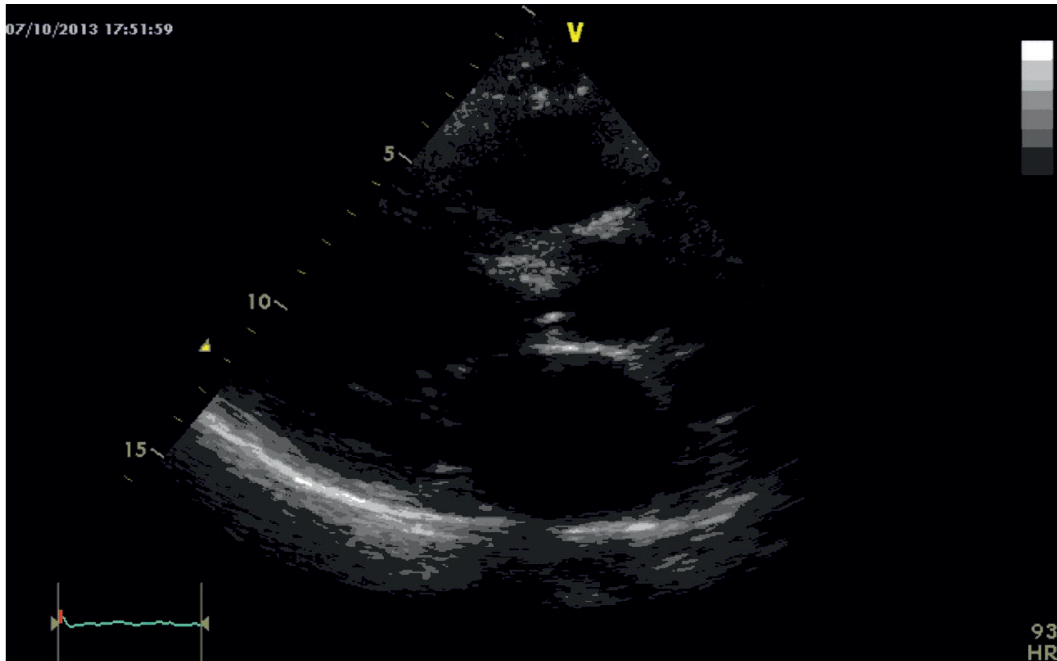


FIGURE 5.

ECHO-CG of patient H.L.V.: opening is practically indiscernible in cross-section at aortic valve level.

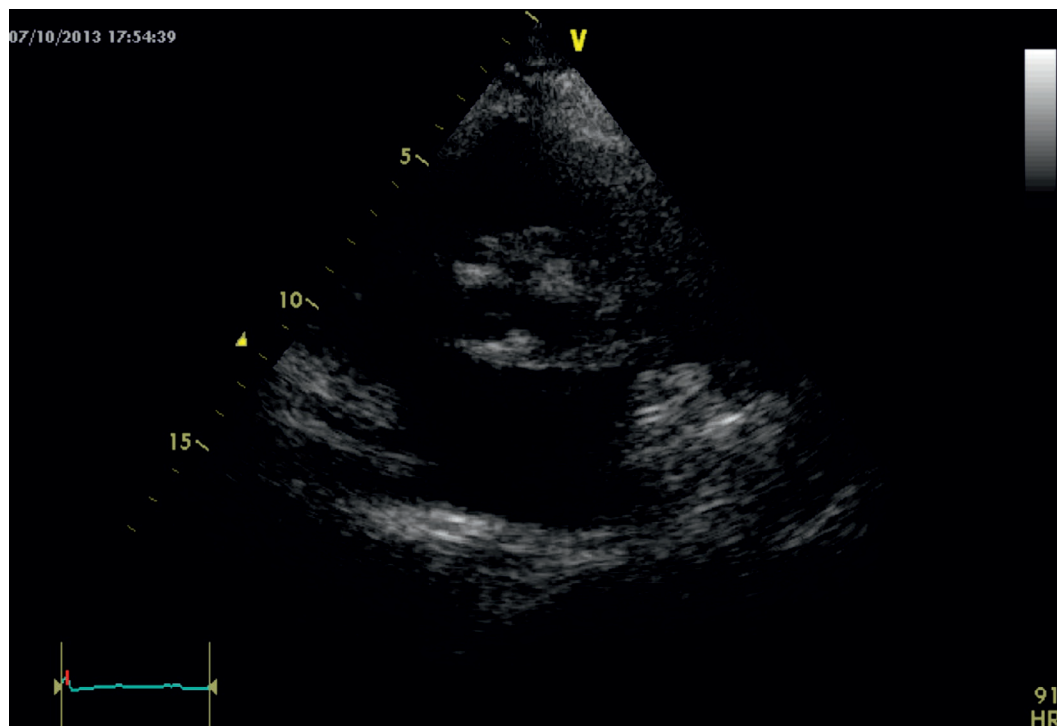


FIGURE 6.  
ECHO-CG of patient H.L.V.: blood flow rate at valve in constant wave mode.

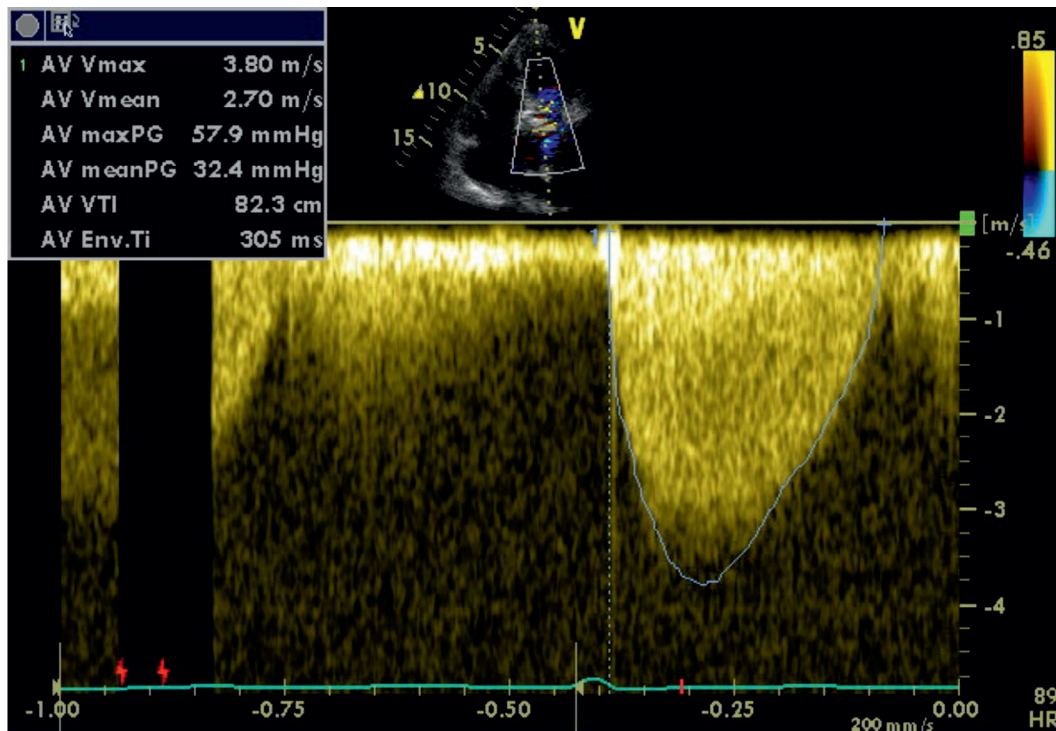


FIGURE 7.  
ECHO-CG of patient H.L.V.: eccentric stream of aortic regurgitation.

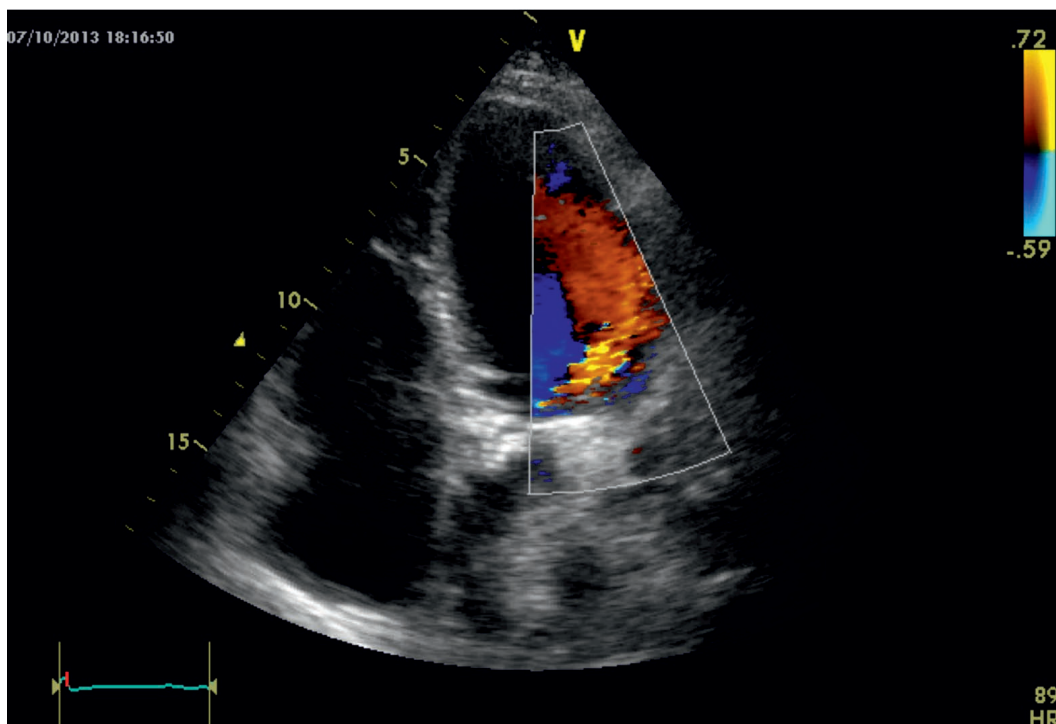
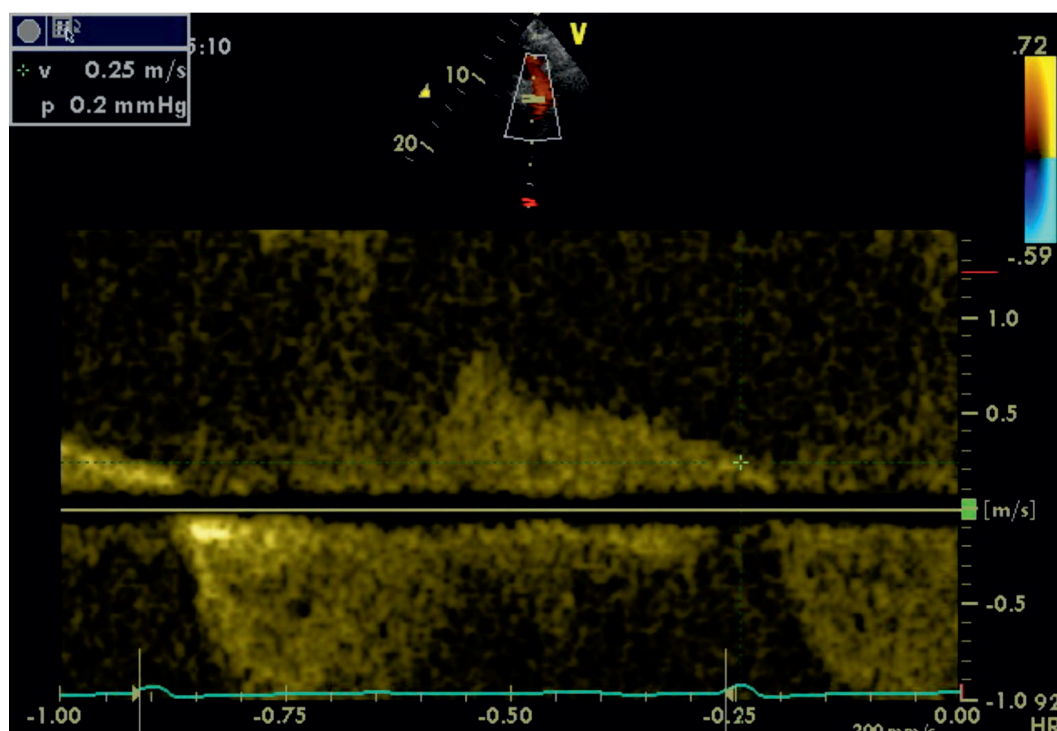


FIGURE 8.

ECHO-CG of patient H.L.V.: Retrograde blood stream in descending aorta with CDS of 0.25 m/s (over 0.18 m/s is considered a sign of severe regurgitation).



The patient was consulted by the cardio surgeon from Federal Almazov Heart, Blood and Endocrinology Centre; indications were identified for surgical correction of aortic valve failure. However, due to the possibility of recurrent cancer disease, there were doubts expressed as to the necessity of surgical treatment of a patient with the supposedly terminal stage of cancer.

In spite of the completed examinations aimed at identifying the presence and stage of the tumor, the diagnostic search was continued. Because of the ongoing ascites and no response to the introduction of diuretic agents, laparocentesis was performed, and no atypical cells were found in the ascetic fluid.

In search of the oncologic process, pelvis MRI, CT of abdomen, fibrogastroscopy and colonoscopy were repeated, which showed no signs of malignant disease.

Also notable was pronounced hypocoagulation during treatment with oral anticoagulants; in order to exclude the oncohematological disease, trepanobiopsy was performed; the mielogramma results were shown to the hematologist, who excluded hematological disease.

At last, the oncologist made the final conclusion about no signs indicating recurrence of the malignant disease.

In spite of the positive dynamics in the patient's condition resulting from cardiac deficiency therapy, recurrent thromboem-

bolism and antibacterial treatment of the supposed infective endocarditis, the question of surgery insistently emerged and on 20.11.2013 the patient was transferred to the cardio surgery department of Almazov Centre.

Immediately on admittance, the patient underwent coronary angiography, whose results did not reveal any significant stenosis of coronary arteries. However, on 24.11.2013 the patient developed an episode of third degree atrioventricular block, accompanied by a hemodynamic collapse, which required resuscitative measures and served as a pretext for urgent surgery. During the surgery, two open abscesses were microscopically revealed on the septal cusps of aortic valve. Aortic valve replacement and annuloplasty of the mitral and tricuspid valve ring according to R. Batista was performed, with cardiopulmonary bypass and blood cardioplegia.

According to the histological examination, alongside atherosclerotic changes and calcinosis, secondary acute infective myocarditis was identified, as well as microorganism colonies.

In the early post-operative period, alongside atrial flutter paroxysm, an episode of third degree atrioventricular block was registered; consequently, on 02.12.2013 VITRATRON DDD electric cardiostimulator was urgently implanted.

Because of the persistent sub-febrile fever, antibacterial therapy was repeatedly altered, which was adjusted to the susceptibility of specific microorganism colonies.

In the process of the treatment, cardiac deficiency dropped significantly, and blood inoculations gave negative results. Post-operative wounds did not show any signs of inflammation. The patient received a course of exercise therapy and physiotherapy. She was discharged in satisfactory condition and prescribed ambulatory monitoring by the cardiologist and oncologist; at present, the patient remains in stably good condition, without any setbacks.

## CONCLUSION

In our opinion, the rapid development and progress of cardiovascular morbidity in this case was caused by the following factors:

- risk factors present prior to the anti-tumor treatment (diabetes mellitus type 2, obesity, dyslipidemia)
- application of combined specific treatment (chemotherapy+radiation therapy), which proved an added risk factor for developing sclera-degenerative diseases of left heart valve
- no dynamic observation by cardiologist for 8 years after antineoplastic treatment, as well as during the current disease, which prevented early detection and correct interpretation of the causes of rapidly progressing cardiovascular morbidity
- “dependence” of doctors, both oncologists and other special-

lists taking part in the patients treatment, on the “cancer” diagnosis

- lack of awareness on the part of “non-oncological” doctors, particularly internists and cardiologists, of the possible consequences of specific treatment of oncological patients.

So far, cases when infective endocarditis develops following chemotherapy and radiation therapy have not been widely discussed in medical literature for cardiologists and internists. Meanwhile, one of the points in instructions for treating oncological patients is careful mouth sanitization and dental check before specific treatment is started due to the possible hazard of infective complications including infective endocarditis [5]. However, given the growing numbers of patients who have been cured or have reached lengthy remission, including old-age and senior people, it is necessary to raise awareness of internists about the possible ways of the progress of co-morbid diseases with such patients.

Therefore, information about the preventive measures against bacteremias and endocarditis should be included into the cardiologic algorithm of managing cancer patients with potential RIHD development in post-radiation period.

In our opinion, the case we have described here proves that modern oncology must operate at the interface between different fields, thereby turning into an interdisciplinary science. Cardiology should obviously become its close partner.

## References

1. Frieland AH, Sung EC, Child JS. Radiation-induced heart disease after Hodgkin's disease and breast cancer treatment: dental implications. *J Am Dent Assoc.* 2003; 134(12): 1615-20.
2. Byrd BF, Mendes LA. Cardiac complications of mediastinal radiotherapy: the other side of the coin. *J Am Coll Cardiol* 2003; 42(4): 750-751.
3. Yusuf SW, Sami S, Daher IN. Radiation-Induced Heart Disease: A Clinical Update. *Cardiology Research and Practice* 2011 [online: <http://dx.doi.org/10.4061/2011/317659>].
4. Brand M.D, Abadi CA, Aurigemma GP. Radiation-associated valvular heart disease in Hodgkin's disease is associated with characteristic thickening and fibrosis of the aortic-mitral curtain. *Journal of Heart Valve Disease* 2001; 10(5): 681-685.
5. Tamura A, Takahara Y, Mogi K, Katsumata M. Radiation-induced valvular disease is the logical consequence of irradiation. *General Thoracic and Cardiovascular Surgery* 2007; 55(2): 53-56.
6. Hong CH, Napeñas JJ, Hodgson BD. A systematic review of dental disease in patients undergoing cancer therapy. *Support Care Cancer* 2010; 18(8): 1007-21.
7. Ballyuzek MF, Stepanov BP. Aims and opportunities of therapeutic rehabilitation of oncology patients. *Clinical Medicine/Klinicheskaja medicina* 2013; 9: 52-56.
8. Wong DD, Ramaseshan G, Mendelson RM. Comparison of the Wells and Revised Geneva Scores for the diagnosis of pulmonary embolism: an Australian experience. *Internal Medicine Journal* 2011; 41(3): 258-263.

### Correspondence:

Prof. Marina F. Ballyuzek, MD PhD

Department of Cardiology, St. Petersburg Hospital of Russian Academy of Sciences  
St. Petersburg, pr. Toreza 72, 194017, Russian Federation