

# Percutaneous vena cava superior angioplasty and stenting as an effective method of treatment in vena cava superior syndrome in the course of lung cancer

*Szymon Darocha, MD<sup>1</sup>, Sebastian Szmit, MD PhD<sup>1</sup>,  
Radosław Pietura, MD PhD<sup>2</sup>, Marcin Kurzyna, MD PhD Ass. Prof.<sup>1</sup>*

*<sup>1</sup> Department of Pulmonary Circulation and Thromboembolic Diseases,  
Centre of Postgraduate Medical Education, European Health Centre Otwock, Poland*

*<sup>2</sup> Department of Radiography, Medical University of Lublin, Poland*



## ABSTRACT

Vena cava superior syndrome (VCSS) is a sudden life-threatening condition encountered in patients with neoplasms. The prognosis depends on histopathological diagnosis, severity of clinical symptoms and administered treatment. Depending on the type of neoplasm, the treatment of choice may be radiotherapy or chemotherapy. In patients with rapidly increasing clinical symptoms the justified management is percutaneous balloon angioplasty of the superior vena cava with the placement of stents.

**KEY WORDS:** vena cava superior syndrome, vena cava superior stenting, lung cancer

## CASE REPORT

A 51-year patient with metastatic lung adenocarcinoma was admitted to the Department of Pulmonary Circulation and Thromboembolic Diseases, in July 2014 as a sudden case of rapidly intensifying symptoms of vena cava superior syndrome in the course of thrombosis. For 10 days before admission she was treated with enoxaparin 60 mg + 40 mg (body weight of the patient: 60 kg). Despite treatment, her clinical condition deteriorated, neck circumference increased, headache and ocular swelling and pain developed. Chest CT did not confirm emboli in pulmonary arteries; however thrombosis of the right internal jugular vein and almost complete obstruction of the superior vena cava for about 20 mm (annular thrombus surrounding the catheter) was demonstrated. At this level vena cava superior was modeled from the outside by two pathologically enlarged lymphatic nodes (from the lateral side by a 21 mm node in the upper pole of the right lung hilus and medially by a 14 mm pretracheal node).

Her oncological history included: I line of chemotherapy with cisplatin and navelbine (February – April 2013), followed by II line of chemotherapy with docetaxel (October – December 2013), in May 2014 neurosurgical treatment of brain metastases, in June 2014 adjuvant radiotherapy of the brain (the dose of 3000 cGy/t in 10 fractions). The patient received glycocortikosteroids for a long time.

In the Department of Pulmonary Circulation and Thromboembolic Diseases treatment with non-fractionated heparin was implemented, initially with a bolus of 5000 units, followed by an infusion of about 1000 units/hour, achieving therapeutic increase of APTT. The clinical condition of the patient improved; there were no complications of thrombolytic treatment. However, despite optimum APTT control during the non-fractionated heparin infusion, the symptoms of superior vena cava syndrome persisted. On 30.07.2014 in the cath lab phlebography was performed from the right basilic and left cephalic vein access. Phlebography showed obstruction of the proximal part of the right brachiocephalic vein and critical narrowing of the proximal part of the left brachiocephalic vein and distal part of the superior vena cava (Figure 1a, 1b). Then, right femoral vein was punctured and a 7F 11 cm port was inserted, followed by a 6F catheter, which, together with a hydrophilic guidewire, was passed through the narrowed superior vena cava and left brachiocephalic vein. Using a 12 × 40 mm balloon pre-dilatation of the stricture was performed (Figure 2a, 2b). Then, chemotherapy port was removed from the right internal jugular vein and subcutaneous tissue on the chest. Using Doppler ultrasound, the presence of a long fibrotic lateral thrombus was revealed, which did not obstruct blood return from the head. Through incision of the right cephalic vein a hydrophilic

FIGURE 1A.

Venography of left upper extremity – critical left bronchocephalic vein stenosis (indicated by arrow).

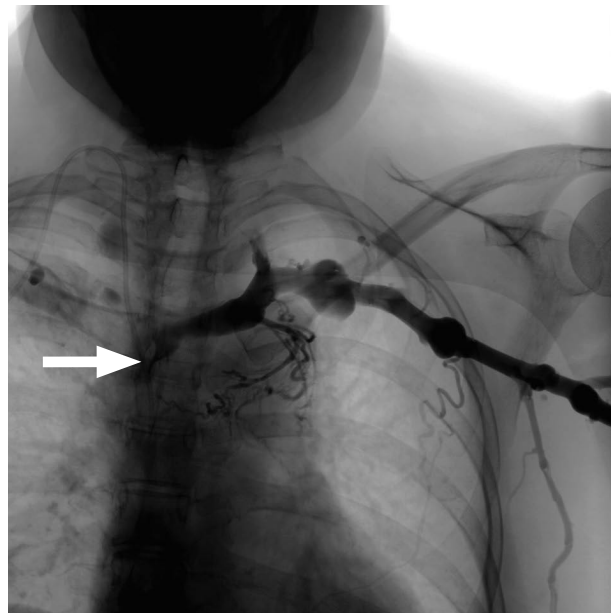
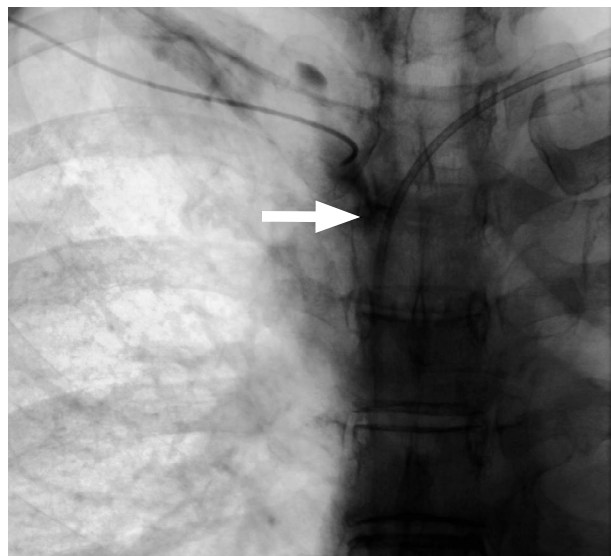


FIGURE 1B.

Venography of right upper extremity – complete occlusion of the right bronchocephalic vein (stop of blood flow indicated by arrow).



guidewire and 6F 11 cm port was inserted. The guidewire with a 6F catheter was passed through the obstructed fragment of the right brachiocephalic vein into vena cava superior, and then inferior. Next, a 12 × 40 mm balloon was inserted into the right brachiocephalic vein and pre-dilatation of the stricture was performed (Figure 3a, 3b). Then, two self-expanding SMART stents were inserted into the right brachiocephalic vein and superior

FIGURE 2A and 2B.

Balloon angioplasty of critical left bronchocephalic vein stenosis (arrows).

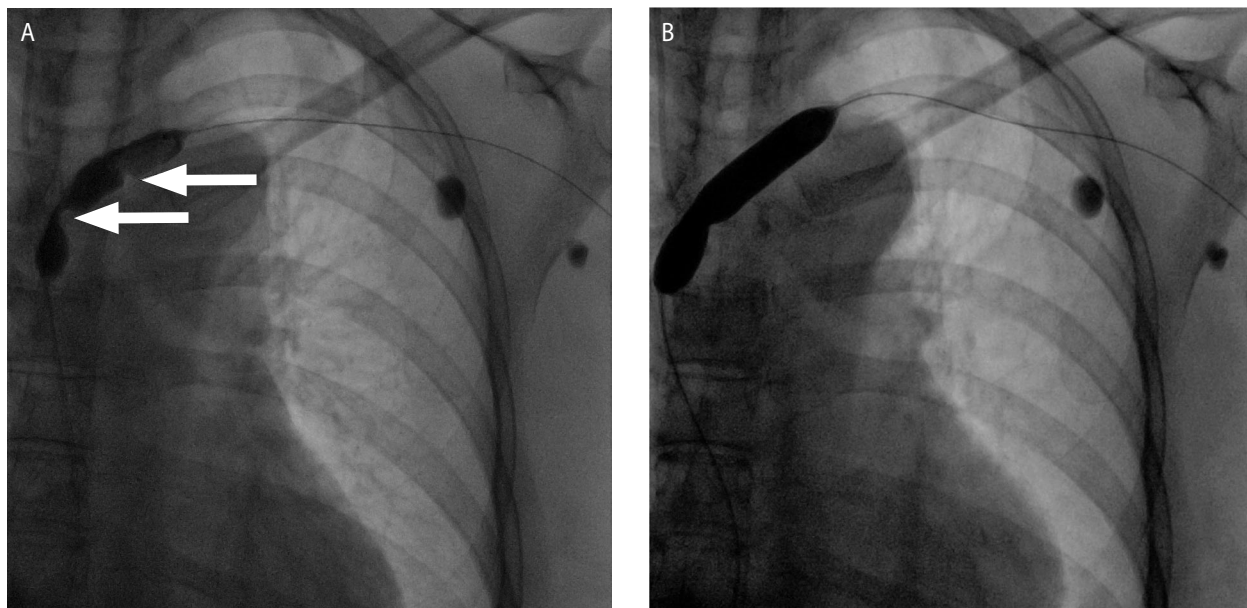
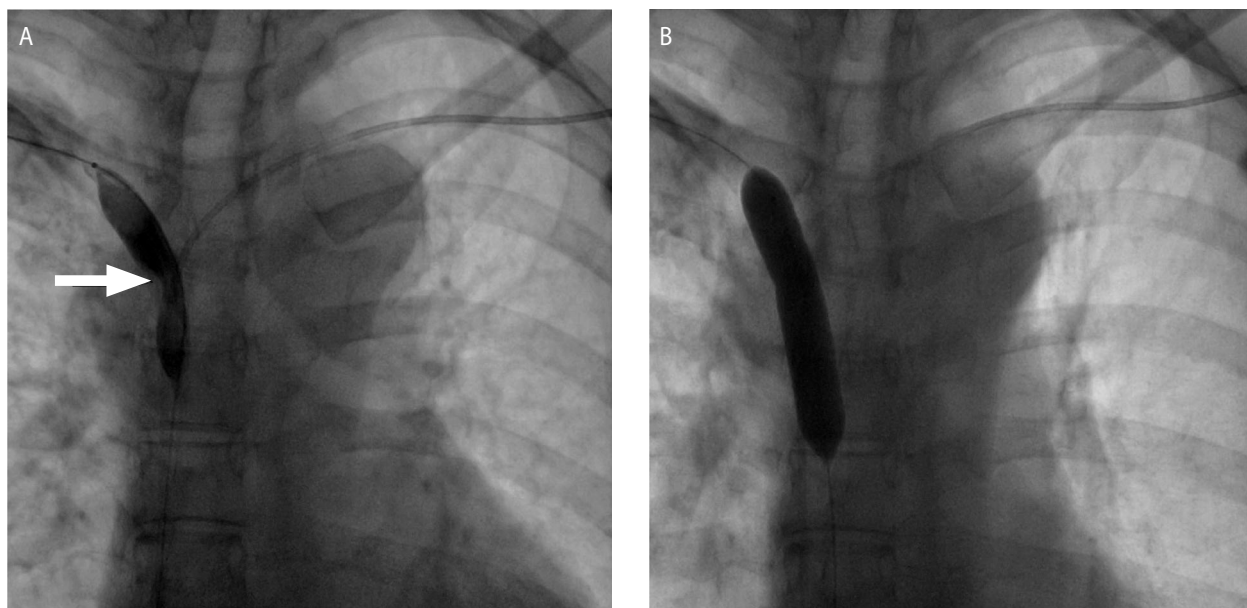


FIGURE 3A and 3B.

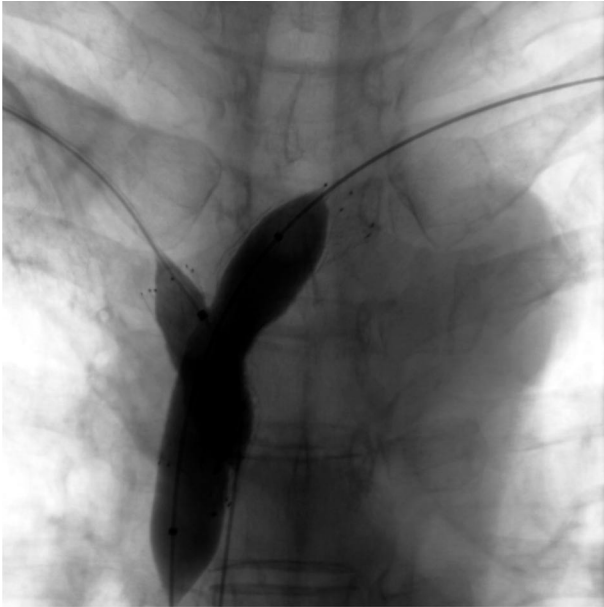Recanalization and balloon angioplasty of occluded right bronchocephalic vein.



vena cava (12 × 40 mm), and into the left brachiocephalic vein and superior vena cava (14 × 60 mm). The next stage of the procedure was dilation of both stents with a 12 × 20 mm balloon on the right side and a 14 × 60 mm balloon on the left side (Figure 4). Control phlebography showed normal bilateral blood flow through brachiocephalic veins and the superior vena cava (Figure 5a, 5b). The course of the procedure was uneventful.

The patient was put on a long-term low-molecular heparin treatment. After the procedure during several following days significant improvement of the patient's general condition was noted, symptoms of vena cava superior syndrome disappeared, headaches and facial edema subsided. The patient was discharged home in good general condition and transferred to her home oncological centre for further radiotherapy.

FIGURE 4.  
Two stents in the confluence of right and left brachiocephalic veins, and in the vena cava superior.

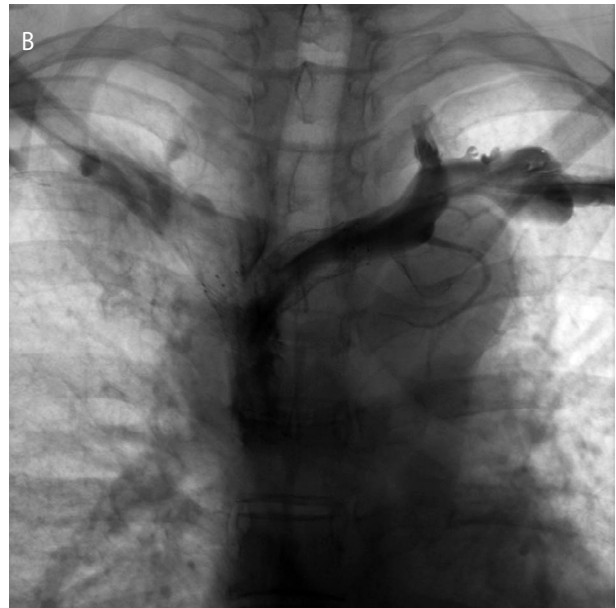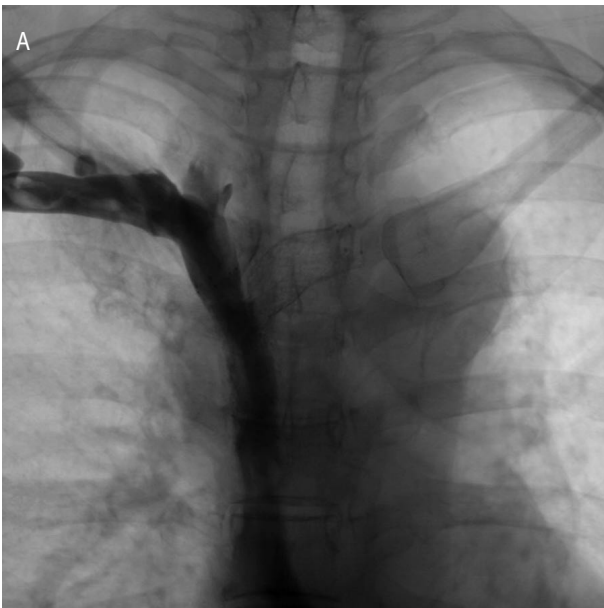


VCSS is usually caused by advanced neoplasms in the thoracic cavity [1]. Abnormal venous drainage from the upper part of the chest results from compression of the veins by neoplastic mass originating from the right main bronchus, upper lobe or enlarged mediastinal nodes [2]. It is usually accompanied by thrombosis, though infiltration of blood vessels is rare.

Main symptoms of VCSS include: facial and orbital swelling, edema of the upper limbs, dilatation of jugular veins, dyspnoea, cough, snoring, dysphagia, headaches, pain in the eyes, vision disturbances and impaired cognitive function. VCSS, if untreated, may lead to brain edema, respiratory tract edema and to coma and even death.

Polish experts claim that during history taking the exact onset, duration and intensity of symptoms must be noted [3], as well as details of the neoplasm and its treatment. The severity of VCSS depends on how rapidly the symptoms increase. The severity of VCSS may be determined according to a 5-step scale, including subjective and objective symptoms and signs [4]. The classification separates patients with direct life threatening in the course of VCSS and without such danger (Table 1).

FIGURE 5A and 5B.  
Venography after angioplasty and stenting – restored blood flow in both bronchocephalic veins and vena cava superior.



## DISCUSSION

Vena cava superior syndrome (VCSS) is a clinical manifestation of stricture or obstruction of the veins collecting blood from the head, neck and upper limbs. Constriction may involve the superior vena cava, or brachiocephalic veins or all these vessels at the same time.

The treatment of VCSS in patients with neoplasms is palliative. It depends on pathological diagnosis, stage of tumor advancement, intensity of symptoms and general prognosis [3]. Pharmacological treatment involves diuretics, glyocortikosteroids and thrombolytic treatment. Radiotherapy is currently the most common method of treatment in neoplasm-origin VCSS, and in small-cell

lung cancer leads to symptoms disappearance in 78% of patients, and in non-small-cell lung cancer it reaches 63%. Alleviation or disappearance of clinical symptoms may be observed after 72 h from the onset of irradiation [5]. Chemotherapy should be the treatment of choice in susceptible tumors (small-cell lung cancer, lymphomas, germinal tumors) – it leads to disappearance of symptoms in about 80% of cases. Conservative management proved successful in 77% of small-cell and 60% of non-small-cell lung cancer cases, with the risk of relapse 16.5% and 11%, respectively [6].

Percutaneous balloon angioplasty of the superior vena cava with the implantation of two stents seems a significantly promising

technique, especially in patients with severe symptoms grade 4 and 3, in whom causative treatment (radio- or chemotherapy) is not possible [3].

Venous vessels stenting may lead to rapid disappearance of symptoms, usually within 72 h, with the efficacy reaching 95% [7]. The risk of relapse is estimated at 11%. In patients with diagnosed relapse of VCSS repeated angioplasty and stenting is suggested. Long term patency of blood vessels is achieved in 92% of patients after this procedure. Surgical approach in VCSS is not recommended, especially in patients in poor clinical condition and with short time of prognosed survival.

TABLE 1.  
Classification of the severity of VCSS (modified on the basis of the literature [3,4]).

Degree	Symptoms	Frequency (%)	Definition
0	none	10	radiological signs of the compression on VCS without symptoms
1	mild	25	swelling of the face or neck (widening of the blood vessels), cyanosis, flushing
2	moderate	50	swelling of the face and/or neck with dysfunction (mild dysphagia, cough, mild or moderate limitation of movement of the head, jaw or eyelids, blurred vision due to swelling eyeballs)
3	serious	10	mild or moderate swelling of the brain (headache and/or dizziness) or mild to moderate laryngeal edema or decrease cardiac reserve (syncope on titling forward)
4	life-threatening	5	clinically significant cerebral edema (confusion, clouding) or significant swelling of the larynx (stridor) or severe haemodynamic abnormalities (syncope, hypotension, renal failure)
5	fatal	< 1	death

## References

1. Escalante CP. Causes and management of superior vena cava syndrome. *Oncology* 1993; 7: 61-8.
2. Ganeshan A, Hon LQ, Warakaulle DR et al. Superior vena caval stenting for SVC obstruction: current status. *Eur J Radiol* 2009; 71(2): 343-9.
3. Kowalski DM, Krzakowski M. Zespół żyły głównej górnej – rozpoznawanie i leczenie. In: *Postępowanie w powikłaniach sercowo-naczyniowych w raku płuca. Rekomendacje Krajowego Nadzoru Kardiologicznego i Onkologicznego dotyczące bezpieczeństwa kardiologicznego u chorych na raka płuca*. Krzakowski M, Opolski G, Szmit S (ed.). Medical Education, Warszawa 2012: 21-29.
4. You JB, Wilson LD, Detterbeck FC. Superior vena cava syndrome – a proposed classification system and algorithm for management. *J Thorac Oncol* 2008; 3: 811-814.
5. Wilson LD, Detterbeck FC, Yahalom J. Superior vena cava syndrome with malignant causes. *N Engl J Med* 2007; 356: 1862-1869.
6. Rowell NP, Gleeson FV. Steroids, radiotherapy, chemotherapy and stents for superior vena caval obstruction in carcinoma of the bronchus. *Cochrane Database Syst Rev* 2001(4): CD001316.
7. Sobrinho G, Aguiar P. Stent placement for the treatment of malignant superior vena cava syndrome – a single-center series of 56 patients. *Arch Bronconeumol* 2014; 50(4): 135-40.

### Correspondence:

Szymon Darocha, MD

Department of Pulmonary Circulation and Thromboembolic Diseases,  
Centre of Postgraduate Medical Education, European Health Centre Otwock  
05-400 Otwock, ul. Borowa 18/18, Poland  
tel.: (+48) 22 710-30-54, e-mail: szymon.darocha@gmail.com