

Cardiac amyloidosis: a hidden cause of cardiovascular complications in oncology practice

*Prof. Beata Mladosevicova, MD PhD¹, Zuzana Poljak, RNDr., PhD¹,
Olja El-Hassoun, MD², Lubica Roziakova, MD PhD^{1,3}, Andrea Carter, MD⁴*

¹ *Institute of Clinical Pathophysiology, Faculty of Medicine, Comenius University, Bratislava, Slovak Republic*

² *Laboratory of Pathology, Alpha Medical Pathology, Inc., Martin, Slovak Republic*

³ *Clinic of Hematology and Transfusiology, Faculty of Medicine, Comenius University and Slovak Medical University, Bratislava, Slovak Republic*

⁴ *University of Maryland University College, The Sciences Programs, Adelphi, Maryland, USA*



ABSTRACT

Amyloidosis is rare, but known cause of heart failure, cardiomyopathy, coronary artery disease, disorders of cardiac conduction system and valvular damage. Disease often remains undetected until it reaches an advanced stage. Currently, we distinguish several types of amyloidosis. Cardiac amyloidosis may be caused by cancer, chronic inflammation, genetic factors and by aging related processes. Overproduction of amyloidogenic proteins by tumor cells has a key role in the pathogenesis of immunoglobulin light chain amyloidosis. Cardiovascular complications in patients with amyloidosis can be induced by insoluble deposits of misfolded proteins or by direct toxic effects of amyloidogenic molecules on cardiomyocytes and endothelial cells.

In this review we focus mainly on pathophysiological mechanisms of cardiac amyloidosis, classification of cardiac amyloidosis types and their cardiovascular manifestations.

KEY WORDS: amyloidosis, cardiotoxicity, cancer, transthyretin

INTRODUCTION

Amyloidosis is a disorder characterized by the formation of abnormal amyloidogenic molecules that accumulate as insoluble fibrillar proteins in the extracellular matrix of different tissues and organs. This accumulation of the amyloid causes morphological and functional changes in the affected organs resulting in the pressure atrophy of cells in its vicinity. Amyloid is also partially toxic for cells. Amyloid deposits contain up to 95% of insoluble proteins with the stabilizing non-fibrillar material making up the remainder of the deposit.

So far, 28 different types of proteins with amyloidogenic potential in vivo have been identified. Nine of them can cause cardiac complications [1]. In normal circumstances, such substances are degraded intracellularly in proteasomes, or macrophages. In amyloidosis, there is failure in "control and quality" mechanisms, leading to extracellular accumulation of the amyloid [2, 3]. Amyloidosis usually develops in patients with an enzymatic disorder that impairs the organism's ability to degrade amyloid. Thus, the organism's ability to eliminate amyloid is negligible. Genetically-based structural abnormalities in amyloid molecules ensure their resistance to degradation by macrophages.

Different amyloidogenic proteins cause different, although often overlapping clinical syndromes. The clinical picture depends on the affected organ, which is usually the heart, liver or kidneys. The molecular pathogenesis of organ tropism is not yet clear, but contributing factors include local protein concentration, interaction with collagen, presence of tissue specific glycosaminoglycans, pH, local specific proteolytic enzymes and cell receptors [4]. Amyloidosis can occur as hereditary or acquired, localized or systemic, fatal or only as an accidental finding.

Amyloidosis can be caused by:

- neoplastic disease (mainly myeloma, lymphoma or endocrine tumors)
- chronic inflammation
- genetic factors (mutations, ethnicity)
- aging-related biochemical processes in the organism [5].

Overproduction of amyloidogenic proteins by tumor cells has a key role in the pathogenesis of immunoglobulin light chain amyloidosis and endocrine peptide-related amyloidosis.

Light chain immunoglobulins amyloidosis is associated with myeloma, seldom with non-Hodgkin lymphoma, MALT and lymphoplasmocytic lymphoma. Endocrine peptide-related amyloidosis was observed in cases of insulinoma, prolactinoma, thyroid medullary carcinoma and pituitary adenoma.

The fact that neoplastic disease can cause amyloidosis is well known. However, amyloidosis was demonstrated as an inducer

of a neoplastic process. Hereditary transthyretin and systemic amyloidosis can induce non-Hodgkin lymphoma. An increased risk for myeloma, non-Hodgkin lymphoma, and spinocellular carcinoma was demonstrated in a group of 1400 patients with nonhereditary amyloidosis. Myeloma and skin tumors were diagnosed 7 to 8 years earlier in patients with amyloidosis in comparison to those without it [6].

Chronic inflammation associated with the secondary amyloidosis plays a role in the pathogenesis of spinocellular carcinoma of the skin and endometrial carcinoma. In hereditary transthyretin amyloidosis and senile systemic amyloidosis, malignant transformation is caused by chronic stimulation or inflammation. In both types of amyloidosis fragments and aggregates of transthyretin amyloid accumulate in different tissues causing long-lasting immune reactions.

CARDIAC AMYLOIDOSIS TYPES

Cardiac amyloidosis is defined by the presence of extracellular deposits of amyloid in the heart. Infiltration was observed in all anatomical sites, including the atria and ventricles, perivascular space (most often of small vessels), as well as in the valves and the conducting system. The deposition of fibrils caused thickening of the chamber walls and subsequent impairment of relaxation. In cardiac amyloidosis the following are high risk precursor molecules:

- light chain immunoglobulins (AL) amyloidosis
- transthyretin particles (formerly known as senile systemic amyloidosis, SSA)
- serum amyloid A (secondary amyloidosis associated with chronic inflammation or SAA)
- atrial natriuretic peptide (isolated atrial amyloidosis or IAA) (Fig. 1).

It should be noted that mutant forms of apolipoprotein A1, fibrinogen and gelsolin are also precursor molecules for amyloid deposits. However, their occurrence in the heart is sporadic.

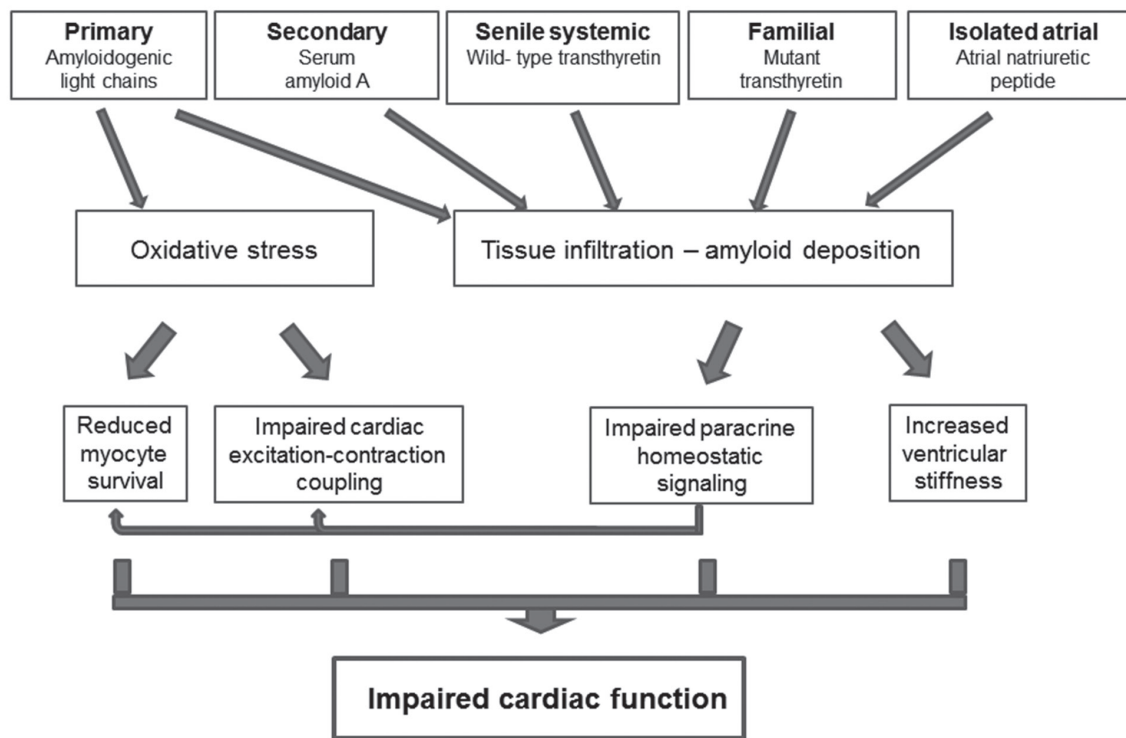
Light chain immunoglobulin (AL) amyloidosis

Light chain immunoglobulin amyloidosis constitutes 85% of all types of amyloidosis. This subtype is most often associated with the cardiac damage [8, 9]. The incidence of primary AL amyloidosis is up to 9 cases in million per year [9].

AL fibrils are composed of fragments or molecules of monoclonal light chain immunoglobulins. AL fibrils are unique to each patient. The physical and chemical attributes of some subtypes of light chain immunoglobulins determine the target organ of

FIGURE 1.

Pathophysiological mechanisms of cardiac damage according to different types of amyloidosis (modified according to [7]).



accumulation. For example, $\Lambda\lambda_{\text{VI}}$ light chains often accumulate in the kidneys while $\Lambda\lambda_{\text{II}}$ accumulate primarily in the heart [10]. Genetic analysis of plasma cells producing amyloidogenic immunoglobulins revealed that amyloid tissue tropism is associated with a gene in the variable segment of the light chain [11].

Transthyretin-related amyloidosis

Cardiac amyloidosis can be also caused by the accumulation of transthyretin amyloid (TTR).

There are two types of TTR amyloidosis:

- hereditary transthyretin amyloidosis (ATTR)
- non-hereditary form (formerly known as senile systemic amyloidosis, SSA).

Hereditary transthyretin amyloidosis (or mutant transthyretin-related form) results from a hereditary mutation of TTR protein. If one parent is affected, there is a 50% chance for the mutation to be passed to the next generation. Even though the TTR mutation is congenital, first clinical manifestations of ATTR appear between the 3rd and 6th decade of life. The clinical picture of the ATTR depends on the specific mutation in the TTR molecule. So far, 113 amyloidogenic point mutations causing con-

formational change of the TTR tetramer to monomer have been identified. These point mutations result in the deposition of the amyloid mainly in the heart and nervous system. The accumulation of TTR amyloid in the myocardium can cause hypertrophic cardiomyopathy, and occasionally arrhythmia [5]. The most common mutation is Val30Met, which accounts for over 60% of the cases [12]. In comparison to AL amyloidosis, ATTR is a slowly progressing disease, with most patients surviving for many years after the first onset of symptoms [13].

Non-hereditary form (wild-type or senile form) of amyloidosis is related to the decomposition of the normal TTR molecule. The amyloidogenic transthyretin particles accumulate mainly in the heart. This form is rarely clinically diagnosed. Most importantly, there has been increasing evidence that this type of cardiac amyloidosis is underdiagnosed since it affects up to 25% of the senile population [6]. This form is found mostly in the male population [14]. Increased life expectancy and advancement in diagnostic methods may result in new challenges when treating this population.

Given that the heart is the only clinically affected organ in this type of amyloidosis, perimaleolar edema or dyspnea are usually the first signs of disease. These signs are automatically associated

with congestive heart failure. Interestingly, many patients with this form of amyloidosis have reported tingling and hypoesthesia in the hands. In these patients, the carpal tunnel syndrome induced by amyloid deposits can manifest 3–5 years prior to the onset of cardiac symptoms [15].

Secondary serum amyloid A amyloidosis

Serum amyloid A (SAA) is the common name for a group of proteins coded by several genes [2]. In this type of amyloidosis, heart deposits are exceedingly rare and manifest with bland symptoms. Secondary SAA amyloidosis is a reaction to chronic inflammation. It occurs in 20% of patients with rheumatic arthritis. The incidence of amyloidosis in these patients is decreasing with better management of chronic inflammation. The heart is affected in 2% of the cases [16].

Isolated atrial amyloidosis

Isolated atrial amyloidosis is an example of amyloidosis local and specific to the myocardium. It is a disease of the senile population with a female predominance [14]. Amyloid forms from the atrial natriuretic peptide (ANP) and deposits mainly in the atria. There was no evidence that conditions causing increase in ANP production would support the development of isolated atrial amyloidosis. This structural abnormality was always diagnosed post mortem. The affected portion of the atrium showed a higher risk of perforation. The prevalence of isolated atrial amyloidosis increases with age, reaching up to 95% in 81 to 90-year-old patients [17, 18]. Despite its high prevalence, isolated atrial amyloidosis is considered to be of no clinical relevance to heart failure [19]. Nevertheless, there are studies that predict a role of isolated atrial amyloidosis in the development of disorders of the conduction system and atrial fibrillation in older population [1, 18]. A recent study involving a group of middle-aged patients with mean age of 40 years with diagnosis of congestive heart failure showed the presence of amyloid deposits in 91.6% of cases, where 93.9% of them were positive for ANP [20]. This demonstrates the need to monitor these patients due to an increased risk of progressive heart amyloidosis.

AL AMYLOIDOSIS AND CARDIOVASCULAR DAMAGE

AL amyloidosis is a monoclonal gammopathy frequently resulting from a myeloma, Waldenström's macroglobulinemia or a monoclonal gammopathy of unknown significance. Between 10% to 20% of myeloma patients develop AL amyloidosis [21, 22]. Monoclonal plasma cells which produce amyloidogenic light chains

are located in the bone marrow, or the spleen. Patients with primary AL amyloidosis have amyloid deposits in the myocardium that lead to the development of rapidly progressive heart failure/infiltrative cardiomyopathy, ventricular tachyarrhythmia and more than 50% mortality rate within one year after the onset of symptoms [23]. Primary AL amyloidosis typically affects older adults with median age at diagnosis 67 years. Approximately fifty percent patients with cardiac AL amyloidosis have renal involvement, about 16% have liver involvement, and about 10% have neurological involvement [9].

The pathogenesis of AL amyloid cardiomyopathy was assumed to be an infiltrative process with extracellular deposits of amyloid fibrils that cause structural and functional damage to the heart. The degree of cardiac infiltration does not always correspond to the degree of clinical dysfunction [24]. However, mortality rate directly corresponds to the levels of circulating free amyloidogenic light chains. Their reduction improves survival rates, even though cardiac amyloid deposits remain unaffected [25–27].

At the level of the cardiovascular system the AL amyloidosis causes:

- infiltrative myocardial damage
- damage of blood vessels
- valvular damage
- arrhythmias
- thromboembolism
- pulmonary hypertension and *cor pulmonale*.

Infiltrative myocardial damage

Infiltrative damage of the myocardium is characterized by extracellular deposition of insoluble fibrils composed of monoclonal light chain immunoglobulins with specific mutation. Only a minor portion of the immunoglobulins possesses amyloidogenic potential. Amyloidogenic light chains with specific structural changes, such as amino acid insertions or replacement of hydrophilic side chains with hydrophobic ones, facilitate insolubility and aggregation of proteins. It was demonstrated that a single mutation can induce an increased production of oligomers and fibrils [28, 29]. Posttranslational modifications have an important role in the stabilization of the pathological conformational changes and the bonding between amyloid fibrils and cells of the target organs. Glycosaminoglycans play a vital role in the deposition of amyloid. Increased levels of serum matrix-metalloproteinase-9 and the tissue inhibitor matrix-metalloproteinase-1 were demonstrated in patients with AL cardiomyopathy when compared with hereditary transthyretin amyloidosis with cardiac involvement. Such findings suggest that proteolysis of extracellular matrix could play an important role in the pathogenesis of the cardiac amyloidosis [30].

Circulating amyloidogenic light chains integrate with membrane components of cardiomyocytes as well as the extracellular matrix. The molecular mechanism of the direct cardiotoxic effect of amyloidogenic proteins in AL amyloidosis is a subject of thorough investigation. Isolated light chains from peripheral blood of patients with AL amyloidosis with cardiomyopathy induce oxidative stress, cell dysfunction and apoptosis of isolated mature cardiomyocytes independently from the formation of fibrils [1, 31, 32].

Recent studies demonstrated that patients with AL cardiomyopathy have an increased expression of stanniocalcin-1 (STC-1) in the heart tissue [33]. This glycoprotein can be induced *in vitro* in isolated cardiomyocytes in reaction to AL light chains. Non-amyloidogenic light chains do not cause such reaction [32]. In mammals, STC-1 is associated with angiogenesis, apoptosis, ischemic damage, inflammation, cell metabolism, differentiation with endothelial permeation, as well as with oxidation stress and impairment of calcium homeostasis. Its pro-apoptotic and anti-apoptotic effect is dependent upon the stimulus and cell type. STC-1 facilitates cell death as a reaction to various stress signals. The cardiotoxic effect of STC-1 is mediated by the loss of mitochondrial membrane potential, production of reactive forms of oxygen, increase in the mitochondrial calcium levels accompanied with their decrease in the cytosol [9, 33]. Disrupted calcium levels cause contractility disorder, increased levels of free radicals and mitochondrial dysfunction. The typical cardiac damage in patients with AL amyloidosis is heart failure with normal ejection fraction or infiltrative cardiomyopathy [3–5, 9].

Blood vessels damage

The amyloid often infiltrates vessels thus causing impairment of vasodilatation, that can lead to myocardial ischemia. The intramyocardial vessels are affected in 90% of patients with AL amyloidosis [34]. In rare cases, amyloid deposits in epicardial vessels cause ischemic effects. These deposits are often not revealed by coronary angiography. However, severe vessel obstruction by amyloid is rather rare. On the other hand, an increased incidence of microinfarcts, ischemia and fibrosis contribute to myocardial dysfunction. Cytotoxic effects of amyloid were also demonstrated in blood vessels. Light chains cause endothelial dysfunction related to increased apoptosis of endothelial cells in coronary arteries [35].

Valvular damage

Even though valves are commonly histologically affected, clinical symptoms and hemodynamic valvular dysfunction are rare find-

ings in amyloidosis [36]. Valve damage is often minimal. Usually the amyloid deposits result in the formation of 1–4 mm size nodules. The prevalence of involvement among of all types of valves is similar. Amyloid deposition in valves can be associated with both stenosis and regurgitation. Valvular insufficiency can develop alongside endocardial amyloid deposition.

Arrhythmias

Amyloid deposits in the heart can be accompanied by fibrosis of the heart's conduction system. Fibrosis, a progressive process, causes abnormalities of conduction, electromechanical dissociation or impairment in automation centers, resulting in fatal arrhythmia [37]. Although all parts of the conduction system can be affected, symptomatic dysfunction of the sinoatrial and atrioventricular nodes are rare. Conduction disorders often appear in the bundle of His and Purkinje fibers. An increased risk of ventricular arrhythmia was also found. Atrial arrhythmia findings, such as atrial fibrillation affecting up to 10–15% of patients, are typical in the advanced stage of the disease [14].

Thromboembolism

AL amyloidosis is associated with an increased risk of atrial thrombosis when compared to other types of amyloidosis. Thromboembolism can have serious consequences in patients with AL amyloidosis [38]. An intracranial thrombus can be the only early sign of cardiac amyloidosis, although the mechanism of its formation remains unclear. It is predicted that the process is facilitated by amyloid deposits resulting in endocardial, myocardial and endothelial damage, cardiotoxicity as well as hypercoagulation [38]. Patients show a number of similar signs – normal sinus rhythm, normal or slightly decreased left ventricle ejection fraction. Intracardiac thrombi are usually diagnosed in the phase of catastrophic pulmonary or systemic embolism. The prognosis is poor with a survival rate of days to months after the diagnosis [39].

Pulmonary hypertension and *cor pulmonale*

In some cases amyloid infiltrates cause marked dilation of the right ventricle in comparison to the left. Such cases are associated with an average survival of 4 months. This condition can be caused by an increased end-diastolic pressure in the left ventricle, or by an increased pulmonary vascular resistance due to amyloid deposition in the pulmonary vasculature. In rare cases, pericardial damage can lead to amyloid infiltration of the lungs with progression to pulmonary hypertension and *cor pulmonale* [40].

CONCLUSION

Cardiac amyloidosis should be suspected in patients with heart failure (and preserved ejection fraction), cardiomyopathy, coronary artery disease, arrhythmias, thromboembolism, pulmonary hypertension, *cor pulmonale* or in association with sudden cardiac death. Heart damage is mostly caused by AL type of amyloidosis. Untreated patients with AL amyloidosis are at high risk of progressive heart failure. Patients with wild-type transthyretin-related cardiac amyloidosis have a favorable prognosis due to slow progression.

Evolving knowledge of pathogenesis of cardiac amyloidosis on molecular, cellular and systemic levels contributes to early diagnosis and better treatment strategies for patients with cardiac amyloidosis.

Acknowledgement

This work was supported by the grant of Ministry of Education of Slovak Republic VEGA 1/0906/14.

References

1. Guan J, Mishra S, Falk RH et al. Current perspectives on cardiac amyloidosis. *Am J Physiol Heart Circ Physiol* 2012; 302(3): H544-H552.
2. Poljak Z, El-Hassoun O, Hulín I et al. Cardiac amyloidosis in the context of new pathophysiological knowledge. *Cardiology Lett* 2014; 23(4): 267-274.
3. Yusuf SW, Negi SI, Lenihan DJ. Infiltrative cardiomyopathy and pericardial disease. *Semin Oncol* 2013; 40(2): 199-209.
4. Gillmore JD, Hawkins PN. Pathophysiology and treatment of systemic amyloidosis. *Nat Rev Nephrol* 2013; 9(10): 574-586.
5. Pika T, Vymetal J, Latalova P. Amyloidosa a postižení srdce: 186-191. In: Mladosevicova B. et al. *Kardioonkologie*, 2. ed. Grada Publishing a.s. 2014, Praha.
6. Hemminki K, Li X, Försti A et al. Cancer risk in amyloidosis patients in Sweden with novel findings on non-Hodgkin lymphoma and skin cancer. *Ann Oncol* 2014; 25(2): 511-518.
7. Sawyer DB, Skinner M. Cardiac amyloidosis: shifting our impressions to hopeful. *Curr Heart Fail Rep* 2006; 3(2): 64-71.
8. Falk RH. Cardiac amyloidosis: a treatable disease, often overlooked. *Circulation* 2011; 124(9): 1079-1085.
9. Gertz MA, Dispenzieri A, Sher T. Pathophysiology and treatment of cardiac amyloidosis. *Nat Rev Cardiol* 2014 [online: doi: 10.1038/nrcardio.2014.165].
10. Abraham RS, Geyer SM, Price-Troska TL et al. Immunoglobulin light chain variable (V) region genes influence clinical presentation and outcome in light chain-associated amyloidosis (AL). *Blood* 2003; 101(10): 3801-3808.
11. Bellotti V, Chiti F. Amyloidogenesis in its biological environment: challenging a fundamental issue in protein misfolding diseases. *Curr Opin Struct Biol* 2008; 18(6): 771-779.
12. Špalek P. Familiární amyloidná polyneuropatia. *Neurol prax* 2013; 14(6): 296-300.
13. Quarta CC, Kruger JL, Falk RH. Cardiac amyloidosis. *Circulation* 2012; 126(12): e178-e182.
14. Falk RH, Dubrey SW. Amyloid heart disease. *Prog Cardiovasc Dis* 2010; 52(4): 347-361.
15. Dubrey SW, Falk RH. Amyloid heart disease. *Br J Hosp Med* 2010; 71: 76-82.
16. Banyersad SM, Moon JC, Whelan C et al. Updates in cardiac amyloidosis: a review. *J Am Heart Assoc* 2012; 1(2): e000364.
17. Steiner I. The prevalence of isolated atrial amyloid. *J Pathol* 1987; 153(4): 395-398.
18. Goette A, Röcken C. Atrial amyloidosis and atrial fibrillation: a gender-dependent "arrhythmogenic substrate"? *Eur Heart J* 2004; 25(14): 1185-1186.
19. Fikrle M, Paleček T, Kuchynka P et al. Cardiac amyloidosis: A comprehensive review. *Cor et Vasa* 2013; 55: e60-e75.
20. Millucci L, Ghezzi L, Bernardini G et al. Prevalence of isolated atrial amyloidosis in young patients affected by congestive heart failure. *Scientific World Journal* 2012: 29386.
21. Falk RH. AL amyloidosis or multiple myeloma? An important distinction. *Br J Haematol* 2014; 164(5): 748-9.
22. Dispenzieri A, Kyle RA, Gertz MA et al. Survival in patients with primary systemic amyloidosis and raised serum cardiac troponins. *Lancet* 2003; 361(9371): 1787-1789.
23. Merlini G, Seldin DC, Gertz MA. Amyloidosis: pathogenesis and new therapeutic options. *J Clin Oncol* 2011; 29(14): 1924-1933.
24. Rapezzi C, Merlini G, Quarta CC et al. Systemic cardiac amyloidoses: disease profiles and clinical courses of the 3 main types. *Circulation* 2009; 120(13): 1203-1212.
25. Palladini G, Campana C, Klersy C et al. Serum n-terminal pro-brain natriuretic peptide is a sensitive marker of myocardial dysfunction in AL amyloidosis. *Circulation* 2003; 107: 2440-2445.
26. Palladini G, Merlini G. Systemic amyloidoses: what an internist should know. *Eur J Intern Med* 2013; 24(8): 729-739.
27. Levinson RT, Olatoye OO, Randles EG et al. Role of mutations in the cellular internalization of amyloidogenic light chains into cardiomyocytes. *Sci Rep* 2013; 3: 1278.

28. Peterson FC, Baden EM, Owen BA et al. A single mutation promotes amyloidogenicity through a highly promiscuous dimer interface. *Structure* 2010; 18: 563-570.
29. Martin DJ, Ramirez-Alvarado M. Comparison of amyloid fibril formation by two closely related immunoglobulin light chain variable domains. *Amyloid* 2010; 17: 129-136.
30. Biolo A, Ramamurthy S, Connors LH et al. Matrix metalloproteinases and their tissue inhibitors in cardiac amyloidosis: relationship to structural, functional myocardial changes and to light chain amyloid deposition. *Circ Heart Fail* 2008; 1(4): 249-257.
31. Shi J, Guan J, Jiang B et al. Amyloidogenic light chains induce cardiomyocyte contractile dysfunction and apoptosis via a non-canonical p38alpha MAPK pathway. *Proc Natl Acad Sci USA* 2010; 107: 4188-4193.
32. Mishra S, Guan J, Plovie E et al. Human amyloidogenic light chain proteins result in cardiac dysfunction, cell death, and early mortality in zebrafish. *Am J Physiol Heart Circ Physiol* 2013; 305(1): H95-H103.
33. Guan J, Mishra S, Shi J et al. Stanniocalcin1 is a key mediator of amyloidogenic light chain induced cardiotoxicity. *Basic Res Cardiol* 2013; 108(5): 378.
34. Desai HV, Aronow WS, Peterson SJ et al. Cardiac amyloidosis: approaches to diagnosis and management. *Cardiol Rev* 2010;18 (1): 1-11.
35. Migrino RQ, Truran S, Gutterman DD et al. Human microvascular dysfunction and apoptotic injury induced by AL amyloidosis light chain proteins. *Am J Physiol Heart Circ Physiol* 2011; 301(6): H2305-H2312.
36. Halwani O, Delgado DH. Cardiac amyloidosis: an approach to diagnosis and management. *Expert Rev Cardiovasc Ther* 2010; 8(7): 1007-1013.
37. García-Pavía P, Tomé-Esteban MT, Rapezzi C. Amyloidosis. Also a heart disease. *Rev Esp Cardiol (engl. ed.)* 2011; 64(9): 797-808.
38. Feng D, Edwards WD, Oh JK et al. Intracardiac thrombosis and embolism in patients with cardiac amyloidosis. *Circulation* 2007; 116(21): 2420-2426.
39. Feng D, Klarich K, Oh JK. Intracardiac Thrombosis, Embolism and Anticoagulation Therapy in Patients with Cardiac Amyloidosis – Inspiration from a Case Observation [online: <http://cdn.intechopen.com/pdfs-wm/23846.pdf>].
40. Dingli D, Utz JP, Gertz MA. Pulmonary hypertension in patients with amyloidosis. *Chest* 2001; 120: 1735-1738.

Correspondence:

Prof. Beata Mladosevicova, MD PhD
Institute of Clinical Pathophysiology, Faculty of Medicine, Comenius University
Sasinkova 4, 813 72 Bratislava, Slovak Republic
e-mail: beata.mladosevicova@fmed.uniba.sk