

IgM multiple myeloma: diagnostic difficulties and results of bortezomib treatment – case report

Rafał Machowicz, MD, MSc in biology, Kamila Skwierawska, MD, Krzysztof Mądry, MD PhD, Michał Górka, MD, Jagoda Żurawska, MD, Piotr Kacprzyk, MD, Anna Waszczuk-Gajda, MD PhD, prof. Jadwiga Dwilewicz-Trojaczek, MD PhD
Department of Hematology, Oncology and Internal Diseases, Medical University of Warsaw



ABSTRACT

The IgM paraprotein secretion is most frequently associated with Waldenström's macroglobulinemia. In very rare cases it may also occur in multiple myeloma. The diagnostic and therapeutic process of a 84 year old male suffering from IgM multiple myeloma is described, including difficulties in establishing this diagnosis. Due to infectious complications, after the first cycle of melphalan–prednisone–bortezomib treatment, melphalan was stopped, subsequently, bortezomib and prednisone doses were also reduced. Two treatment interruptions have occurred. Despite reduced treatment intensity, the patient was in very good partial remission, while the toxicity profile was acceptable.

IgM multiple myeloma should be included in the differential diagnosis of IgM paraproteinemia, also when osteolytic lesions and translocation 11:14 are not detected. Bortezomib-based therapy can be effective in elderly patients (also in those suffering from cardiac insufficiency), even when dose reduction is required.

KEY WORDS: multiple myeloma, IgM, Waldenström's macroglobulinemia, bortezomib

INTRODUCTION

Multiple myeloma is a plasmocyte dyscrasia with an incidence of 5.8/100,000/year [1]. Clonal cells usually retain the ability to produce immunoglobulin – most often IgG (52%) or IgA (21%) class, less frequently IgD (2%) or IgE (<0.01%), while cases of IgM multiple myeloma are scarce [2]. Detection of the IgM paraprotein itself is not that rare. Its presence is associated with Waldenström's macroglobulinemia – lymphoma deriving from a transformed cell being in an intermediate stage between lymphocyte B and plasmocyte (incidence of 3/1mln/year) [3]. The decision as to the diagnosis of IgM multiple myeloma or Waldenström's macroglobulinemia is not only theoretic. They are distinct nosological entities with different prognosis, complications and, most importantly, different optimal treatments [4].

The aim of this work is to present the diagnostic and therapeutic process of a patient with IgM multiple myeloma, including the difficulties in establishing this diagnosis.

CASE DESCRIPTION

An eighty four year old man presented in June 2013 to the Department of Hematology, Oncology and Internal Diseases with a suspicion of myelodysplastic syndrome (WBC 4.3 G/l, Hb 11.0 g/dl, PLT 87 G/l) with increasing fatigue and dyspnea. He had a long history of heart disease (chronic heart failure NYHA II, implantation of mechanical aortic valve in 2000, chronic atrial flutter, chronic anticoagulation with acenocumarol), and additionally: stage 3 of chronic kidney disease, cholelithiasis and knee joint pain. Despite the age and above-mentioned history, the patient was in fairly good clinical condition (ECOG 1, Karnofsky 80%). There were no signs of hyperviscosity syndrome.

Hyperproteinemia (total protein 11.8 g/dl) and peak of monoclonal protein (5.07 g/dl) detected in serum protein electrophoresis suggested that the cause of cytopenia was not MDS, but rather multiple myeloma infiltration. When the paraprotein was typed as IgM kappa with kappa free light chains (IgM concentration of 7896 mg/dl), Waldenström's macroglobulinemia seemed to be more probable. This diagnosis was additionally supported by the lack of osteolytic lesions in a bone X-ray.

Neither hepatomegaly nor lymphadenopathy was detected in physical examination and imaging. The key for establishing the diagnosis was the bone marrow trephine biopsy results: 49% plasmocytes in cytology, 4% of CD38++, CD138++, CD56- cells in cytometry. Histopathology (with immunohistochemistry) revealed almost complete bone marrow infiltration with multiple myeloma cells (CD138+, cycl D1+, CD56-) with a restriction of

kappa light chain secretion. Antigens CD20 and CD117 were not present on these cells.

Other important results were: the presence of the paraprotein (free light chains kappa) in immunofixation of the urine proteins, elevated plasma concentration of kappa free light chains (132 mg/l) and β 2-microglobulin (5.37 mg/l). The result of Congo red staining of the trephine biopsy sample was negative. Cryoglobulins were not detected. Creatinine concentration was 1.72 mg/dl. In the cytogenetic bone marrow analysis, the normal male karyotype (46,XY) was found. With the use of FISH technique, 3 cell lines were detected: 96% – normal, 3% without Y chromosome, 1% with two Y chromosomes (alterations attributable probably to age).

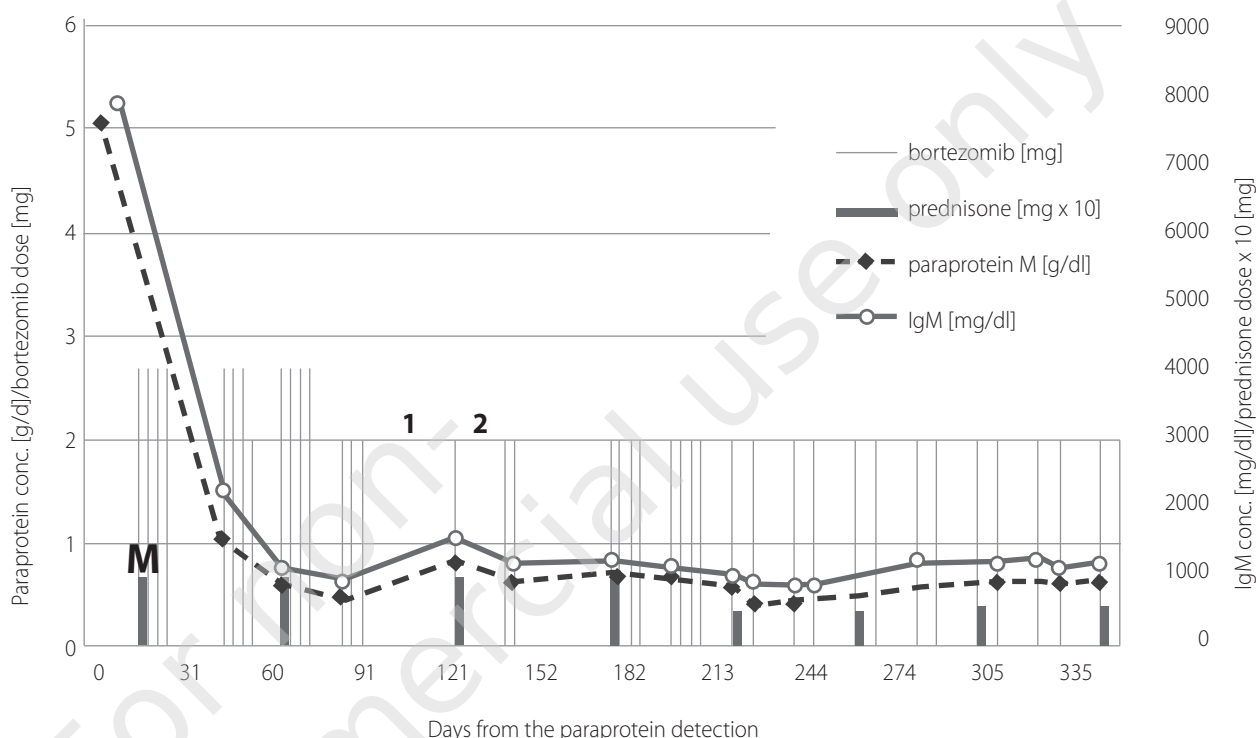
Finally, the IgM kappa multiple myeloma (ISS-2) was diagnosed (according to the IMWG criteria: presence of IgM paraprotein + bone marrow involvement + anemia).

TREATMENT COURSE

The patient was enrolled into a multiple myeloma treatment program with bortezomib as a first line therapy in combination with melphalan and prednisone (for patients over 75 years not qualifying for bone marrow transplantation) – MPV regimen (melphalan: 18 mg/d; prednisone 100 mg; bortezomib: 2.7 mg). The treatment course is illustrated in Fig. 1. The dose of prednisone was reduced to 100 mg due to the patient's age. The bortezomib dose was reduced to 2 mg because of thrombocytopenia (grade III according to CTC AE) which occurred during the first cycle. As a result of the patient developing infectious complications (pneumonia) after the 1st part of the first chemotherapy cycle, melphalan was discontinued. Taking thrombocytopenia into account, starting from the second part of the second cycle, the dose of bortezomib was reduced (to 2 mg). The anticoagulation was changed from acenocumarol to LMWH (low-molecular weight heparin) due to the possibility of faster therapy termination when the platelet count falls below 50 G/l. The day before the last dose of the second cycle, the patient stumbled and fell. This caused a L5 vertebral body fracture and a L4 lamina infraction (earlier radiography did not reveal any osteolytic lesions in this area). After the percutaneous vertebroplasty, chemotherapy was continued. During the 3rd chemotherapy cycle, an episode of bradycardia (HR 30/min) and hypotension (BP 80/40 mmHg) occurred. EKG revealed a 3rd degree atrioventricular block, in Holter EKG two episodes of advanced heart block were found. The pause lasting > 2.5 s did not meet the ACC, AHA and NASPE criteria for pacemaker implantation (> 3 s required). The cardiac rhythm abnormalities were attri-

FIGURE 1.

Treatment course. M – melphalan 18 mg/d for 4 days. 1 – interruption due to fracture and vertebroplasty. 2 – interruption due to arrhythmia. Detailed description in the text.



buted to the β -adrenolytic and digoxin treatment, which were subsequently discontinued. After 2 administrations of bortezomib and a break that followed, when there was no recurrence of arrhythmia, the previous regimen was continued. In further observation, no 3rd degree atrioventricular block appeared.

Due to the increasing psychological abnormalities (deterioration of the logical contact, agitation, delusional thoughts) which were attributed to the glucocorticoid use (steroid psychosis) from the fifth cycle, prednisone dose was reduced from 100 to 50 mg daily. As the symptoms permanently receded, the dose was increased to 60 mg, with good tolerance thereafter.

After the first part of the first cycle of treatment, partial remission (PR) was achieved (79% drop in the paraprotein concentration). At the beginning of the second part of second cycle, very good partial remission (VGPR) was achieved (over 90% reduction). The first treatment interruption (fracture and vertebroplasty) caused a slight increase in the activity of the disease (0.4 g/dl increase in the paraprotein concentration), while the second interruption (arrhythmia) did not have such an effect. After the fourth cycle, 30% of multiple myeloma infiltration in the bone marrow (in histopathology) and partial remission (PR)

in paraprotein concentration (0.58 g/dl) was found (IgM 1029 mg/dl). From the fifth chemotherapy cycle, according to the drug program, bortezomib was administered every 7 days (4 instead of 8 times per 42-day cycle), disease stabilisation (SD) was present. The nadir of the paraprotein concentration was during the fifth cycle – 0.41 g/dl.

After the eighth cycle (12 months from the beginning of the therapy), the patient's condition rapidly deteriorated while he was at home. He was admitted to a nearby hospital with severe pneumonia complicated with ARDS and pulmonary edema. The family informed the attending treating physician about the patient's death by telephone. During the last 3 months no neutropenia (ANC 3.7 G/l at the last bortezomib administration) occurred, and the IgG concentration was only slightly decreased and remained above 500 mg/dl.

DISCUSSION

We describe probably the first Polish case of an elderly patient suffering from IgM multiple myeloma who was treated with bortezomib for one year. This therapy became available in Febru-

ary 2013, when the National Health Fund drug program for multiple myeloma was introduced. Treatment of patients older than 75 who did not qualify for autologous stem cell transplant, started to be reimbursed.

The treatment resulted in a good response with an acceptable toxicity profile. For an elderly patient, controlling the disease course is more important than taking the great risk of getting life-threatening complications, even if to achieve a long-lasting remission. In the described patient, despite the gradual reduction in treatment intensity (melphalan discontinuation, bortezomib and, subsequently, steroid reduction), that goal was achieved. Two interruptions in the treatment occurred. During the first one, paraprotein concentration increased, while the second one did not have such an effect. Despite these limitations in the treatment intensity, the patient achieved VGPR (very good partial remission), and there was no increase in the disease symptoms (renal insufficiency, anemia).

Reports of bortezomib treatment in IgM multiple myeloma are scarce. Japanese patients with IgM multiple myeloma and advanced amyloidosis had a good response to bortezomib as a second-line treatment [5]. Two patients in Austria had a good response to bortezomib with dexamethasone [6]. Three out of four Chinese patients received bortezomib in induction therapy and had a PFS of only 6.0 (2.5–7.0) months with an OS of 17.5 (2.5–27), despite a younger age than the described patient (54–69 years) [7]. Interestingly, three of them had a 11:14 translocation.

Establishing the diagnosis of IgM multiple myeloma can be really difficult and this description testifies to this. Waldenström's macroglobulinemia is classically the most important element in the differential diagnosis. It can be distinguished by lymphadenopathy, splenomegaly and the bone marrow findings: lymphocyte or lymphoplasmacyte (or plasmatic cell) infiltration with expression of CD20 and other B lymphocyte antigens, while CD138 (characteristic for multiple myeloma) is absent. There are no typical multiple myeloma symptoms: osteolysis, hypercalcemia and renal insufficiency. A paraprotein associated with another non-Hodgkin lymphoma (SLL/CLL, MZL, FL, MCL, DLBCL) should also be considered [8].

Some investigators use the presence of 11:14 translocation as a diagnostic criterion, as it was frequently found in this multiple myeloma type (5/8 patients [9]; 7/8 patients, while absent in 17 Waldenström's macroglobulinemia patients [4]). This cytogenetic aberration is frequently associated with cyclin D1 overexpression [9, 10]. It was found in 15–24% of multiple myeloma patients [10] and is associated with a low cytogenetic risk [1]. The described patient did not have translocation 11:14, but immunohistochemical staining for cyclin D1 was positive, which may suggest that a mutation with similar effect occurred but was not associated with karyotype alterations. This patient's case does not support the necessity of t(11:14) and/or osteolytic lesions presence for IgM multiple myeloma diagnosis [4].

On patient's cells CD20, CD56 and CD117 antigens were not expressed, which was described as characteristic for IgM multiple myeloma [9].

In the largest IgM multiple myeloma group, the mean survival of 30 months was similar to the prognosis for other types at that time [4]. It is worth mentioning that the patients were much younger (55–77 years) and often the disease was less advanced. This patient survived for 12 months from the diagnosis and died from severe infection, concordant with the observed high proportion of early deaths caused by sepsis in this patient group [9]. An unusual situation is the impossibility of classifying the disease in the Durie-Salmon scale – caused by the lack of criteria for the IgM paraprotein concentration. The patient did not have any other symptoms qualifying their disease for a grade higher than I, but IgM paraprotein concentration of 5.07 g/dl seems to suggest a higher grade – especially when compared with the cut-off values for IgA (> 3 g/dl for grade II and > 5 g/dl for grade III) and IgG (> 5 g/dl and > 7 g/dl, respectively).

IgM multiple myeloma should be included in the differential diagnosis of IgM paraproteinemia, also when osteolytic lesions and translocation 11:14 are not detected. Bortezomib-based therapy can be effective in elderly patients (also in those suffering from cardiac insufficiency), even when dose reduction is required.

References

1. Dmoszyńska A, Walter-Croneck A, Usnarska-Zubkiewicz L et al. Zalecenia Polskiej Grupy Szpiczakowej dotyczące rozpoznawania i leczenia szpiczaka plazmocytozowego oraz innych dyskracji plazmocytozowych na rok 2013. *Acta Haematol Pol* 2013; 44(1): 43-47.
2. Jurczyszyn A, Skotnicki AB. Szpiczak mnogi – kompleksowa diagnostyka i terapia. Górnicki Wydawnictwo Medyczne, Wrocław 2010.
3. Lech-Marańda E. Makroglobulinemia Waldenströma/chłoniak limfoplazmocytozowy. W: Zalecenia postępowania diagnostyczno-terapeutycznego w nowotworach złośliwych – pp. 2013 rok. Krzakowski M, Warzocha K (ed.). Via Medica, Gdańsk 2013.

4. Schuster SR, Rajkumar SV, Dispenzieri A et al. IgM multiple myeloma: disease definition, prognosis, and differentiation from Waldenstrom's macroglobulinemia. *Am J Hematol* 2010; 85(11): 853-855.
5. Higeta D, Yokohama A, Osaki Y et al. IgM-lambda multiple myeloma presenting with systemic amyloidosis. *Rinsho Ketsueki* 2009; 50(12): 1711-1714.
6. Willenbacher E, Erdel M, Strasser U et al. IgM myeloma: more on a rare entity. *Br J Haematol* 2008; 143(1): 146-148.
7. Fan J, Fu W, Shi H et al. Clinical and laboratory features of four cases with IgM multiple myeloma. *Zhonghua Xue Ye Xue Za Zhi* 2013; 34(4): 341-344.
8. Lin P, Hao S, Handy BC et al. Lymphoid neoplasms associated with IgM paraprotein: a study of 382 patients. *Am J Clin Pathol* 2005; 123(2): 200-205.
9. Feyler S, O'Connor SJM, Rawstron AC et al. IgM myeloma: a rare entity characterized by a CD20-CD56-CD117-immunophenotype and the t(11;14). *Br J Haematol* 2008; 140(5): 547-551.
10. An G, Xu Y, Shi L et al. T(11;14) Multiple Myeloma: a Subtype Associated With Distinct Immunological Features, Immunophenotypic Characteristics But Divergent Outcome. *Leuk Res* 2013; 37(10): 1251-1257.

Correspondence:

Rafał Machowicz, MD, MSc
Department of Hematology, Oncology and Internal Diseases,
Medical University of Warsaw
02-097 Warsaw, Poland, ul. Banacha 1a
e-mail: r.machowicz@wp.pl