

# Interstitial pneumonia during treatment with rituximab

***Dominika Leś, MD, Anna Polakiewicz-Gilowska, MD, PhD, Beata Kaleta, MD, Danuta Starzyczny-Słota, MD, Elżbieta Nowara, MD, PhD***

*Clinical and Experimental Oncology Clinic  
Oncology Centre, Maria Skłodowska-Curie Institute of Oncology, Gliwice  
Head: Elżbieta Nowara, MD, PhD*



Received: 31.10.2014. Accepted: 28.01.2015.

## ABSTRACT

Rituximab (RTX) is a chimeric anti-CD20 antibody. It plays an important role in the treatment of B-cell lymphomas and diseases of autoaggression. RTX-induced lung disease is a rare entity, which should be considered in those patients treated with RTX who present with pulmonary disorders with no clear evidence of infection.

A 37-year-old woman suffering from CD20-positive DLBCL (diffuse large B-cell lymphoma) received two cycles of the R-CHOP (RTX, cyclophosphamide, doxorubicin, vincristine and prednisone) regimen. After the second cycle of immunochemotherapy, symptoms of interstitial pneumonia occurred. Having excluded all the other causes, it was diagnosed as a complication associated with the administration of RTX.

**KEY WORDS:** interstitial pneumonia, complications, rituximab

## Correspondence:

Dominika Leś, MD  
Oncology Centre

Maria Skłodowska-Curie Institute of Oncology  
44-101 Gliwice, ul. Wybrzeże Armii Krajowej 15  
tel.: (+48 32) 278-87-17

e-mail: dles@io.gliwice.pl

## INTRODUCTION

Rituximab (RTX), a chimeric human-murine anti-CD20 antibody, has become part of a standard therapy for patients suffering from CD20-positive B-cell lymphoma. RTX leads to a sudden depletion of regular B lymphocytes in peripheral blood, those expressing the CD20 antigen, while the immunoglobulin concentration in blood serum remains largely unchanged. RTX does not affect the T lymphocytes, thanks to which opportunistic infections are rare in the course of treatment. When combined with different chemotherapy regimens, it may cause higher incidence of neutropenia (grade 3 and 4 neutropenia: 97% for R-CHOP vs 88% for CHOP), which however does not translate into a higher incidence of infectious complications (45% in the R-CHOP group vs 41% in the CHOP one) [1]. In the majority of patients, the RTX-based therapy is safe and well-tolerated. So far, a dozen or so cases of pulmonary complications have been described involving patients receiving RTX as monotherapy, and as part of combined treatment with chemotherapy. The total rate of lung damage which might have been caused by the drug is currently below 3.5%, but mortality remains a high 33% [2]. What can be of significance in the pathogenesis of pulmonary complications in the form of interstitial pneumonia is, *inter alia*, persistent release of cytokines as a result of the destruction of CD20-positive cells, tumour lysis syndrome, activation of the T lymphocytes, and the subsequent capillary and pulmonary alveoli damage, as well as the cross reaction between the tumour and lung antigens.

Interstitial lung diseases constitute a heterogeneous group of conditions, in which the underlying pathological process involves the basement membrane of the pulmonary alveolar epithelium, and the pulmonary capillary endothelium. Clinical presentation of drug-induced lesions in the lung interstitium may be different, ranging from oligosymptomatic cases through severe ones, including the acute respiratory distress syndrome (ARDS), quickly leading to respiratory insufficiency requiring mechanical ventilation. Drug-induced reaction may have the course of pneumonia or another interstitial inflammatory condition, including the non-specific pneumonia or regular interstitial pneumonia, diffuse alveolar haemorrhage, allergic alveolitis and sarcoid-like reactions.

The present paper presents a case of a DLBCL female patient treated with the R-CHOP immunochemotherapy regimen, in which case interstitial pneumonia developed in the course of treatment.

## CASE PRESENTATION

In March 2012, a 37-year-old woman reported the first symptoms, including difficulty swallowing solid foods, hoarse voice, cough, incidents of dyspnoea and hyperhidrosis. Neck ultrasound revealed a left thyroid lobe tumour. Due to the suspicion of a neoplastic process, wedge resection of both thyroid lobes was performed on March 12 2012. Microscopic examination revealed colloid nodular goitre with lymphocytic inflammation. In May, the imaging diagnostics was extended to neck and chest CT with contrast, revealing a 7 × 10 cm neck tumour, descending towards the mediastinum, involving the blood vessels branching out of the aortic arch, modelling the oesophagus, and compressing the trachea and the spherical enlarged lymph nodes in the area. As the diagnostic process to that date did not result in an accurate diagnosis, the imaging and microscopic tests were repeated in June. Fine-needle aspiration biopsy (FNAC) of the thyroid revealed numerous elements of an inflammatory infiltration with the predominance of granulocytes, and follow-up CT demonstrated a stagnation of the neck and mediastinum lesions. On June 14–19 2012, the patient was hospitalized at the Clinical Department of Nuclear Medicine and Oncological Endocrinology of the Gliwice Institute of Oncology, where she was urgently admitted due to dysphagia and dyspnoea caused by tracheal stenosis. Anti-inflammatory treatment and steroid therapy was administered, resulting in the withdrawal of dyspnoea, and a reduction in the symptoms related to dysphagia. Subsequently, on July 26 2012, endobronchial ultrasonography (EBUS) was performed at the Department of Thoracic Surgery of the Specialist Lung Disease Hospital in Zakopane, and the right supraclavicular lymph node was removed. Histopathological examination (HP) revealed a CD20-positive and CD30-positive diffuse large B-cell lymphoma (Ki67 80%). As the patient's resting dyspnoea progressed rapidly, she was hospitalized on August 7–8 2012 at the Municipal Hospital in Gliwice, from where she was transferred to the Clinical and Experimental Oncology Clinic of the Gliwice Institute of Oncology, having presented with symptoms of respiratory distress and in poor general condition.

The physical examination performed upon the patient's admission to the Institute of Oncology revealed a nodular polycyclic infiltration in the neck area, distorting neck profile. The urgently performed neck and chest CT revealed a significant stenosis of the tracheal lumen affected by the infiltration, with the narrowest lumen site, measured at the level of the superior thoracic aperture, totalling around 5 mm. During the patient's hospital stay, only the necessary imaging tests were performed, as the patient's clinical condition excluded a complete diagno-

stic process, including trepanobiopsy (dyspnoea in recumbent position). Due to her general poor condition (ZUBROD 4) and risk of complications, the patient received the 1<sup>st</sup> cycle of chemotherapy on August 9 2012, following the COP regimen (cyclophosphamide, vincristine, prednisone). Following the 1<sup>st</sup> COP cycle, there were moderate symptoms of the tumour lysis syndrome, supraventricular cardiac arrhythmia, lower leg oedema, and electrolyte imbalance (K-3.3 mmol/l), which all receded as a result of adjunctive treatment. At the same time, the patient's clinical condition quickly improved, making it possible for her to initiate treatment in accordance with the R-CHOP regimen. On August 28 2012, the first cycle was administered, combined with primary prophylaxis of febrile neutropenia based on pegfilgrastim. On September 19 2012, the second cycle of R-CHOP chemotherapy was administered, leading to complications such as WHO 3 anaemia, and urinary tract infection. On the 19<sup>th</sup> day following the second cycle of R-CHOP, the patient was admitted to the Clinical and Experimental Oncology Clinic in Gliwice due to a rapidly progressing respiratory insufficiency. Her complaints included the sensation of breathlessness, a 38°C fever, dry cough, and an exacerbation of her general condition. The physical examination performed upon admission revealed crepitations at the base of both lungs, and residual infiltration at the base of the neck (compared to the previous examination there was further and almost complete regression of infiltrative lesions). After the administration of anti-infective and symptomatic treatment (amikacin, cephthazidim, fluconazole, hydrocortisone acetate, and oxygen therapy), the patient's clinical condition improved. The blood and sputum cultures did not enable pathogen specification. Blood chemistry, blood clotting and blood gases tests revealed respiratory alkalosis, leucocyto-

sis 16 000/μl, and a slight increase in CRP, ESR, and D-dimer levels. Chest HRCT (high-resolution computed tomography) revealed intensified diffuse interstitial lesions within the superior lobes of both lungs, possibly reflecting infiltrative-inflammatory lesions, and additionally areas of ground-glass condensations were observed in the middle and inferior right lung. The radiological image suggested the diagnosis of interstitial pneumonia, possibly as an RTX-induced complication (Fig. 1).

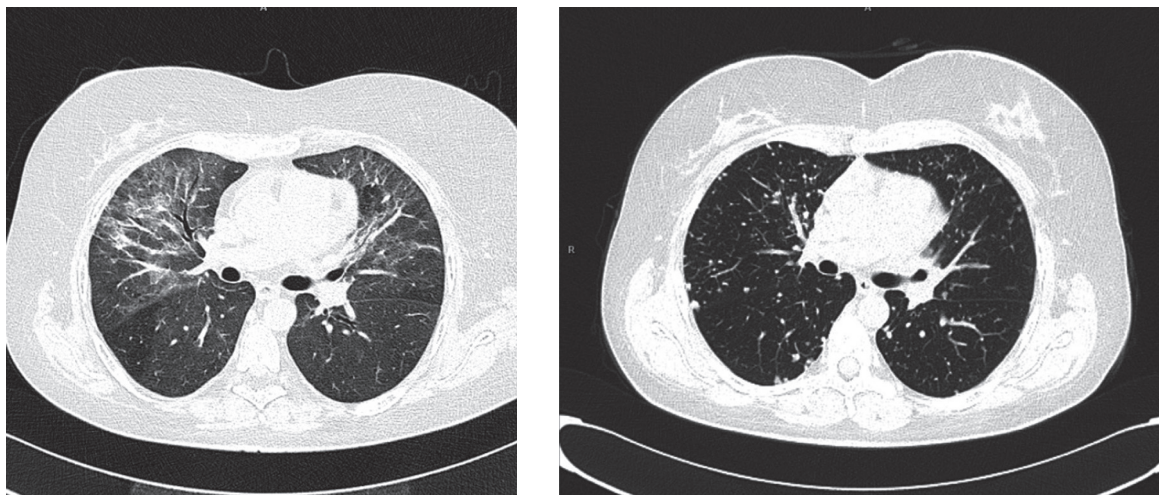
Eventually, the patient was diagnosed with interstitial pneumonia on the basis of the adopted diagnostic criteria for the condition (guidelines of the *American Thoracic Society* and *European Respiratory Society*), including the clinical picture (dyspnoea, dry cough, fever), results of a chest radiology examination (HRCT plays an important role, when it comes to interpreting lung lesions, rendering lung biopsy unnecessary in many cases), pathogen exclusion, and improvement after steroid treatment. Based on the available data from clinical trials, it was established that the most probable cause behind the above mentioned clinical symptoms was RTX [3].

Once the patient's clinical condition improved, her treatment was continued with the exclusion of RTX. She received 5 chemotherapy cycles in total. The treatment was complicated with G4 neutropenia and coagulation disorders. The patient received growth factors, antibiotics, antifungals, antivirals, etamsylate, and fresh frozen plasma in accordance with the standards of adjunctive therapy.

When evaluating treatment effects after the fifth cycle, imaging diagnostics revealed residual neck lesions. PET-CT performed

FIGURE 1.

HRCT of the chest: diffuse interstitial lesions which may reflect infiltrative-inflammatory changes, and areas of ground-glass condensations.



on December 12 2012, revealed radiotracer uptake in thyroid projection, which could reflect residual metabolic activity of the lymphoma. Decision on implementing radical radiotherapy was taken. Since January 24 2013, the patient has been irradiated with X6 and 20 MV photons, applied on the neck and mediastinum lymphatic system, df 1.8 Gy/tumour to 36 Gy/tumour, and subsequently received a *boost* to target the residual lesions revealed in the PET examination – df 1.8 Gy/tumour up to the total dose of 45 Gy/tumour. In the course of radiotherapy, on February 15 2013, complications in the form of pneumonia were observed (chest radiological examination once again revealed maculate and streaky condensations located chiefly within the superior and middle lung lobes). Hence, the patient was hospitalized from February 15 to March 1 2013 at the Clinical Hospital No. 3 in Zabrze, where based on the result of blood culture (*Enterobacter cloacae*), and in accordance with the antibiogram, she was started on imipenem. Within 5 days, clinical improvement was achieved, with partial radiological remission.

Once the treatment had been completed, follow-up PET-CT was performed (15 May 2013), indicating a lack of evident metabolic features of an active lymphoma location. An area of increased radiotracer uptake was revealed within the superior left lung lobe, corresponding with low metabolic activity sarcoidosis. There was also increased radiotracer uptake in the retrosternal antero-superior mediastinum, most probably corresponding with the thymus functional activity. It is worth observing that the location of the above described sarcoid lesions did not correspond with the location of the interstitial lesions. On September 12 2013, follow-up chest CT revealed that the volume of lesions in both lung apices had apparently been reduced, with visible regression of abnormal condensations within the left lung (which size had reached 24 mm before, and only 7 mm during the follow-up chest CT). Otherwise, the chest CT results were similar, showing condensations in the field of the removed thyroid, and in the field of thymus. Presently, the patient's condition is good, and she remains in follow-up. The most recent imaging tests indicate no persistent RTX-induced interstitial lesions, and rule out recurrence of the neoplastic disease. Minor sarcoid-like lesions persist, though. As of today, the patient requires no therapeutic management.

## DISCUSSION

A thorough follow-up of patients undergoing RTX therapy made it possible to define interstitial pneumonia as an RTX-induced complication. The following diagnostic criteria have been elaborated: clinical picture involving dyspnoea, dry cough and

fever, result of the chest radiological examination (with HRCT being of particular diagnostic value), pathogen exclusion, and improvement of the patient's condition upon steroid therapy.

Few cases of pulmonary complications have been described in the literature to date, involving patients suffering from malignant lymphomas, and treated with RTX as monotherapy or in combination with chemotherapy, or involving patients treated for rheumatoid arthritis.

Kanelli et al. described a case of a mantle cell lymphoma patient, in whom bilateral pulmonary infiltration developed 6 days following the first dose of RTX [4]. The patient required mechanical ventilation. Once treatment had been implemented, the patient's condition improved, and the result of a chest radiological examination performed 2 months later was normal.

3 cases of the grade 3 and 4 pulmonary toxicity were described in a phase 2 randomized clinical trial involving the use of RTX with fludarabine in patients suffering from B-cell chronic lymphocytic leukaemia. The cases included isolated interstitial pneumonia, interstitial pneumonia with cardiomyopathy, and obliterative bronchiolitis with organizing pneumonia, which occurred after the second, third, and fifth therapy cycle respectively [5]. Those adverse events were successfully treated in all patients, by means of withdrawing the administration of fludarabine and RTX, and applying short glucocorticosteroid treatment courses. One of the patients received RTX consolidation with no toxicity symptoms later in the course of treatment.

A case of lethal intra-alveolar haemorrhage in the course of R-CHOP therapy in a patient suffering from a non-Hodgkin lymphoma has also been described. In that case, histopathological examination revealed pneumonia, which had most probably been caused by hypersensitivity to RTX [6].

In a phase 2 clinical trial, a group of elderly patients treated with RTX combined with VNCOP-B experienced respiratory insufficiency secondary to bilateral pulmonary infiltration, which resulted in the patients' death [7].

Burton and collaborators described 2 more cases of interstitial pneumonia in patients receiving RTX. In both of the cases, the time of the reaction indicated RTX as a potential cause behind the symptoms. Complete regression of pulmonary symptoms was achieved by means of steroid therapy [8]. Similar cases of reversible interstitial pneumonia have also been described in the course of RTX treatment administered due to idiopathic



thrombocytopenic purpura as well as in a patient treated with the R-CHOP regimen for NHL [9].

## CONCLUSIONS

The presented description of the course of treatment of a DLBCL patient, involving a characteristic clinical picture, i.e. rapidly progressing respiratory insufficiency with fever, and considerable improvement following steroid therapy, as well as a characteristic result of the HRCT examination, made it possible

to diagnose the patient with post-RTX interstitial pneumonia. RTX-induced pulmonary toxicity is a rare complication, but literature findings suggest that the course of interstitial pneumonia may be fulminant, leading to irreversible lung damage or even death. Therefore, all patients presenting respiratory symptoms related to RTX should be thoroughly monitored [10].

## Acknowledgements

Authors report no conflict of interest.

## References

1. Coiffier B, Lepage E, Briere J et al. CHOP chemotherapy plus rituximab compared with CHOP alone in elderly patients with diffuse large-B-cell lymphoma. *N Engl J Med* 2002; 346: 235-42.
2. Cha SI, Choi KJ, Shin KM et al. Risk factors for rituximab-induced interstitial lung diseases in patients with malignant lymphoma. *Respiration* 2013; 85(2): 175.
3. Nieuwenhuizen L, Verzijlbergen FJ, Wiltink E. et al. A possible role of 18F-FDG positron – emission tomography scanning in the early detection of rituximab-induced pneumonitis in patients with non-Hodgkins lymphoma. *Haematologica* 2008; 93: 1267-69.
4. Kanelli S, Ansell SM, Habermann T et al. Rituximab toxicity in patients with peripheral blood malignant B-cell lymphocytosis. *Leukemia and Lymphoma* 2001; 42(6): 1329-37.
5. Byrd JC, Peterson BL, Morrison VA et al. Randomized phase 2 study of fludarabine, with concurrent versus sequential treatment with rituximab in symptomatic, untreated patients with B-cell chronic lymphocytic leukemia: results from Cancer and Leukemia Group B 9712 (CALGB 9712). *Blood* 2003; 101(1): 6-14.
6. Alexandrescu DT, Dutcher JP, O'Boyle K et al. Fatal intra-alveolar hemorrhage after rituximab in a patient with non-Hodgkin lymphoma. *Leukemia and Lymphoma* 2004; 45(11): 2321-25.
7. Hainsworth JD, Litchy S, Lamb MR et al. First-line treatment with brief-duration chemotherapy plus rituximab in elderly patients with intermediate-grade non-Hodgkin's lymphoma: phase II trial. *Clin Lymphoma* 2003; 4: 36-42.
8. Burton C, Kaczmarek R, Jan-Mohamed R et al. Interstitial pneumonitis related to rituximab therapy. *The New England Journal of Medicine* 2003; 348(26): 2690-91.
9. Julien V, Perrin C, Peyrade F et al. A case of acute respiratory failure related to rituximabtherapy. *Rev Mal Respir* 2004; 21: 407-10.
10. Kimby E. Tolerability and safety of rituximab (MabThera). *Cancer Treatment Reviews* 2005; 31(6): 456-73.

### Authors' contributions:

Dominika Leś: 60%; Anna Polakiewicz-Gilowska: 10%;  
Beata Kaleta: 10%; Danuta Starzyczny-Słota: 10%;  
Elżbieta Nowara: 10%