

# Cardiooncological balance in a 75-year-old male with a hepatocellular carcinoma CS IV and a congestive heart failure NYHA III „de novo”

Maciej Żechowicz, MD<sup>1,2</sup>, Konrad Wroński, MD, PhD<sup>1,3</sup>,  
Monika Rucińska MD, PhD<sup>1</sup>

<sup>1</sup> Department of Oncology, Faculty of Medical Sciences,  
University of Warmia and Mazury in Olsztyn, Poland

<sup>2</sup> Department of Internal Medicine, Gastroenterology and Hepatology with the  
Unit of Cardiology, Heart Failure Treatment Centre and Cardiooncology,  
University Hospital in Olsztyn, Poland

<sup>3</sup> Clinical Department of Surgical Oncology, Ministry of Internal Affairs Hospital  
with Warmia and Mazury Oncology Centre in Olsztyn, Poland



Received: 23.02.2015. Accepted: 27.04.2015.

## ABSTRACT

The case reports about a 75-years-old man without a previous medical history, in whom a heart failure NYHA III de novo was diagnosed together with persistent atrial fibrillation and hepatocellular carcinoma in clinical stage IV. Based on echocardiography and computed tomography there were pulmonary hypertension in course of lymphangiosis carcinomatosa as well as diffuse metastases in the abdomen diagnosed. Before the treatment initiation the patient was classified 3 in WHO performance status. After an improvement in control of the rhythm frequency and the heart failure treatment stabilisation with a  $\beta$ -blocker, an ACE-inhibitor, spironolactone and furosemide, the patient's performance status improved to WHO 2. He was further disqualified from surgical procedures due to the advanced clinical stage of the oncological disease. Considering high probability of further cardiotoxic influence of sorafenib on the heart failure despite its satisfactory control, the patient was assigned to palliative chemotherapy with FOLFOX. Parallel he was strictly followed up cardiologically in an outpatient clinic what certainly supported the oncological treatment. The patient survived 32 weeks from the first hospitalization and the progression free survival was 12 weeks from the chemotherapy initiation.

**KEY WORDS:** cardiooncology, hepatocellular carcinoma (HCC), heart failure

### Correspondence:

Maciej Żechowicz, MD  
Department of Oncology, Faculty of Medical Sciences,  
University of Warmia and Mazury in Olsztyn  
10-228 Olsztyn, ul. Wojska Polskiego 37  
e-mail: m.zechowicz@gmail.com

## INTRODUCTION

This paper discusses interdisciplinary decisions regarding diagnostic and therapeutic procedures in the management of cancer and heart disease in a 75-year old patient diagnosed with de novo NYHA class III heart failure, persistent atrial fibrillation and bilateral pneumonia, and suspected of hepatocellular carcinoma (HCC) during his stay in hospital in the department of internal medicine.

## CASE PRESENTATION

A 75-year old male patient, with no significant pre-existing conditions, was admitted to hospital due to fatigue, dyspnoea and oedema in calves, all of which had been increasing for several weeks. Based on a physical exam, the following was established: the patient's WHO performance status was 3 and he had an irregular heart rate of 100–120 per minute, a tendency towards hypotension, signs of bilateral pulmonary haemostasis, oedema in calves and mild ascites. A chest X-ray image showed parenchymal densities (Fig. 1). An abdominal ultrasound scan revealed a heterogeneous lesion measuring over 7 cm in segment IV of the liver and a number of smaller hepatic lesions measuring between 2 cm and 3 cm. Based on a computer tomography (CT) scan, pathological lesions were identified in the liver suggestive of HCC (the largest one measuring approx. 7.8 cm), and signs of cirrhotic liver and ascites were observed (Fig. 2). Laboratory tests showed a normal level of alpha-fetoprotein, NT-pro-BNP > 2500 pg/ml, D-dimer > 2700 ng/ml, ESR of 65 mm/h, hypoalbuminemia and a positive result for anti-HCV antibodies. An ECG identified atrial fibrillation with QRS 100–120 per minute and a right bundle branch block (Fig. 3). The patient was diagnosed with atrial fibrillation with a rapid ventricular response, de novo NYHA class III heart failure and pneumonia, and suspected of hepatocellular carcinoma associated with a hepatitis C virus (HCV) infection. The patient was started on an empiric antibiotic therapy based on amoxicillin and clavulanic acid. In order to manage the heart failure, carvedilol, ramipril and furosemide were initiated. In addition, spironolactone was given to the patient to manage the co-existing liver failure (class B according to the Child-Pugh score). The decision was taken to initiate an anticoagulant therapy based on enoxaparin at 1.5 mg per kilogram of body weight. The therapy improved the patient's overall health status, helped to control the heart rate and reduced dyspnoea and oedema in calves. Echocardiography showed signs of pulmonary hypertension with right ventricular systolic pressure (RVSP) at 65–70 mmHg, a dilated and non-reactive inferior vena cava, a slightly dilated pulmonary trunk (27 mm) and both pulmonary arteries, boundary PAcCT at

FIGURE 1.

Bilateral parenchymal densities in chest X-ray.

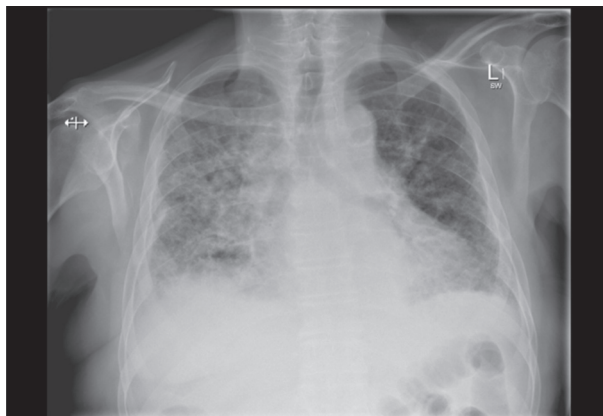


FIGURE 2.

Suspected HCC associated with liver cirrhosis and co-existing ascites shown by abdominal CT scan.

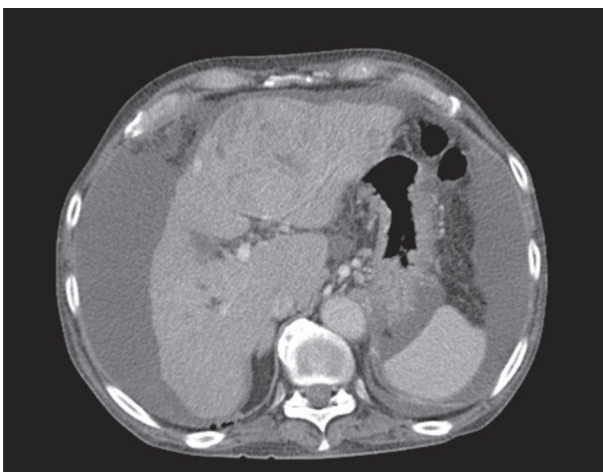
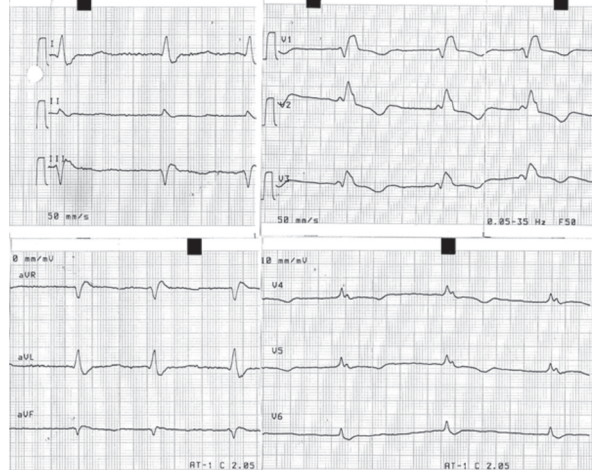


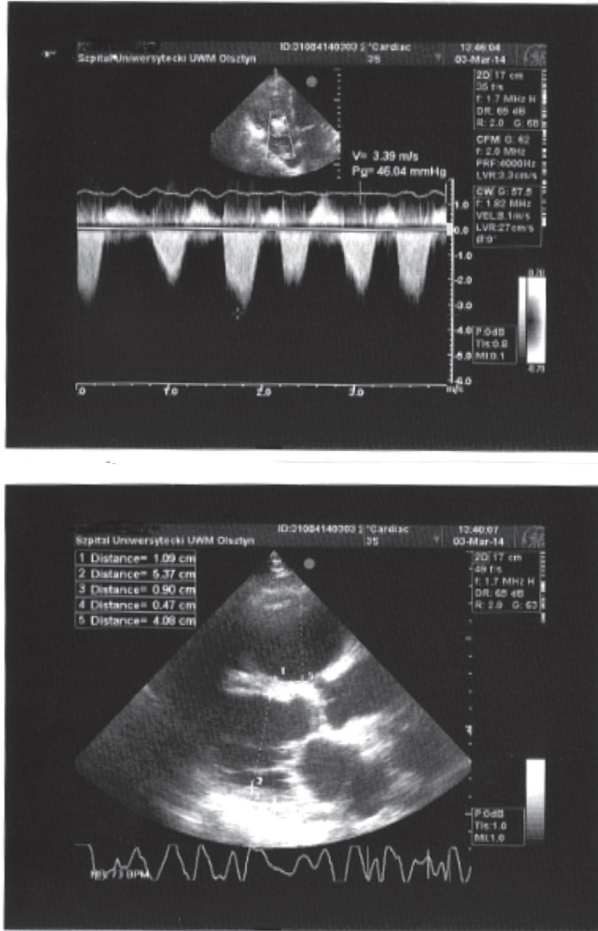
FIGURE 3.

Atrial fibrillation and right bundle branch block shown in ECG.



82 ms, a retained right ventricular systolic function with TAPSE of 17 mm, a left ventricular systolic function without abnormalities and LVEF of 60% (measured by the Simpson rule) in atrial fibrillation, as well as valves without changes of haemodynamic relevance (Fig. 4). Another CT scan of the chest was taken which helped to rule out, with high probability, pulmonary embolism and the signs of pneumonia which has been identified

FIGURE 4.  
Signs of right ventricular overload in echocardiography.



earlier in the chest X-ray. However, lymphangiosis carcinomatosa were found which, along with advanced congestive heart failure, were considered as the most likely cause of secondary pulmonary hypertension. On account of the advanced stage of hepatic lesions and the presence of lymphangiosis carcinomatosa, the patient was not considered eligible for curative liver surgery. A CT-guided fine-needle aspiration biopsy of the hepatic tumour was performed. The histopathological exam confirmed a diagnosis of hepatocellular carcinoma. The tumour was assessed as stage T3N1M1 according to the TNM classification and CS class IV. Given the significant improvement in the patient's overall performance following treatment of heart failure,

and his clinical stabilisation, the stage of HCC was re-assessed as C according to the Barcelona Clinic Liver Cancer (BCLC) staging, taking into account the improved overall performance (WHO status 2 and Child-Turcotte-Pugh score B). The patient was not considered eligible for treatment with sorafenib due to his serious heart problem and a risk of complications including cardiotoxicity. The decision was taken to offer the patient FOLFOX 4 palliative chemotherapy. The patient received 4 courses of chemotherapy in prescribed doses and showed good tolerance. He was closely monitored by an internal medicine specialist and a cardiologist who managed the drug therapy which targeted the patient's co-existing heart failure and atrial fibrillation. The chemotherapy had to be stopped owing to progression of the disease (severe ascites and advancing cachexia) and deterioration of clinical performance (WHO status 4). The patient died 32 weeks after the first admission to hospital due to cachexia and circulatory-respiratory failure. The progression-free survival was 12 weeks from the initiation of chemotherapy.

## DISCUSSION

Hepatocellular carcinoma accounts for over 80% of primary liver tumours. It is the 5<sup>th</sup> most frequent malign tumour worldwide, with the majority of cases occurring in Asia and Africa. In Poland, approx. 1,400 people develop HCC each year (according to 2010 data) [1]. Symptoms of hepatocellular carcinoma are non-specific, they increase slowly and resemble those of liver cirrhosis. The treatment of choice is surgery which is the only method that can cure the disease. Tumour resection is performed on patients who are at an early stage of the disease, have a normal liver function and show no symptoms of portal hypertension. Patients who are not eligible for surgery receive systemic treatment whose efficacy is very limited. It has been reported that doxorubicin, which was widely used until recently, does not have any effect on patient survival. Multiple-drug chemotherapy, despite eliciting a slightly higher response rate, does not improve the prognosis, either [11]. Sorafenib turned out to be the only drug which slightly improves survival of HCC patients. However, its use is associated with cardiotoxicity whose severity and extent has not been yet fully researched [7, 13]. The prognosis for inoperable HCC is poor, with 5-year survival occurring in only up to 10% of cases and median survival of merely ca. 12–16 weeks [2, 3]. Similarly, prognosis for patients with advanced heart failure is poor, and only approx. 50% of them survive 24 months [4]. Currently, it may be assumed that a patient with a heart failure, diagnosed and treated, is at a higher risk of developing cancer in the future, with the risk increasing along with the duration of heart failure treatment [15].

In the case at hand, two diseases with poor prognosis were diagnosed simultaneously and their symptoms to some extent overlapped and concurrently exacerbated (the patient's oedema in calves and ascites could have been induced both by cirrhotic liver failure and congestive heart failure), which made the diagnosis and therapeutic decisions more difficult. The patient had to receive treatment for his failing heart as the first line of treatment. Following treatment with a  $\beta$ -blocker, ACE-inhibitor (ACE-I), a loop diuretic and an aldosterone antagonist, the patient's clinical status and performance improved, which enabled further diagnostic and therapeutic procedures (including diagnosis of metastatic disease). The patient was scheduled for a FOLFOX palliative chemotherapy regimen. On account of the high risk of adverse events, in particular cardiotoxicity, the patient was not given sorafenib despite its demonstrated efficacy in HCC, which reportedly achieves an improvement in relative survival by up to 44% [14] as compared to cytotoxic treatment based on doxorubicin or cisplatin (positive response to therapy < 10%) [11]. 10% of patients treated with sorafenib experience a decrease in ejection fraction, and either develop heart failure symptoms or their existing symptoms are exacerbated [7, 13]. Selection of the safest possible anticoagulant agent to manage atrial fibrillation proved difficult given that cancer patients are not recommended to receive novel oral anticoagulants (such as rivaroxaban and dabigatran). In addition, it was difficult to maintain a therapeutic INR level during warfarin therapy due to co-existence of a liver disease with malignant tumours [8, 9]. Eventually, the patient was given therapeutic doses of enoxaparin and did not suffer haemorrhagic complications or thromboembolic events. Despite the poor prognosis at the outset and no proof that the systemic treatment regimen improves survival [10, 11], the patient survived a total of 32 weeks after the first hospital admission in a quite good clinical status and mental condition. It seems that the  $\beta$ -blocker and ACE-I, used not only to manage the heart failure but also to protect the heart from impact of the cancer therapy [17], had a beneficial effect on survival despite the patient's tendency towards hypotension and advancing cancer cachexia. Further contributing factors included regular monitoring of symptoms and quick decision

making regarding diagnostic and therapeutic procedures which mitigated the risk of having to admit the patient to hospital again on account of exacerbated underlying diseases [12]. The patient's total survival (8 months) was slightly better than that of patients with advanced liver failure (CTP score C) and poor clinical performance (WHO status > 2) attributable to presence and progression of hepatic tumour who receive symptomatic treatment only, which is under 6 months [5, 11]. A randomised multi-centre study conducted in Asia to evaluate the FOLFOX-4 regimen and doxorubicin, demonstrated that patients with inoperable HCC experienced an average survival of 6.4 and 4.97 months, respectively [16]. However, in the case of the HCC patient from this case report, one also needs to take into account the poor prognosis associated with advanced congestive heart failure and manifestations of pulmonary hypertension. The decision to initiate treatment of heart failure in combination with cancer therapy appears to have been right because the patient managed to survive in a satisfactory clinical condition for a longer period than projected. It is not possible to confirm efficacy of the treatment by means of clinical trials as the number of homogenous patients is not sufficient. The efficacy of the therapy may only be verified through individual case reports.

## CONCLUSION

Co-existence of serious heart diseases worsens the prognosis for cancer patients. On the other hand, development of cancer in a patient with heart failure shortens that patient's projected survival. However, the right choice of causal therapy, including anticancer treatment, combined with monitoring of the therapy impact on the heart help to improve survival relative to what can be achieved by symptomatic treatment only. It is necessary to discuss the treatment options, their efficacy and possible toxicity with the patient and to take joint decisions about diagnostic and therapeutic procedures together with the patient.

## Acknowledgements

Authors report no conflict of interest.

## References

1. Wojciechowska U, Didkowska J. Zachorowania i zgony na nowotwory złośliwe w Polsce. Krajowy Rejestr Nowotworów, Centrum Onkologii – Instytut im. Marii Skłodowskiej-Curie [online: <http://onkologia.org.pl/raporty/> – dostęp z dnia 06/01/2015].
2. Thomas MB. Hepatocellular carcinoma: the need for progress. *J Clin Oncol* 2005; 23(13): 2892-2899.
3. Pons F, Varela M, Llovet JM. Staging systems in hepatocellular carcinoma. *HPB* 2005; 7: 35-41.

4. Stewart S, MacIntyre K, Hole DJ et al. More ‘malignant’ than cancer? Five-year survival following a first admission for heart failure. *Eur J Heart Fail* 2001; 3(3): 315-322.
5. Bruix J, Sherman M. Practice Guidelines Committee, American Association for the Study of Liver Diseases: Management of hepatocellular carcinoma. *Hepatology* 2005; 42: 1208-1233.
6. Llovet JM, Brú C, Bruix J. Prognosis of hepatocellular carcinoma: the BCLC staging classification. *Semin Liver Dis* 1999; 19: 329-338.
7. Sohn W, Paik YH, Cho JY et al. Sorafenib therapy for hepatocellular carcinoma with extrahepatic spread: treatment outcome and prognostic factors. *J Hepatol* 2014 Dec 13. pii: S0168-8278(14)00927-1 [doi: 10.1016/j.jhep.2014.12.009].
8. Rahme E, Feugère G, Sirois C et al. Anticoagulant use in patients with cancer associated venous thromboembolism: a retrospective cohort study. *Thromb Res* 2013; 131(3): 210-217.
9. Osterspey A, Krome A. Role of the new oral anticoagulants in comparison to vitamin K antagonists in practice. *Herz* 2012; 37(4): 384-392.
10. Louafi S, Boige V, Ducreux M et al. Gemcitabine plus oxaliplatin (GEMOX) in patients with advanced hepatocellular carcinoma (HCC): results of a phase II study. *Cancer* 2007; 109: 1384-1390.
11. Verslype C, Rosmorduc O, Rougier P; ESMO Guidelines Working Group: Hepatocellular carcinoma: ESMO–ESDO Clinical Practice Guidelines for diagnosis, treatment and follow-up. *Ann Oncol* 2012; 23(supl. 7): vii41-vii48.
12. Del Carlo CH, Cardoso JN, Ochia ME et al. Temporal Variation in the Prognosis and Treatment of Advanced Heart Failure – Before and After 2000. *Arquivos Brasileiros de Cardiologia* 2014; 102(5): 495-504.
13. Eschenhagen T, Force T, Ewer M et al. Cardiovascular side effects of cancer therapies: a position statement from the Heart Failure Association of the European Society of Cardiology. *Eur J Heart Fail* 2011; 13: 1-10.
14. Llovet JM, Ricci S, Mazzaferro V et al. SHARP Investigators Study Group: Sorafenib in advanced hepatocellular carcinoma. *N Engl J Med* 2008; 359: 378-390.
15. Hasin T, Gerber Y, McNallan SM et al. Patients with heart failure have an increased risk of incident cancer. *J Am Coll Cardiol* 2013; 62: 881-886.
16. Qin S, Bai Y, Lim HY et al. Randomized, multicenter, open-label study of oxaliplatin plus fluorouracil/leucovorin versus doxorubicin as palliative chemotherapy in patients with advanced hepatocellular carcinoma from Asia. *Clin Oncol* 2013; 31(28): 3501-3508.
17. Opolski G, Krzakowski M, Szmit S et al. Recommendations of National Team of Cardiologic and Oncologic Supervision on cardiologic safety of patients with breast cancer. The prevention and treatment of cardiovascular complications in breast cancer. The Task Force of National Consultants in Cardiology and Clinical Oncology for the elaboration of recommendations of cardiologic proceeding with patients with breast cancer. *Kardiol Pol* 2011; 69(5): 520-530.

**Authors’ contributions:**

Maciej Żechowicz: research/planning, data collection, analysis of the data/statistics, interpretation, writing the manuscript, references collection and analysis

Konrad Wroński: data collection and analysis, statistics

Monika Rucińska: data analysis/statistics, data interpretation, writing the manuscript