

Case report

Cardiac complications during DLBCL treatment using R-CHOP

Barbara Sosnowska-Pasiarska¹, Paweł Zgódka², Paulina Steckiewicz², Marcin Pasiarski^{2, 3}

¹ Department of Oncocardiology, Holy Cross Cancer Center, Kielce

² Department of Hematology, Immunology and Bone Marrow Transplantation, Holy Cross Cancer Center, Kielce

³ The Faculty of Medicine and Health Sciences, The Jan Kochanowski University, Kielce

Correspondence:

Barbara Sosnowska-Pasiarska
Department of Oncocardiology,
Holy Cross Cancer Center
25-734 Kielce, Artwińskiego 3
e-mail: barbara.pasiarska@onkol.kielce.pl

Received:

4.03.2019

Accepted:

8.03.2019

DOI: 10.24292/01.0R.119080319

Copyright © Medical Education.

All rights reserved.

ABSTRACT

Diffuse large B-cell lymphoma (DLBCL) is the most frequent of non-Hodgkin's lymphomas in the world. Immunochemotherapy with rituximab, doxorubicin, cyclophosphamide, vincristine, and prednisone (R-CHOP) is the first-line treatment in this disease. Rituximab is a chimeric murine-human monoclonal anti-CD20 antibody, which binds specifically with CD20 receptor located on majority of mature B-cell lymphocytes. We are presenting the case of sudden cardiac arrest with ventricular fibrillation after intravenous injection of rituximab in a patient with DLBCL type NGC.

Key words: DLBCL, rituximab, sudden cardiac arrest, implantable cardioverter-defibrillator

BACKGROUND

Diffuse large B-cell lymphoma (DLBCL) is the most frequent of non-Hodgkin's lymphomas in the world, presenting about 30–40% of all lymphomas. The main type of DLBCL is DLBCL not otherwise specified (DLBCL-NOS). There is very heterogenic group of DLBCL with different clinical course of the disease. Many subtypes of DLBCL are identified in the base of gene expression profiling, the most frequent of them are germinal center B-cell-like DLBCL (GCB DLBCL) and activated B-cell-like DLBCL (ABC DLBCL). Non-germinal center DLBCL (DLBCL-NGL) is diagnosed frequently as well [1].

The first symptoms of the disease are often rapidly magnifying lymph nodes of one or more nodal areas. Not seldom lymphomas can develop outside the lymph nodes, e.g. stomach, vertebral bodies or the central nervous system. DLBCL is characterized by aggressive course, despite this 5-year survival after the first-line therapy reaches about 60–70% of patients, and progression free survival time (PFS) is noted in 50–60% of patients [1].

International Prognostic Index (IPI) is used to risk stratification in DLBCL patients, which evaluates: age, stage of the disease (according to the Ann Arbor classification), number of extranodal locations, functional status assessed by the Eastern Cooperative Oncology Group (ECOG) scale, serum lactate dehydrogenase (LDH) activity [2].

Immunotherapy with rituximab, doxorubicin, cyclophosphamide, vincristine, and prednisone (R-CHOP) administered every 14–21 days is the first-line treatment in this disease. In case of the first-line treatment failure rituximab and combination of other chemotherapy are given for the next step of an oncologic therapy [3, 4]. Also experimental drugs are accessible in clinical trials.

Rituximab is a chimeric murine-human monoclonal anti-CD20 antibody, which binds specifically with CD20 receptor located on majority of mature B-cell lymphocytes. The medicine is used in monotherapy or in combination with other chemotherapy in onco-hematology, among others in B-cell lymphomas. The most common adverse event of rituximab is immediate anaphylactic reaction, but post-marketing reports have been citing increased rates of rare but serious complications such as hepatitis type B reactivation, bowel perforation, progressive multifocal encephalopathy and cardiac arrhythmias and ischemia [5].

We are presenting the case of the patient with DLBCL-NGC, in which after intravenous therapy with rituximab during the first-

-line treatment sudden cardiac arrest with ventricular fibrillation was observed.

CASE STUDY

64-year-old male with history of diabetes mellitus type 2, visceral obesity and gouty arthritis, was admitted to Department of Hematology, Immunology and Bone Marrow Transplantation in October 2015 with the diagnosis of DLBCL-NGC for the treatment of the disease. During the two months preceding admission to hospital, the patient observed enlarging cervical lymph nodes and general symptoms accompanying hematological disease in the form of night sweats, weight loss and febrile states, but without symptoms of pectoris angina, palpitations or syncope. The patient's family history was not burdened with hematological or cardiac diseases. Diagnosis of neoplastic disease was based on histopathological examination of the cervical lymph node. Initially in PET/CT examination, changes of active proliferative process including tonsil pharyngeum, cervical node conglomerates, mucous membrane of the left maxillary sinus, upper right nasal turbinates, lower right tracheal lymph nodes and left tracheal-bronchial lymph nodes, left lung hilus, stomach, mesenteric nodes, aortic nodes, external and internal iliac nodes, left-sided inguinal lymph nodes and testes were observed. There was no infiltration of lymphoma in the bone marrow in histopathological examination. There was also no infiltration in central nervous system in MRI. Stage the severity of the underlying disease was set to IV according to Ann Arbor/Lugano.

When he was admitted to the hospital, the general condition was defined as moderately severe, the patient was feverish up to 38.4°C, the blood cultures for bacteriological tests were negative. The results of laboratory tests are presented in table 1.

TABLE 1.

The results of selected laboratory tests before treatment, during the cardiac arrest and during VT/VF interrupted by ICD intervention.

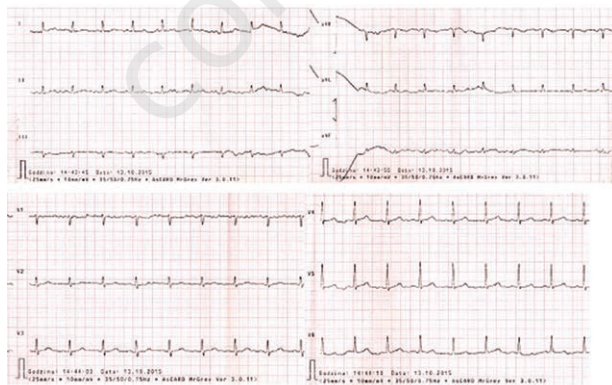
	admission	SCA	VT/VF terminated by ICD
Hb [g/dl]	8.3	9.7	9.0
Ht [%]	25.8	29.7	27.1
WBC [G/l]	4.22	4.05	5.53
ANC [G/l]	2.47	3.16	3.89
PLT [G/l]	239	155	8
Sodium [mmol/l] (136–145)	125.4	134.9	142.3
Potassium [mmol/l] (3.5–5.1)	5.37	4.04	3.89

Total calcium [mmo/l] (2,1–2,6)	2.5	2.19	1.96
Magnesium [mg/dl] (1,6–2,6)			2.22
Crea [mg/dl]	1.35	0.58	1.87
eGFR [ml/min/1,73 m ²] ⁺	55.5	108.5	36.9
ALT [U/l] (0–41)	34	31	6
CRP [mg/l] (0–5)	107.54	39.60	122.73
PCT [ng/ml]	0.81	1.11	0.34
cTnI [μg/l]		0.06	cTnI hs [ng/l] 64..73..75..68..68

DLBCL – diffuse large B-cell lymphoma; SCA – sudden cardiac arrest; ICD – implantable cardioverter-defibrillator; VT/VF – ventricular tachycardia/ventricular fibrillation; Hb – hemoglobin; Ht – hematocrit; WBC – leukocytes; ANC – neutrophils; PLT – platelets; Crea – creatinine; eGFR – estimated glomerular filtration rate, + obtained from Chronic Kidney Disease Epidemiology Collaboration (CKD-EPI) formula; ALT – alanine aminotransferase; CRP – C-reactive protein; PCT – procalcitonin; cTnI – cardiac troponin I; hs-cTnI – high-sensitivity cardiac troponin I.

The patient was hydrated and enrolled with empiric antibiotic therapy (ceftazidime, ciprofloxacin). As a result, clinical improvement and reduction of inflammatory parameters were gradually achieved. Before the qualification for chemotherapy the echocardiographic examination was performed and no pathology was found, the ejection fraction of the left ventricle was normal. Electrocardiography also did not reveal any abnormalities (fig. 1).

FIGURE 1.
ECG before starting treatment. Sinus rhythm 88 bpm. QT 360 ms, QTc 436 ms (Bazett's formula), QTc 409 ms (Fridericia's formula).



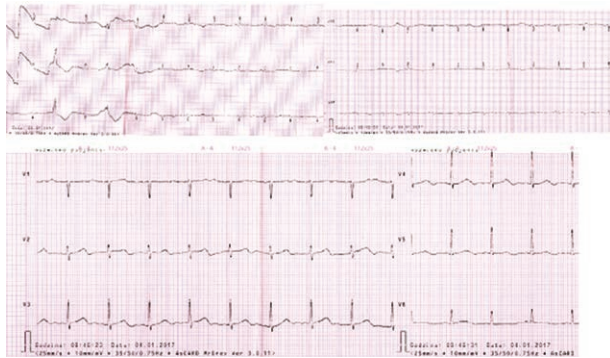
The patient was qualified for chemotherapy according to the R-CHOP regimen with intrathecal prophylaxis with methotrexate 15 mg and dexamethasone 4 mg. The first intravenous administration of rituximab in a dose of 100 mg patient was well-tolerated and no complications were observed. The next day after the consecutive rituximab dose (565.9 mg), the patient was febrile to 38.1°C, and laboratory tests showed an increase in procalcitonin to 2.85 ng/ml, therefore, chemotherapy was not started (doxorubicin, cyclophosphamide, vincristine,

prednisone) and antibiotic therapy was modified (meropenem, amikacin). On the third day after administration of rituximab, the patient had a sudden cardiac arrest (SCA) in the ventricular fibrillation mechanism (VF). The patient was resuscitated (2 × defibrillation 360 J, adrenaline total 3 mg) and the sinus rhythm was recovered at a frequency of 120 /min. During ECG monitoring, ventricular tachycardia (VT) 170/min was observed, which resolved after intravenous administration of amiodarone. The patient received a total dose of amiodarone 900 mg. Immediately after resuscitation and resolution of VT in the electrocardiogram ST segment depression in V3–V6 leads was observed and the echocardiography revealed hypokinesia of the apical segment of the interventricular septum and of the anterior wall with a left ventricular ejection fraction of 50%. Coronary angiography did not reveal atherosclerotic lesions in coronary arteries. Non-sustained ventricular tachycardias (ns-VTs) were still recorded in ECG monitoring and the QTc interval was 530 ms. Therefore, it was decided to implant the cardioverter-defibrillator system (ICD) as part of the secondary prevention of sudden cardiac death. The patient received bisoprolol 7.5 mg/24 h as a pharmacological treatment.

Control echocardiographic examination was performed after 4 months and it did not show a reduction of the left ventricle ejection fraction, no prolongation of the QTc interval was observed in the ECG. Treatment of neoplastic disease was continued and the patient received a total of 4 prophylactic intrathecal injections of methotrexate and 4 R-COP courses (due to cardiac complications [SCA], initially the administration of doxorubicin was abandoned). Due to the uncomplicated course of previous chemotherapy (preserved left ventricular ejection fraction, without arrhythmias, without ICD intervention), after 4 courses of previous treatment due to the progression of lymphoma, it was decided to intensify the treatment and the R-COMP regimen with liposomal doxorubicin was included. There were no cardiac complications of the implemented treatment. Since the features of lymphoma progression were still observed in the PET/CT examination, the decision was again made to intensify chemotherapy, this time based on the R-DHAP regimen (rituximab, cytosine arabinoside, cisplatin, dexamethasone). During the third course of R-DHAP on the 20th day after switching chemotherapy, the patient was suffered from 3 times ICD's intervention. At this time, episodes of ventricular fibrillation and ventricular tachycardia, interrupted by ICD, were observed on the external ECG monitor. In addition, there were numerous single premature ventricular extrasystoles and ventricular bigeminy episodes (fig. 2).

FIGURE 2.

ECG in the ICD intervention day. Sinus rhythm 78 bpm. QT 480 ms, QTc 547 ms (Bazett's formula), QTc 524 ms (Fridericia's formula). Single premature ventricular extrasystoles.



Then the patient was treated for bronchitis and was feverish. He received an antibiotics (piperacillin and tazobactam). The results of laboratory tests are presented in table 1.

Then pharmacotherapy was modified and the dose of bisoprolol was increased up to 10 mg/24 h and attached amlodipine 5 mg/24 h. No other ICD discharges were observed.

Unfortunately, the used chemotherapy did not stop the progression of the disease and in a subsequent PET/CT scan, new infiltrative lymphoma changes were found. Due to the progression of the disease and resistance to the applied therapy, as well as due to significant complications after the patient's previous therapy, he was qualified for palliative treatment with bendamustine monotherapy. He got the first course, but he did not decide on the next one. From information obtained from the family, he died in a district hospital due to infectious complications.

DISCUSSION

Rituximab is a monoclonal antibody widely used in medicine. It is a relatively safe drug, and the most common complications associated with its administration relate to hypersensitivity reactions and usually occur during the first injection. In the described patient ventricular cardiac arrhythmias in the form of sudden cardiac arrest in the mechanism of ventricular fibrillation were observed on the third day after rituximab intravenous administration. The literature provides descriptions of cases in which VT or VF occurred during an intravenous infusion of this drug. In one of the papers the prevalence of rituximab cardiotoxicity in the form of various types of arrhythmias (bradycardia, atrial fibrillation, tachycardia, premature ventricular beats) was estimated at 8% [6]. The best therapeutic option for patients with DLBCL is the use of a regimen combining chemotherapy with immunotherapy using rituximab [3, 4]. Despite the occurrence of a serious cardiac complication in the presented case probably associated

with the use of rituximab, further cancer therapy with the use of this drug was possible due to ICD implantation.

In the presented patient there was no chest pain, but it should be remembered that he had been diagnosed with type 2 diabetes mellitus and therefore he could suffer from the autonomic neuropathy. Immediately after the VT resolution, ST segment depression to 1 mm in V3–V6 leads in the ECG was observed, and the echocardiography showed segmental contractility disturbances. The observed cardiac arrhythmias were probably caused by coronary artery vasospasm.

Coronary artery vasospasm may be caused by vascular smooth muscle hyperreactivity, metabolism dysfunction and altered autonomic function, endothelial dysfunction, which is observed in the course of diabetes mellitus. Subclinical asymptomatic myocardial injury associated with endothelial dysfunction in the course of diabetes mellitus may be responsible for the described clinical manifestation.

In the literature, we also found case reports when after intravenous infusion of rituximab the changes observed in the ECG (ST segment elevation, ST segment depression, ventricular arrhythmias) were consistent with coronary artery spasm [7, 8]. Intracoronary nitroglycerin use during angiography of coronary arteries caused regression of angina pain and ECG changes [9]. Thanks to the progress that has been made in cardiology in the field of electrotherapy, effective treatment is also possible in hematology. ICD implantation in secondary prevention of sudden cardiac death after ventricular fibrillation due to coronary artery spasm or in a patient with primary cardiac lymphoma, whose the first symptom is ventricular tachycardia, gives the chance to control the disease with the use of anticancer drugs [10–12]. Interestingly, the occurrence of tako-tsubo syndrome following intravenous rituximab administration has also been documented [13]. VT was also reported during the infusion of rituximab in a burdened with respiratory diseases patient [14].

In the presented patient, VF occurred several days after administration of the drug, so it can not be unequivocally stated that rituximab injection contributed directly to the occurrence of arrhythmia, but it can not be ruled out. It can be assumed that the appearance of ventricular arrhythmias occurred due to the coexistence of many factors: administration of rituximab, vascular endothelial dysfunction observed in patients with diabetes mellitus, stress and associated increased adrenergic tone, as well as factors that promote the prolongation of the QT interval (including fever, electrolyte disturbances, antibiotic therapy). It should also be noted that the CD20 antigen can act as

a calcium channel, which can also be associated with observed cardiac complications [15, 16].

CONCLUSION

It should be emphasized that rituximab is a drug that is fairly well-tolerated, effective and has a recognized place in the treatment of lymphomas. Based on the described case, the relationship between VF and the use of rituximab can not be unambiguously confirmed, but regardless of its cause by ICD implantation continued therapy with the anti-CD20 antibody was possible. In the assessment of the risk of potentially malignant arrhythmias, drug interactions, malnutrition, electrolyte disturbances and multi-organ dysfunction must be considered. It should be noted that case reports in the literature suggest

that the ECG monitoring during the infusion of rituximab will be necessary every time. As we improve the techniques of monitoring patients in the future, it may turn out that more and more often we will know the causes of chest pain, fainting or syncope, currently referred to as idiopathic or reflex.

Electrocardiographic monitoring of the patient during the administration of rituximab is always justified, regardless of whether he is burdened with cardiovascular disease or not, because VT is a serious complication and can lead to death. The occurrence of ventricular arrhythmia results from the coincidence of many factors. The pathophysiological mechanism of ventricular arrhythmias development during treatment with rituximab remains unclear.

References

1. Li S, Young KH, Mederidos LJ. Diffuse large B-cell lymphoma. *Pathology* 2018; 50: 74-87.
2. Ziepert M, Hasenclever D, Kuhnt E et al. Standard International Prognostic Index Remains a Valid Predictor of Outcome for Patients With Aggressive CD20 B-Cell Lymphoma in the Rituximab Era. *J Clin Oncol* 2010; 28: 14.
3. Pfreundschuh M. How I treat elderly patients with diffuse large B-cell lymphoma. *Blood* 2010; 9: 116.
4. Martelli M, Ferreri AJM, Agostinelli C et al. Diffuse large B-cell lymphoma. *Crit Rev Oncol Hematol* 2013; 87: 146-171.
5. Seruga B, Sterling L, Wang L, Tannock IF. Reporting of serious adverse drug reactions of targeted anticancer agents in pivotal phase III clinical trials. *J Clin Oncol* 2011; 29: 174-185.
6. Foran JM, Rohatiner AZS, Cunningham D et al. European phase II study of rituximab (chimeric anti-CD20 monoclonal antibody) for patients with newly diagnosed mantle-cell lymphoma and previously treated mantle-cell lymphoma, immunocytoma, and small B-cell lymphocytic lymphoma. *J Clin Oncol* 2000; 18: 317-324.
7. Poterucha JT, Westberg M, Nerheim P, Lovell JP. Rituximab-Induced Polymorphic Ventricular Tachycardia. *Tex Heart Inst J* 2010; 37(2): 218-220.
8. Lee L, Kukreti V. Rituximab-Induced Coronary Vasospasm. *Case Rep Hematol* 2012. Article ID 984986. DOI:10.1155/2012/984986.
9. Ke C, Khosla A, Davis MK et al. A Case of Coronary Vasospasm after Repeat Rituximab Infusion. *Case Rep Cardiol* 2015. Article ID 523149. <http://dx.doi.org/10.1155/2015/523149>.
10. Naqvi SY, Hanley A, Crowley J. Ventricular fibrillation due to coronary vasospasm. *BMJ Case Rep* 2014. DOI:10.1136/bcr-2013-203253.
11. Arenja N, Zimmerli L, Urbaniak P, Vogel R. Acute anterior myocardial infarction after rituximab. *Dtsch Med Wochenschr* 2016; 141: 500-503. DOI: 10.1055/s-0041-106055.
12. Bambury R, Gallagher F, Dodd JD, Fennelly D. Primary cardiac lymphoma: diagnostic tools and treatment challenges. *Ir J Med Sci* 2011; 180: 271-273. DOI: 10.1007/s11845-009-0446-x.
13. Ng KH, Dearden C, Gruber P. Rituximab-induced Takotsubo syndrome: more cardiotoxic than it appears? *BMJ Case Rep* 2015. DOI:10.1136/bcr-2014-208203.
14. Arai Y, Tadokoro J, Mitani K. Ventricular tachycardia associated with infusion of rituximab in mantle cell lymphoma. *Am J Hematol* 2005; 78: 316-319. <https://doi.org/10.1002/ajh.20303>.
15. Janas E, Priest R, Malhotra R. Functional role of lipid rafts in CD20 activity? *Biochem Soc Symp* 2005; 72: 165-175.
16. Cragg MS, Walshe CA, Ivanov AO, Glennie MJ. The biology of CD20 and its potential as a target for mAb therapy. *Curr Dir Autoimmun* 2005; 8: 140-174.

Authors' contributions:

All authors contributed equally to the study.

Conflict of interests:

None.

Financial support:

None.

Ethics:

The authors had full access to the data and take full responsibility for its integrity. All authors have read and agreed with the content of the manuscript as written. All authors declare no conflict of interest. This work has been carried out in accordance with The Code of Ethics of the World Medical Association (Declaration of Helsinki) for experiments involving humans.