

Case report

Severe vascular and neurological complications after hematopoietic stem cell transplantation with reduced intensity conditioning

Krzysztof Czyżewski^{*1}, Paulina Nierychlewska^{*2}, Monika Richert-Przygońska¹, Jakub Cieściński³, Jan Styczyński¹

^{*}Both authors contributed equally to the study

¹ Department of Pediatric Hematology and Oncology, Collegium Medicum, Nicolaus Copernicus University, Bydgoszcz, Poland

² Student Scientific Society at Department of Pediatric Hematology and Oncology, Collegium Medicum, Nicolaus Copernicus University, Bydgoszcz, Poland

³ Department of Radiology and Diagnostic Imaging, Collegium Medicum, Nicolaus Copernicus University, Bydgoszcz, Poland

Correspondence:

Krzysztof Czyżewski
Department of Pediatric
Hematology and Oncology
85-094 Bydgoszcz,
Curie-Skłodowskiej 9
phone: (48 52) 585-48-60
fax: (48 52) 585-48-67
e-mail: k.czyzewski@cm.umk.pl

Received:

14.09.2018

Accepted:

19.02.2019

DOI: 10.24292/01.OR.119190219

Copyright © Medical Education.

All rights reserved.

ABSTRACT

It is well established that the benefit of myeloablative ALLO-HSCT can be associated with a potential high risk of procedure-related toxicity. The objective of this report is the analysis of complications in a 17-year-old girl with AML previously treated for medulloblastoma and myelodysplastic syndrome. Thiopeta, fludarabine, treosulfan and thymoglobuline were used in conditioning regimen. During conditioning neurological complications have occurred. MRI and CT scan results revealed the coexistence of PRES with the left internal carotid artery thrombosis. The effect of fludarabine on endothelial cells could possibly contribute to irreversible CNS damage and death in presented case.

Key words: fludarabine, ALLO-HSCT, reduced intensity conditioning, PRES, neurotoxicity

INTRODUCTION

Conventional myeloablative hematopoietic stem cell transplantation (HSCT) is associated with significant transplant related mortality (TRM) [1, 2]. Reduced-intensity conditioning (RIC) regimens decrease toxicity and risk of TRM [1], but there is still a group of patients where even standard doses of drugs used during the conditioning procedure may cause serious neurological complications [2, 3]. This divergence may depend on a presence of potential risk factors such as: multiple chemotherapeutics use, number and doses of drugs administrated before the RIC, previously treated CNS disease or conditioning to allogeneic HSCT (ALLO-HSCT) [3]. In the first year after transplantation, the incidence of CNS complications ranges in between 8% and 56% [2].

Fludarabine (FLUD) is a drug widely used in the treatment of hematological malignancies, representing one of the main components in the RIC regimens for HSCT [4]. Neurotoxicity is possible adverse event during treatment with FLUD [4].

The objective of this case report is to present severe neurological and vascular complications in patient after RIC-HSCT.

CASE REPORT

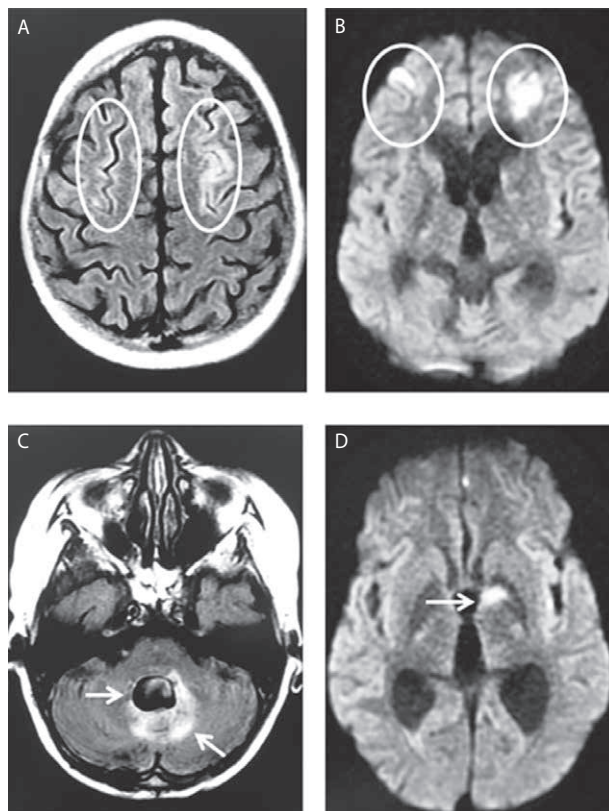
A 17-year-old girl was admitted to transplant unit to perform peripheral blood stem cell transplantation from 10/10 HLA-matched unrelated donor (MUD). The patient was previously treated for medulloblastoma diagnosed 5 years earlier. The therapy of medulloblastoma included surgery, chemotherapy (2 cycles of carboplatin, etoposide, vincristine, alternately with 2 cycles of ifosfamide, etoposide, cisplatin), radiotherapy (35 Gy for CNS and 55 Gy for primary tumor area) followed by 8 cycles of maintenance therapy (week 1: lomustine, cisplatin, vincristine; week 2: vincristine; week 3: vincristine) in six weeks intervals. One year later she was diagnosed with myelodysplastic syndrome which proceeded to acute myeloid leukemia (AML) within one year. The patient was given two courses of IDA-FLAG (idarubicin, FLUD, cytarabine, G-CSF) chemotherapy.

On admission the patient was in good clinical status presented with mild bradykinesia, headaches and unspecific vision disorders (blurred vision, central scotoma), and Karnofsky score 80. Cranial CT scans showed no relevant disorders, despite of a constant dilatation of ventricles and postoperative changes. Ophthalmological examination did not reveal any abnormalities. The patient received RIC consisting of: thiotepa (8 mg/kg) days: -7, FLUD (40 mg/m²) days: -6, -5, -4, -3, treosulfan

(14 g/m²) days -6, -5, -4 and thymoglobuline (8 mg/kg) days: -3, -2, -1. After the third day of conditioning chemotherapy the patient presented with seizures, right side hemiparesis, aphasia and progressive consciousness disorders with somnolence and confusion. In MRI an increased signal in T2 and FLAIR (cortical-subcortical) in occipital and parietal regions of the left hemisphere of the brain was observed (fig. 1). Also in deeper structures of the left hemisphere the same type of lesion (12 × 5.6 mm) were notified. Moreover other neurological abnormalities such as dilatation on fourth ventricle and in sequence DWI presence of diffused areas of a low signal responded to small areas of hemorrhage with hemosiderin were discovered. Transplant procedure was continued. After 3 days the second MRI confirmed the progression of the ischemic changes in frontal and parietal lobes, as well as in the deep structures of the left hemisphere. Also thrombotic occlusion of a left internal carotid artery in the intracranial part as well as presence of ischemic changes in left hemisphere of the brain and signs of posterior

FIGURE 1.

A, B. In the fronto-parietal regions of both hemispheres (less visible in right) of the brain in cortical and subcortical areas, the elevated signal in T2-FLAIR sequences (**A**) and diffusion restrictions in DWI sequences (**B**) are visible. **C.** The IV ventricle is widened with surrounding large areas of elevated signal in T2-FLAIR sequences. **D.** In the deep structures of brain's left hemisphere there is an area of elevated signal in DWI sequences.



reversible encephalopathy syndrome (PRES) were observed. In Doppler examination lack of the proper blood flow confirmed the occlusion of the left carotid internal artery. Ischemic stroke and PRES were diagnosed. Enoxaparinum, 20% mannitol and corticosteroids were implemented. Due to progression of the consciousness disorders and acute respiratory failure the patient was transferred to the intensive care unit. Conditioning regimen was continued and HSCT was performed with no delay. The patient condition has deteriorated with coma, high level of inflammatory indicators and renal failure. The patient died on day 3 after transplantation.

DISCUSSION

Neurological complications after ALLO-HSCT are common and life-threatening in most cases and they may affect CNS [2]. Patients who developed CNS complications after FLUD-based RIC had higher rates of 1 year non-relapse mortality (37% vs. 20%) and worse 4 years overall survival (33% vs. 45%) in comparison to patients without FLUD in conditioning regimen [2]. Only recently, clinical and MRI aspects of a possible specific neurotoxicity after standard dose FLUD both in the treatment of hematologic malignancies and in RIC HSCT have been reported [1, 3–7].

Pathophysiology of PRES is not clear. It is known that it is an endotheliopathy of the posterior cerebral vasculature leading to failed cerebral autoregulation, posterior edema and encephalopathy [8].

A number of studies has been done demonstrating effects of chemotherapy on endothelial function in cancer survivors [6, 9–11]. FLUD has the highest significance in the aspect of impairment of endothelial function [9]. Also young adults treated for acute lymphoblastic leukemia (ALL) during childhood are at risk for impaired flow-mediated dilatation regardless of whether or not they received cranial irradiation [12].

Injury to endothelial cells is the inciting factor in the sequence of events leading to thrombotic microangiopathy (TMA), which in some cases can't be easily distinguished from PRES [13]. A borderline difference in the hemorrhage rate was seen among the various clinical conditions associated with PRES [14]. Some authors found that FLUD-based non-myeloablative conditioning does not confer a lesser risk for TMA, which suggests, that FLUD itself may be involved in causing endothelial damage [10].

In case of our patient we excluded inheriting blood-clotting disorders (protein C or S deficiency, factor V Leiden defect, prothrombin defect, elevated factors II, VIII, IX, XI and antithrombin III deficiency).

CNS toxicity presenting as encephalopathy of different severity has been observed not only after FLUD administration but also with other chemotherapeutic agents, such as vincristine, cisplatin, methotrexate, cytarabine, ifosfamide, 5-fluorouracil [3, 4]. Additionally authors suggest that previous treatment with high dose cytarabine, intrathecal therapy, or cranial irradiation may be at greater risk for neurotoxicity [3]. We haven't found any evidence suggesting that other drugs, such as thiotepa or treosulfan can be involved in this process. Thiotepa-based conditioning therapy in AML is feasible, effective and safe, as investigated for sinusoidal obstruction syndrome and mucositis [15], whereas no suggestive imaging counterpart of thiotepa neurotoxicity has been proposed thus far [4]. Moreover a recent study demonstrated the efficacy and safety of treosulfan based conditioning regimens with no significant association between higher treosulfan dose and severe toxicity [16, 17].

The neurotoxicity of FLUD can have very early (hours) or late onset (months after administration) [6]. Previous treatment of our patient with high doses of chemotherapy (IDA-FLAG) and CNS radiotherapy could increased CNS susceptibility to neurotoxic properties of RIC. In case of our patients we observed coexistence of PRES and ischemic stroke. Multiple ischemic changes, brain edema and left internal carotid artery occlusion could have been caused by dysfunction in cerebral vascular autoregulation due to a direct endothelial damage. We suspect that FLUD can be also responsible for the left internal carotid artery occlusion. FLUD is a major constituent of RIC, and its effect on endothelial cells may contribute to irreversible CNS damage and death.

CONCLUSION

We should be very careful with patients who have been previously treated with chemotherapy. They are at high risk of organ toxicity during conditioning before ALLO-HSCT. Moreover FLUD toxicity should be included in a differential diagnosis of patients with unexplained CNS findings, especially in case of patients treated with this drug before.

References

1. Long-Boyle JR, Green KG, Brunstein CG et al. High fludarabine exposure and relationship with treatment-related mortality after nonmyeloablative hematopoietic cell transplantation. *Bone Marrow Transplant* 2011; 46(1): 20-26.
2. Barba P, Pinana JL, Valcarcel D et al. Early and late neurological complications after reduced-intensity conditioning allogeneic stem cell transplantation. *Biol Blood Marrow Transplant* 2009; 15(11): 1439-1446.
3. Beitinjane A, McKinney AM, Cao Q et al. Toxic leukoencephalopathy following fludarabine-associated hematopoietic cell transplantation. *Biol Blood Marrow Transplant* 2011; 17(3): 300-308.
4. Annaloro C, Costa A, Fracchiolla NS et al. Severe fludarabine neurotoxicity after reduced intensity conditioning regimen to allogeneic hematopoietic stem cell transplantation: a case report. *Clin Case Rep* 2015; 3(7): 650-655.
5. Lee MS, McKinney AM, Brace JR et al. Clinical and imaging features of fludarabine neurotoxicity. *J Neuroophthalmol* 2010; 30(1): 37-41.
6. Johnson PW, Fearnley J, Domizio P et al. Neurological illness following treatment with fludarabine. *Br J Cancer* 1994; 70(5): 966-968.
7. McKinney AM, Short J, Truwit CL et al. Posterior reversible encephalopathy syndrome: incidence of atypical regions of involvement and imaging findings. *AJR Am J Roentgenol* 2007; 189(4): 904-912.
8. Granata G, Greco A, Iannella G et al. Posterior reversible encephalopathy syndrome—Insight into pathogenesis, clinical variants and treatment approaches. *Autoimmun Rev* 2015; 14(9): 830-836.
9. Poreba M, Gac P, Usnarska-Zubkiewicz L et al. Endothelial Function in Patients with Hematologic Malignancies Undergoing High-Dose Chemotherapy Followed by Hematopoietic Stem Cell Transplantation. *Cardiovasc Toxicol* 2016; 16(2): 156-162.
10. Shimoni A, Yeshurun M, Hardan I et al. Thrombotic microangiopathy after allogeneic stem cell transplantation in the era of reduced-intensity conditioning: The incidence is not reduced. *Biol Blood Marrow Transplant* 2004; 10(7): 484-493.
11. Martin GG, Fernandez SP, Castro VS et al. Vertebral artery occlusion after chemotherapy. *Stroke* 2008; 39(2): e38; author reply e39.
12. Dengel DR, Ness KK, Glasser SP et al. Endothelial function in young adult survivors of childhood acute lymphoblastic leukemia. *J Pediatr Hematol Oncol* 2008; 30(1): 20-25.
13. Ellchuk TN, Shah LM, Hewlett RH et al. Suspicious neuroimaging pattern of thrombotic microangiopathy. *AJNR Am J Neuroradiol* 2011; 32(4): 734-738.
14. Hefzy HM, Bartynski WS, Boardman JF et al. Hemorrhage in posterior reversible encephalopathy syndrome: imaging and clinical features. *AJNR Am J Neuroradiol* 2009; 30(7): 1371-1379.
15. Eder S, Labopin M, Finke J et al. Safety and efficacy of thiotepa-based conditioning for allogeneic transplantation in AML: a survey from the ALWP of the EBMT. *Bone Marrow Transplant* 2017; 52(2): 238-244.
16. Boztug H, Zecca M, Sykora KW et al. Treosulfan-based conditioning regimens for allogeneic HSCT in children with acute lymphoblastic leukaemia. *Ann Hematol* 2015; 94(2): 297-306.
17. Slatter MA, Boztug H, Potschger U et al. Treosulfan-based conditioning regimens for allogeneic haematopoietic stem cell transplantation in children with non-malignant diseases. *Bone Marrow Transplant* 2015; 50(12): 1536-1541.

Authors' contributions:

Krzysztof Czyżewski: the concept of the article, data collection and interpretation, manuscript writing, critical revision of the manuscript, final approval of manuscript;

Paulina Nierychlewska: data collection and interpretation, manuscript writing, critical revision of the manuscript, final approval of manuscript;

Monika Richert-Przygońska: data collection and interpretation, critical revision of the manuscript, final approval of manuscript;

Jakub Cieściński: data collection and interpretation, critical revision of the manuscript, final approval of manuscript;

Jan Styczyński: data collection and interpretation, critical revision of the manuscript, final approval of manuscript.

Conflict of interests:

None.

Financial support:

None.

Ethics:

The authors had full access to the data and take full responsibility for its integrity. All authors have read and agreed with the content of the manuscript as written. All authors declare no conflict of interest.

This work has been carried out in accordance with The Code of Ethics of the World Medical Association (Declaration of Helsinki) for experiments involving humans.