

Case report

## The massive nodular cutaneous and soft tissues lesions of the right shoulder and the arm as the extramedullary manifestation of the advanced stage of multiple myeloma

**Arkadiusz Drobiecki<sup>1</sup>, Marcin Pasiarski<sup>1, 2</sup>, Agnieszka Stelmach-Góldyś<sup>1</sup>, Bartosz Garus<sup>1</sup>**

<sup>1</sup> Clinic of Hematology of the Holy Cross Centre in Kielce, Poland

<sup>2</sup> The Faculty of Medicine and Health Science, Jan Kochanowski University Kielce, Poland

For non-commercial use only

### Correspondence:

Arkadiusz Drobiecki  
Clinic of Hematology of the Holy Cross Centre in Kielce, Poland  
25-734 Kielce, ul. Artwińskiego 3  
tel.: +48 41 3674 848  
e-mail: arekdro@gmail.com

### Received:

15.12.2017.

### Accepted:

20.12.2017.

DOI: 10.24292/01.OR.201217  
Copyright © Medical Education.  
All rights reserved.

### ABSTRACT

Cutaneous and soft tissue involvement is a very rare manifestation of multiple myeloma. We are describing a woman with the huge multiple plasma cells infiltrations of the soft tissues and the skin of the right shoulder and the arm that had occurred 2.5 years after the diagnosis of multiple myeloma. In the case of the described patient there is a distinct correlation between the appearance of the nodular lesions in soft tissues and the underlying osteolytic changes found in the skeleton. We assumed that the fracture of the right humerus in the past was the beginning of the plasma cells dissemination in the adherent tissues. The skin changes in our patient appeared in the advanced stage of multiple myeloma. There was only transient improvement of cutaneous changes after the chemotherapy, despite the complete remission of the underlying disease in the bone marrow. Despite of the intensive treatment (chemotherapy, radiotherapy) the patient died 7 months after the first appearance of the skin changes.

**Key words:** multiple myeloma, cutaneous involvement

## INTRODUCTION

Extramedullary manifestation of plasma cell neoplasms can be divided into primary and secondary lesions. Secondary lesions are considered as the metastases resulting from the haematogenous spread of multiple myeloma or infiltrations of the soft tissues adjacent to the bones involved in the disease process. Cutaneous and soft tissue involvement is a very rare manifestation of multiple myeloma [1]. Sometimes the cutaneous changes are considered to be reactive to the course of the disease. According to Kois et al. [2] there are a few forms of such manifestation: extramedullary cutaneous plasmacytomas, cutaneous amyloidosis, pyoderma gangrenosum, leukocytoclastic vasculitis, necrobiotic xanthogranuloma, scleromyxedema, Sweet's syndrome, subcorneal pustular dermatosis, POEMS syndrome, scleredema, angioedema with C1 inhibitor deficiency, plane xanthomas, follicular hyperkeratosis.

We are describing a woman with the huge multiple plasma cells infiltrations of the soft tissues and the skin of the right shoulder and the arm that had occurred two and a half years after the diagnosis of multiple myeloma.

## CASE STUDY

In December 2000 the diagnosis of multiple myeloma in a 65-year-old woman was established. At the time of the presentation the serum level of a monoclonal protein IgA was 3.21 g/l, proteinuria 2.38 g/l. Light chains kappa were detected in the urine. Bone marrow smear revealed 40% of plasma cells. There were numerous osteolytic lesions in the radiographs of the skeleton. This patient received the chemotherapy from January 2001 to January 2002 (VMBCP, VBCP). Partial remission was achieved. Serum level of monoclonal protein decreased to 1.96 g/l and proteinuria disappeared. Examination of the bone marrow revealed 12% infiltration of the plasma cells. In June 2002 the patient suffered from the pathological fracture of the right humerus. After 4 months of conservative treatment partial synostosis was achieved. In August 2002, because of the progression of the osteolysis and the anaemia, the VBCP chemotherapy was started again. A very intensive shoulder pain with concomitant swelling occurred in October 2002. Additionally a nodule 13 mm in diameter was found in the front axillary line of the chest. It was probably the extension of the tumour from the eighth rib. These changes were accompanied by considerable swelling, reddening and warming up of the shoulder. Histological evaluation of the surgically removed lesions revealed infiltration of plasma cells. The rapid progression of the underlying disease was observed. The serum level of the monoclonal protein was 14.4 g/l and there were 45% plasma cells detected in the bone marrow smear. In

November 2002, nodular subcutaneous infiltration (15 × 15 cm) in the upper part of the right shoulder was noticed. Despite the new treatment regimen (VDBCP) and palliative radiotherapy (600 cGy dosage) on the right shoulder region, the progression of the infiltrative lesions was observed. In January 2003 subcutaneous infiltrations and lesions spread and enlarged rapidly in the shape of cyanosed cauliflower-like tumours which spread across the whole shoulder, arm and to the frontal part of the chest with concomitant increasing of swelling, pain and dysfunction of the affected limb [fig. 1, 2]. CT scans showed the pathological mass in the soft tissues of the right shoulder and its surroundings [fig. 3]. The tumour spread through the thorax reaching the right subclavicular fossa. After the intensified treatment (cyclophosphamide, etoposide, idarubicin, dexamethason), the distinct but transient improvement was achieved [fig. 4, 5]. The histopathological examination of bone marrow showed the disappearance of plasmacytes. The subsequent course of chemotherapy was implemented due to the recurrence of the cutaneous changes described above. Despite the continuing treatment further regression was not achieved.

FIGURE 1, 2.

The skin changes of advanced stage of the disease before chemotherapy intensification.

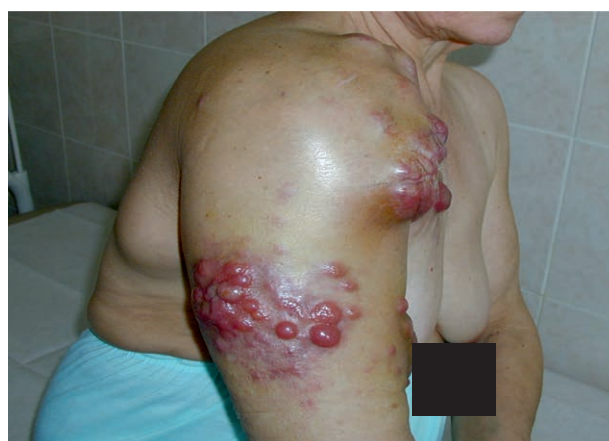
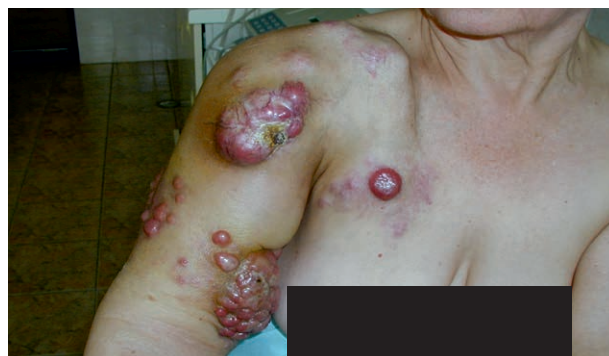
FIGURE 3.

The pathological mass in the soft tissues of the right shoulder and its surroundings.

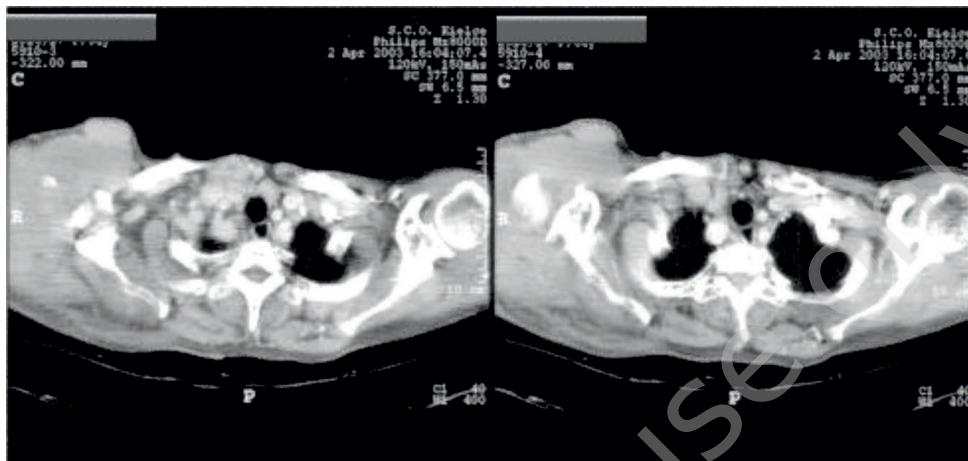


FIGURE 4.

The distinct but transient improvement of described changes after applied treatment regimens.

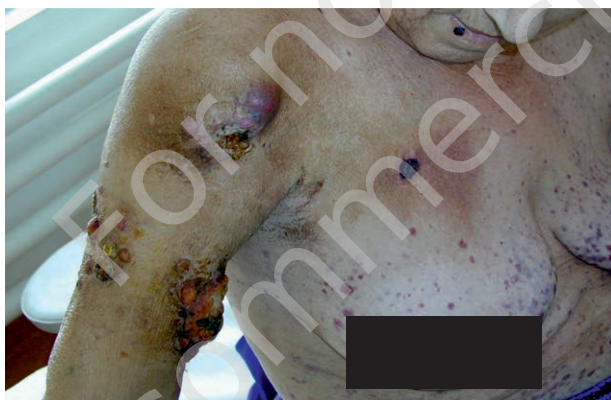
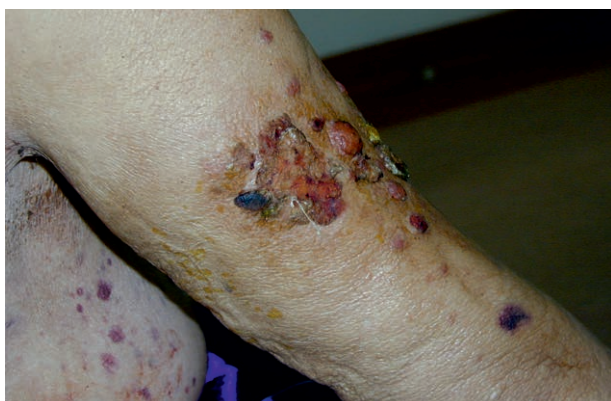
FIGURE 5.

The distinct but transient improvement of described changes after applied treatment regimens.



## DISCUSSION

Cutaneous involvement in the course of multiple myeloma is the effect of the infiltration from the adjacent bones with osteolytic-

ic changes. Metastatic lesions in the skin far from the osteolytic bones are very rare. It usually occurs in late stages of multiple myeloma as a reflection of increased tumor cell burden. Review of the literature regarding specific cutaneous involvement in multiple myeloma, revealed almost 100 patients in whom skin plasma cells infiltrations were discovered without the underlying bone lesions [3]. There are many forms of skin manifestations of plasma cells infiltrations. The nodular and interstitial pattern are the most frequent. The whole skin thickness is involved, sometimes sparing the epidermis. Nodular lesions consist of single or multiple clusters of neoplastic plasma cells arranged as relatively cohesive masses. On the contrary interstitial lesions are formed of strands and narrow cords of neoplastic plasma cells arranged between collagen bundles of the dermis. Cases of huge limited skin lesions with ulceration and secondary infections were also described. Cutaneous involvement in multiple myeloma may appear in any area of the skin, but it has been reported most commonly on the trunk and abdomen, followed by the scalp, face, neck, lower and upper extremities [2–6]. The origin of the infiltrating cells can be easily identified histopathologically. They usually are plasma cells of various maturity, some of them bi- or multinucleated and sometimes atypical [3].

The risk of cutaneous involvement is not associated with a particular class of myeloma immunoglobulins. In one of the articles 83 cases with metastatic cutaneous plasmacytomas in multiple myeloma were analysed. Among these cases with IgG, IgA, IgD, and Bence-Jones proteins skin changes were found in 52, 23%, 16% and 6% respectively. According to the other authors skin infiltrations of the plasma cells occur more often if IgA monoclonal immunoglobulins are detected in the serum, similarly to the our case described [3, 7, 8].

There is a clear correlation between the appearance of the nodular lesions in soft tissues and the underlying osteolytic changes in the skeleton in the described case of the patient. We assume that the fracture of the right humerus in the past was the beginning of the plasma cells dissemination in the adherent tissues. Skin infiltrations started to spread rapidly into the adjacent areas, i.e. thorax and progressed to wide lesion involving almost all shoulder and subclavial region.

A similar case was found in the literature. A 59-year-old woman with Durie-Salamon stage IIIB IgG  $\kappa$  multiple myeloma presented eighty three days after autologous hematopoietic stem cell transplantation with multiple subcutaneous plasmacytomas. These lesions were confined exclusively to the sites of the previous injections [9]. A few cases of extramedullary dissemination of plasma cells to the skin and the urinary bladder [10], to the pleura [11], and other examples of skin involvement [12–14] were described as the first manifestation of multiple myeloma. The survival time in all presenting cases of multiple myeloma with cutaneous involvement was limited to a few months only. The skin changes observed in our patient appeared in the ad-

vanced stage of multiple myeloma, after 2.5 years from the diagnosis of the disease. Their occurrence had clear relevance to the repeated trauma (fracture of the humerus, histopathological biopsy). After the chemotherapy there was only transient improvement of cutaneous lesions, despite the complete disappearance of plasmocytes in the bone marrow. Metastases were detected in other parts of the body i.e. the abdominal cavity, the pelvis and the skull. In spite of the intensive treatment (chemotherapy, radiotherapy) the patient died seven months after the first appearance of the skin changes.

Currently modern therapeutic regimens based on agents that inhibit angiogenesis and proteasome inhibitors are used as a main treatment of multiple myeloma for many years. Over the last decade of our observation the course of multiple myeloma has changed radically and there have been no spectacular extramedullary changes of the disease observed since the implementation of the new agents. We also hope that such changes will be no longer observed in patients with multiple myeloma in the future, so that the presented case seems to be a good example and reminder about the course of resistant multiple myeloma in the past.

## References

1. Diwan AG, Gholap NN, Taneja SR. Extramedullary plasmacytoma associated with multiple myeloma. *J Assoc Physicians India* 2003; 51: 236-237.
2. Kojs JM, Sexton FM, Lookingbill DP. Cutaneous manifestations of multiple myeloma. *Arch Dermatol* 1991; 127: 69-74.
3. Requena L, Kutzner H, Palmedo G et al. Cutaneous involvement in multiple myeloma: a clinicopathologic, immunohistochemical, and cytogenetic study of 8 cases. *Arch Dermatol* 2003; 139: 475-486.
4. Bayer-Garner IB, Smoller BR. The spectrum of cutaneous disease in multiple myeloma. *J Am Acad Dermatol* 2003; 48: 497-507.
5. Green T, Grant J, Pye R, Marcus R. Multiple primary cutaneous plasmacytomas. *Arch Dermatol* 1992; 128: 962-965.
6. Procopiou M, Hügli A. A 29 year-old man with multiple myeloma presenting with subcutaneous masses. University Hospital Geneva, Department of Internal Medicine, Switzerland.
7. Garcia-Malo MD, Vallejo C, Vincente V. IgA multiple myeloma with multiple cutaneous plasmacytomas. *Haematologica* 2001; 86: 1118.
8. Kato N, Kimura K, Yasukawa K, Aikawa K. Metastatic cutaneous plasmacytoma: a case report associated with IgA lambda multiple myeloma and a review of the literature of metastatic cutaneous plasmacytomas associated with multiple myeloma and primary cutaneous plasmacytomas. *J Dermatol* 1999; 26: 587-594.
9. Rosenblum MD, Bredeson CN, Chang CC, Rizzo JD. Subcutaneous plasmacytomas with tropism to sites of previous trauma in a multiple myeloma patient treated with an autologous bone marrow transplant. *Am J Hematol* 2003; 72: 274-277.
10. Shpilberg O, Yaniv R, Levy Y et al. Huge cutaneous plasmacytomas complicating multiple myeloma. *Clin Exp Dermatol* 1994; 19: 324-326.
11. Vianelli N, Tosi P. Plasmacytoma with cutaneous and pleural involvement. *Haematologica* 1999; 84: 559.
12. Wong DA, Hunt MJ, Stapleton K. IgA multiple myeloma presenting as an acquired bullous disorder. *Australas J Dermatol* 1999; 40: 31-34.
13. Patterson JW, Parsons JM, White RM et al. Cutaneous involvement of multiple myeloma and extramedullary plasmacytoma. *J Am Acad Dermatol* 1988; 19: 879-890.
14. Patel K, Carrington PA, Bhatnagar S et al. IgD myeloma with multiple cutaneous plasmacytomas. *Clin Lab Haematol* 1998; 20: 53-55.

## Authors' contributions:

Arkadiusz Drobiecki and Marcin Pasiarski conceived the original idea. Arkadiusz Drobiecki wrote the manuscript with the support from Agnieszka Stelmach-Goldyś and Bartosz Garus. All authors discussed the case. Both Arkadiusz Drobiecki and Marcin Pasiarski contributed to the final version of the manuscript.

## Conflict of interests:

None.

## Financial support:

None.

## Ethics:

The paper complies with the Helsinki Declaration, EU Directives and harmonized requirements for biomedical journals.