

# Percutaneous retrieval of a fractured portacath fragment in two patients undergoing long-term chemotherapy

*Justyna Norwa, MD<sup>1</sup>, Szymon Darocha, MD<sup>1</sup>, Anna Dobosiewicz, MD<sup>1</sup>,  
Andrzej Koteja, MD<sup>2</sup>, Arkadiusz Pietrasik, MD, PhD<sup>3</sup>,  
Radosław Pietura, MD, PhD<sup>4</sup>,  
Prof. Adam Torbicki, MD, PhD<sup>1</sup>, Sebastian Szmit, MD, PhD<sup>1</sup>,  
Marcin Kurzyna, MD, PhD, Assoc. Prof.<sup>1</sup>*

<sup>1</sup> *Department of Pulmonary Circulation and Thromboembolic Diseases, Centre of Postgraduate Medical Education, European Health Centre Otwock, Otwock, Poland  
Head of the Department: Prof. Adam Torbicki, MD, PhD*

<sup>2</sup> *Intensive Care Unit, European Health Centre Otwock, Otwock, Poland*

<sup>3</sup> *I Department of Cardiology, Medical University of Warsaw, Poland*

<sup>4</sup> *Department of Radiology and Diagnostic Imaging,  
Independent Public Clinical Hospital No. 1 in Lublin, Poland*

Received: 13.05.2016. Accepted: 19.05.2016.

## ABSTRACT

The paper discusses two clinical cases of cancer patients undergoing chemotherapy, in whom fractured and displaced tips of portacath catheters were revealed based on plain chest imaging. In the first case, the portacath fragment migrated to the left pulmonary artery, with the missing catheter tip revealed during the procedure of port removal due to its occlusion, with no other prior clinical symptoms. In the second case, the catheter broke off at the level of its entry into the subclavian vein, and migrated into the right cardiac ventricle, which was accompanied by mild pain and oedema in the subclavicular region. Both patients underwent successful procedures of percutaneous foreign body retrieval with the use of endovascular snares. The procedures were performed via femoral vein access, with no complications.

**KEY WORDS:** central venous port, endovascular removal, chemotherapy, cancer

## Correspondence:

Justyna Norwa, MD

Department of Pulmonary Circulation and Thromboembolic Diseases,  
Centre of Postgraduate Medical Education, European Health Centre Otwock

05-400 Otwock, ul. Borowa 14/18

e-mail: norwaj@wp.pl

## INTRODUCTION

Long-term venous access devices are now widely applied in different fields of medicine. A special type of such a device is the portacath implanted for chemotherapy, whose chamber for drug delivery is inserted in the subcutaneous tissue, connected with the central vein system with a catheter. The catheter that runs from the port is usually inserted into the subclavian or internal jugular vein, and terminates in the superior vena cava, just upstream of the right atrium. Unlike the simple peripheral venous catheter, a central venous access port may be left in place for many months to come. It is of paramount importance in long-term treatment of patients who require repeated infusions of therapeutic agents which irritate vascular walls. Unfortunately, despite its many advantages, the method is not devoid of complications. The most common complications include infection-related events, and thromboembolic incidents [1].

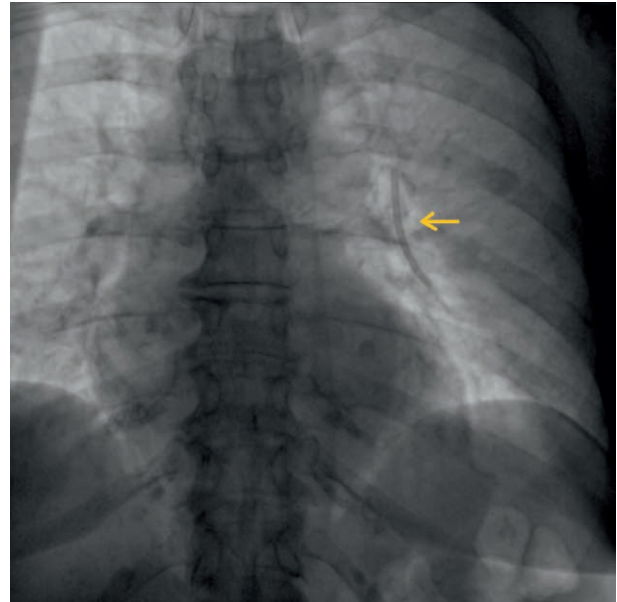
The present paper discusses two clinical cases of patients admitted to the Clinic of Pulmonary Circulation and Thromboembolic Diseases in Otwock at one-month interval, who experienced one of the least frequently reported types of complications, i.e. detachment of a fragment of central catheter from the venous port.

### CASE REPORT 1<sup>st</sup>

A 69-year-old patient with a history of rectal cancer, following radiotherapy and surgery in April 2014 (abdominoperineal resection of the rectum with colostomy), and chemotherapy for lung metastases (5 courses of FOLFIRI) from April to August 2015, was admitted to the Clinic for the retrieval of a broken portacath fragment that had migrated into the pulmonary vessels. Based on the patient's history and medical files, it was established that the port had been implanted in the right subclavian region on 22<sup>nd</sup> April, 2015, and that towards the end of October 2015, an unsuccessful attempt had been made to flush the port. Two weeks later, when examining the port under fluoroscopy, the distal 5 cm tip of the catheter had been revealed as missing. Subsequently, the detached fragment had been visualised in the left lung field (fig. 1). At the same time, the non-patent port had been removed, leaving the missing fragment behind for further intervention. The patient was started on enoxaparin dosed at 40 mg per 24 h to prevent local thrombotic complications. Upon the admission to the Clinic of Pulmonary Circulation and Thromboembolic Diseases, on 30<sup>th</sup> November, 2015, the patient's general condition was good, and she was haemodynamically stable. She did not report any chest pain or discomfort, haemoptysis or palpitation. She claimed that since the comple-

FIGURE 1.

Fragment of the fractured central catheter, detached from the chemotherapy port, visualized in the field of the left inferior lobar artery. The examination was performed after the removal of the port.



tion of chemotherapy, she had not observed any alarming symptoms. Resting ECG revealed no cardiac rhythm abnormalities. On 1<sup>st</sup> December, 2015, fluoroscopy-guided angiography of the left inferior lobar artery was performed via the femoral vein, revealing a fragment of the catheter, wedged in the artery up to segment 8, with the proximal tip located in the inferior lobar artery. Subsequently, with the use of a 6F guiding sheath (Cook Flexor, 6F, 70 cm) and a triple-loop snare (Merit Medical, EN Snare, 6F), one of the tips of the broken catheter was grasped, and the catheter was thus removed from the vascular system. There were no complications reported during the procedure or afterwards, during the monitoring period at the Cardiac Intensive Care Unit. In agreement with the clinical oncologist supervising the patient, and taking into consideration the lack of neoplastic disease progression, and the absence of any additional thrombotic risk factors, it was decided that on the day of the patient's discharge from the Clinic, there were no indications for long-term antithrombotic treatment.

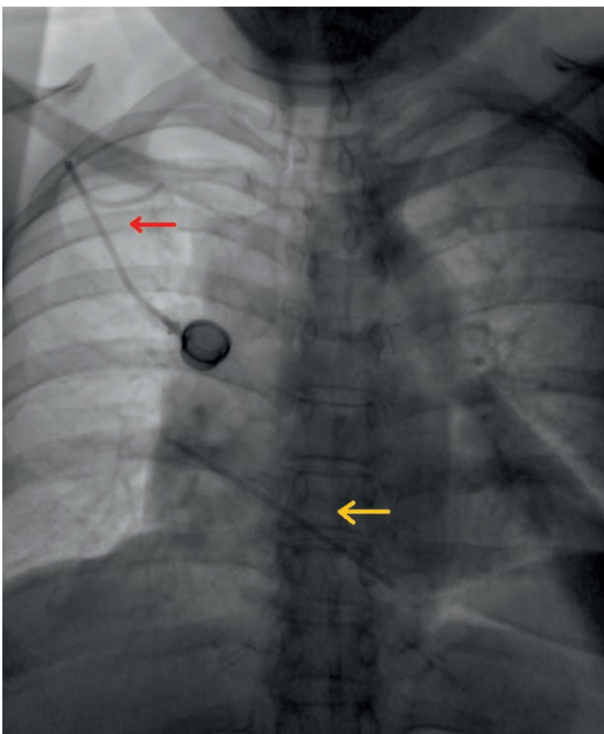
### CASE REPORT 2<sup>nd</sup>

A 59-year-old patient, who had undergone preventative hysteroadnexectomy in 2008 (due to confirmed *BRCA1* gene mutation), was diagnosed with primary peritoneal cancer 2 years later, and underwent cytoreductive surgery, followed by chemotherapy for the subsequent cancer recurrences. The patient received 6 courses of paclitaxel with carboplatin from Septem-

ber 2010 to January 2011, followed by 6 courses of carboplatin as monotherapy from April to October 2014, and later on by 5 courses of doxorubicin that the patient was started on in April 2015. Eventually, in September 2015, the regimen was changed to gemcitabine plus cisplatin, with 4 courses administered to the patient by January 2016. Additionally, the patient received anti-thrombotic treatment with subcutaneous enoxaparin dosed at  $1 \times 100 \text{ mg}/24 \text{ h}$  due to a past thrombosis at the tip of the central catheter, confirmed in CT in September 2015.

On 10<sup>th</sup> January 2016, the patient was admitted to the Clinic of Pulmonary Circulation and Thromboembolic Diseases due to a fragment of chemotherapy portacath visualised in the right heart in a chest X-ray examination. On that day, the patient reported for a scheduled oncological consultation visit before the next course of chemotherapy. She complained about pain and slight oedema in the right subclavicular region (port implantation site) that appeared around 2 weeks before the visit and was gradually receding. Due to the complaint, chest X-ray was performed, revealing a foreign body in the field of the right atrium and the right ventricle (fig. 2). The patient's medical records indicated that the portacath had been implanted in March 2015. Upon the admission to the Clinic, the patient's general condition

FIGURE 2. Vascular port in the right subclavicular region, with the catheter broken off in the region of its entry into the subclavian vein (red arrow). The detached fragment of the catheter visualized in the field of the right atrium and right ventricle (yellow arrow).



was good, and she did not complain about chest pain or palpitation. No cardiac rhythm abnormalities were observed under resting ECG or the patient's observation at the Cardiac Intensive Care Unit. No local lesions were reported within the site of the implanted port. An echocardiogram revealed an additional echo in the right atrium, running along its wall, and most probably reaching into the right ventricle. In the local cathlab, a 6F pigtail catheter was inserted through the femoral access under fluoroscopy, grasping the detached portacath fragment, and moving one of its tips into the inferior vena cava (fig. 3). Subsequently, with the help of a triple lasso catheter (Argon, Atrieve Vascular Snare, 6F), the tip of the portacath located in the inferior vena cava was grasped (fig. 4), and the catheter was removed from the vascular system (fig. 5). There were no complications in the perioperative period. Due to a history of venous thrombosis, presence of an active neoplastic disease, and the need for further chemotherapy, it was decided that antithrombotic secondary prevention be continued with enoxaparin dosed at  $1 \times 1.5 \text{ mg}/\text{kg}/24 \text{ h}$ .

FIGURE 3. The fractured fragment of the portacath translocated from the right atrium to the inferior vena cava.

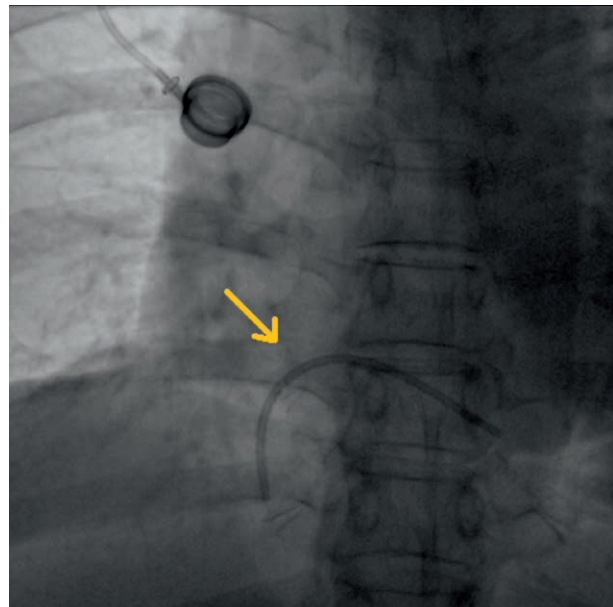


FIGURE 4.  
Catheter tip grasped with the help of an endovascular snare in the inferior vena cava.

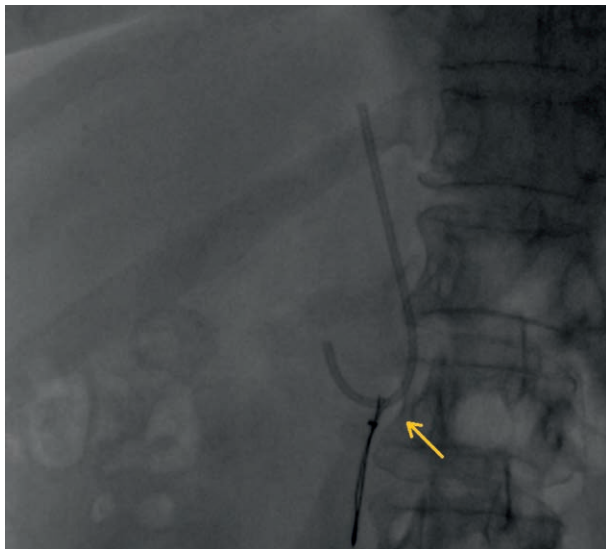
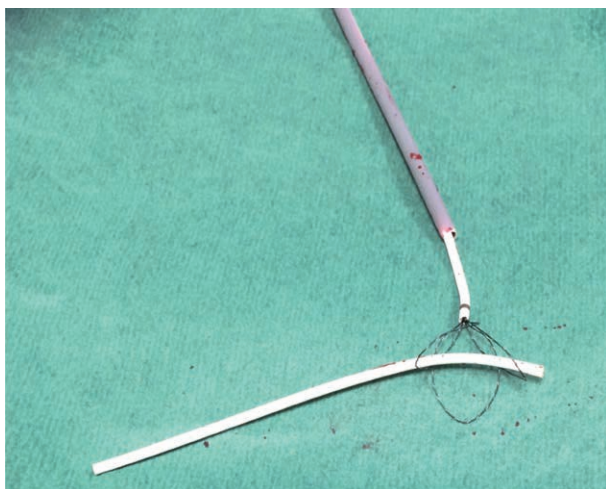

FIGURE 5.  
Status post retrieval of the portacath catheter – the Atrieve Vascular Snare device.



## DISCUSSION

The availability and low complexity of the portacath implantation procedure have led to their wide application in the long-term treatment of oncological patients who require intravenous chemotherapy. However, one needs to remember about the possible complications related to the presence of a foreign body within the central vascular system. The most common complications are related to implantation, and include events such as pneumothorax and haematoma at the implantation site, followed by venous thrombosis, and local and systemic infections. The least frequent complications are related to the dislocation or

fracture of the catheter, including events such as perforation of the vascular system, translocation of the catheter to the cardiac chambers and pulmonary arteries, dangerous vascular rhythm abnormalities, and pulmonary vessel occlusion. Barbetakis et al. made an attempt at estimating the incidence of such adverse events in 2011, analysing the effects of central intravascular catheter implantation in 700 cancer patients. They assessed the rate of catheter fracture or translocation to the pulmonary arteries as very low, with 0.4% and 0.3% respectively, as compared with thrombotic and infectious complications (4.7% and 4.1%) [1, 2]. Importantly, there may be no symptoms related to catheter translocation or they may be highly non-specific, including coughing, atypical and minor retrosternal and subclavicular discomfort, i.e. discomfort in the region of the catheter's migration to the venous system. It may also happen that drugs are delivered to the subcutaneous tissue, causing enhanced local reactions. In the two cases mentioned above, the diagnosis was somewhat incidental, with the radiology examinations performed in order to inspect a non-patent port (in the first case), and to verify non-specific subclavicular discomfort reported by the patient before another course of chemotherapy (in the second case). According to some authors, over 50% of the translocation cases are detected by accident, based on a chest X-ray examination [3], which might justify periodic radiological control of the central catheter placement in patients undergoing chemotherapy with the use of a portacath. Echocardiography is another test which may prove helpful, when trying to verify the position of catheter fragments within the heart. The test allows us to assess the possible complications within the myocardium, including valvular injury, perforation or pericardial effusion. Unfortunately, echocardiography cannot visualize the pulmonary vessels (apart from the initial segments of the main arteries), and the result of the examination also depends on the experience of the doctor who performs it, as it is not specifically designed to search for foreign bodies within the system [4].

Diagnosis of a damaged intravascular catheter, irrespective of the presence of signs and symptoms, is an indication for its removal in order to prevent possible serious complications [3–6]. The management of choice should be percutaneous retrieval of the foreign body [3, 5–7], being a highly efficacious (89%) and low-invasive method associated with a low risk of complications (mainly affecting the site of the vascular access) [6]. If the percutaneous procedure fails, cardio-surgical intervention may be required. However, such situations are sporadic and involve broken catheter fragments which have migrated into the heart of a patient whose long-term prognosis is good [8]. In the case of catheter fragments which have migrated into the branches of

the pulmonary artery, and cannot be retrieved percutaneously, decisions on surgical intervention should be taken with due caution, depending on the location of the foreign body as well as on the advancement of the oncological disease. Upon the diagnosis

of a foreign body within the pulmonary arteries, one should also review the indications for antithrombotic treatment, depending on the concomitant diseases, the type and activity of the neoplastic disease.

## References

1. Darocha S, Szmit S, Walaszewska-Czyż A et al. Central venous catheters and complications in cancer patients. *OncoReview* 2012; 2(3): 194-198.
2. Barbetakis N, Asteriou C, Kleontas A et al. Totally implantable central venous access ports. Analysis of 700 cases. *J Surg Oncol* 2011; 104(6): 654-656.
3. Surov A, Buerke M, John E et al. Intravenous port catheter embolization: mechanisms, clinical features, and management. *Angiology* 2008; 59: 90-97.
4. Pawłowski K, Dorniak W, Trenkner W et al. Percutaneous retrieval of foreign body inducing potentially fatal complex ventricular arrhythmias in a patient with acute myocardial infarction. *Post Kardiol Interw* 2008; 4, 1(11): 46-48.
5. Surov A, Jordan K, Buerke M et al. Atypical pulmonary embolism of port catheter fragments in oncology patients. *Support Care Cancer* 2006; 14: 479-483.
6. Gabelmann A, Kramer S, Gorich J. Percutaneous retrieval of lost or misplaced intravascular objects. *Am J Roentgenol* 2001; 176: 1509-1513.
7. Thomas J, Sinclair-Smith B, Bloomfield D et al. Nonsurgical retrieval of broken segment of steel spring guide from the right atrium and inferior vena cava. *Circulation* 1964; 30: 106-108.
8. Kapadia S, Parakh R, Grover T et al. Catheter fracture and cardiac migration of a totally implantable venous device. *Indian J Cancer* 2005; 42: 155-157.

### Authors' contributions:

Justyna Norwa: case reports, first version of discussion

Anna Dobosiewicz: abstract

Szymon Darocha: figures

Andrzej Koteja: part about central venous port

Arkadiusz Pietrasik: assistance in the selection of the literature

Radosław Pietura: supervision over the correctness of factual description of procedures

Sebastian Szmit: checking the article for oncologic aspects

Marcin Kurzyna: supervision over the discussion and summary

Adam Torbicki: supervision over the article, acceptance of the article.