

Recurrent invasive pulmonary aspergillosis or breakthrough fungal infection in a child after haploidentical hematopoietic stem cell transplantation

Tomasz Ociepa, MD, PhD

*Department of Paediatrics, Paediatric Haematology and Oncology,
Independent Public Clinical Hospital No. 1, Szczecin, Poland*

Received: 12.05.2016. Accepted: 30.05.2016.

ABSTRACT

Invasive fungal infections (IFI) are devastating and life-threatening infections affecting especially immunocompromised patients. We report on a case of a 14-year-old boy with myelodysplastic syndrome (MDS), after haploidentical hematopoietic stem cell transplantation, in whom invasive pulmonary aspergillosis (IA) was diagnosed and successfully treated with subsequent (despite the secondary antifungal prophylaxis) IA or breakthrough infection development. Thanks to intensive and broad spectrum antifungal treatment (voriconazole upfront therapy, followed by a combination of voriconazole and micafungin, and eventually by the amphotericin B lipid complex), significant improvement was accomplished.

KEY WORDS: invasive fungal infection, invasive pulmonary aspergillosis, children, breakthrough infection, hematopoietic stem cell transplantation

Correspondence:

Tomasz Ociepa, MD, PhD
Department of Paediatrics, Paediatric Haematology and Oncology,
Independent Public Clinical Hospital No. 1
71-252 Szczecin, ul. Unii Lubelskiej 1
tel.: (91) 425-31-39, 425-31-57
e-mail: tociepa@gmail.com

INTRODUCTION

Myelodysplastic syndrome (MDS) is a clonal disease of the hematopoietic system, which is generally associated with the presence of single or multiple-lineage cytopenia of varying intensity. In some cases, MDS evolves into acute myeloid leukaemia (AML). The only efficacious form of MDS treatment in paediatric patients is hematopoietic stem cell transplantation. Some authors believe that symptomatic treatment should be offered until transfusion dependency develops or the risk of infection increases (which is usually caused by persistent neutropenia) [1]. Hematopoietic stem cell transplantation may be a long-lasting compensation for the previous hematologic disturbances, but it significantly increases the risk of numerous complications, including invasive fungal infections (IFI). According to ECIL (*European Conference on Infections in Leukemia*), patients following allogeneic hematopoietic stem cell transplantation are the high risk group for IFI due to the initial prolonged neutropenia, the use of immunosuppressive drugs, including glucocorticosteroids, and the graft-versus-host disease (GvHD) [2]. All those factors predispose patients to mould fungal infections in particular. The type of infection is also influenced by individual and environmental factors such as the local epidemiology, construction and renovation works carried out in the vicinity of the medical centre, type of transplantation, patient age, lack of HEPA filters, and iron overload. The most common type of IFI caused by mould fungi in high risk children is pulmonary aspergillosis, caused by the *Aspergillus fumigatus* species (or more rarely *Aspergillus flavus*) [3]. Despite the progress in early diagnostics (systematic galactomannan antigen assessment, imaging tests) and treatment (new generation antifungals: voriconazole, echinocandins, posaconazole, liposomal and lipid formulations of amphotericin B), mortality is still high in invasive aspergillosis (IA), remaining at the level of 40–70% [3, 4]. Thus treatment of IA is truly an important challenge in high risk patients.

CASE PRESENTATION

A 14-year-old boy was diagnosed with refractory cytopenia subtype of myelodysplastic syndrome (MDS-RC) at the age of 11. He was after multiple platelet concentrate transfusions finally followed by two haploidentical hematopoietic stem cell transplantations at the age of 13. The transplantation was complicated by development of acute skin GvHD and viral infections (BKV and ADV). Glucocorticosteroids and antivirals were administered with good response. In month 11th following transplantation, another exacerbation of skin GvHD was detected. The glucocorticosteroid dose (methylprednisolone) was escalated to 1 mg/kg/24 h. Gradual improvement was observed. Due to

a cough, which appeared concurrently with the initiation of the glucocorticosteroid therapy, with only minor initial auscultatory findings (isolated crepitations) and the patient's good general condition, chest CT was performed, which failed to reveal lesions typical of pneumonia and IA. As part of further diagnostics, serum galactomannan antigen was tested twice, revealing normal titres. As the respiratory symptoms aggravated (cough, chest pain), with moderately elevated CRP level, and in light of the unsuccessful broad spectrum antibiotic therapy, bronchoscopy was performed to harvest material for microbiology tests. Macroscopic lesions suggestive of an infection (erosions, whitish coating) were revealed, bronchial washings culture was positive (*Aspergillus flavus*), and the GM titres were high (4.231–5.335). Antifungal therapy was initiated (voriconazole at a dose of 2 × 6 mg/kg on day one, followed by 2 × 4 mg/kg/24 h). On day 5th of the therapy, the concentration of voriconazole was measured (TDM, therapeutic drug monitoring). As 12 hours after its administration the concentration of the drug was lower than the reference values (0.77 µg/ml), the dose was escalated to 2 × 5 mg/kg/24 hours. Gradual clinical improvement was reported, with lower CRP and regression of the auscultatory signs. The 14-day-long intravenous treatment was replaced by oral administration of the drug at a dose of 2 × 200 mg/24 h. Figure 1 presents the treatment algorithm.

Upon completion of the treatment (which lasted 4 weeks altogether), with normal chest CT results and negative GM test, the patient was qualified for IFI prophylaxis (posaconazole at a dose of 3 × 200 mg/24 h). After the following 4 weeks, the patient was readmitted to the Department of Paediatric Haematology with signs of septic shock (initial vital signs: blood pressure 60/40 mmHg, heart rate 160/min, O₂ saturation: 70%). An intestinal infection (acute diarrhoea) was accompanied by elevated inflammatory markers (CRP > 200 mg/l, procalcitonin 66.3 ng/ml), and high activity of liver enzymes (ALT 3447 U/l, AST 4650 U/l). Intensive treatment (broad spectrum antibiotic therapy and supportive management) initially brought improvement. However, in the following days, the patient's condition was exacerbated again (persistent fever, CRP on the increase). As IFI was suspected, combined antifungal therapy was initiated, with voriconazole (2 × 6 mg/kg/24 h on day one, followed by 2 × 5 mg/kg/24 h i.v. starting from day 2) and micafungin dosed at 2 mg/kg/24 h i.v. Despite the treatment, the boy's condition continued to worsen, evolving into a symptomatic pneumonia. Chest CT was performed, revealing diffuse parenchymal densities in both lungs, nodular lesions, inflammatory and atelectatic lesions, predominantly in the right lung, and fluid in the right pleural cavity with density of up to 5 HU (fig. 2).

FIGURE 1.
Diagnostic and therapeutic algorithm in IA.

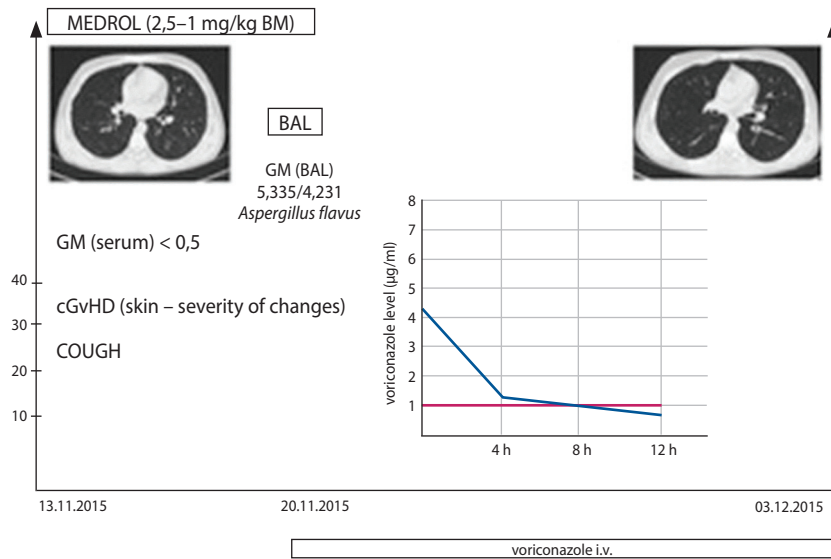
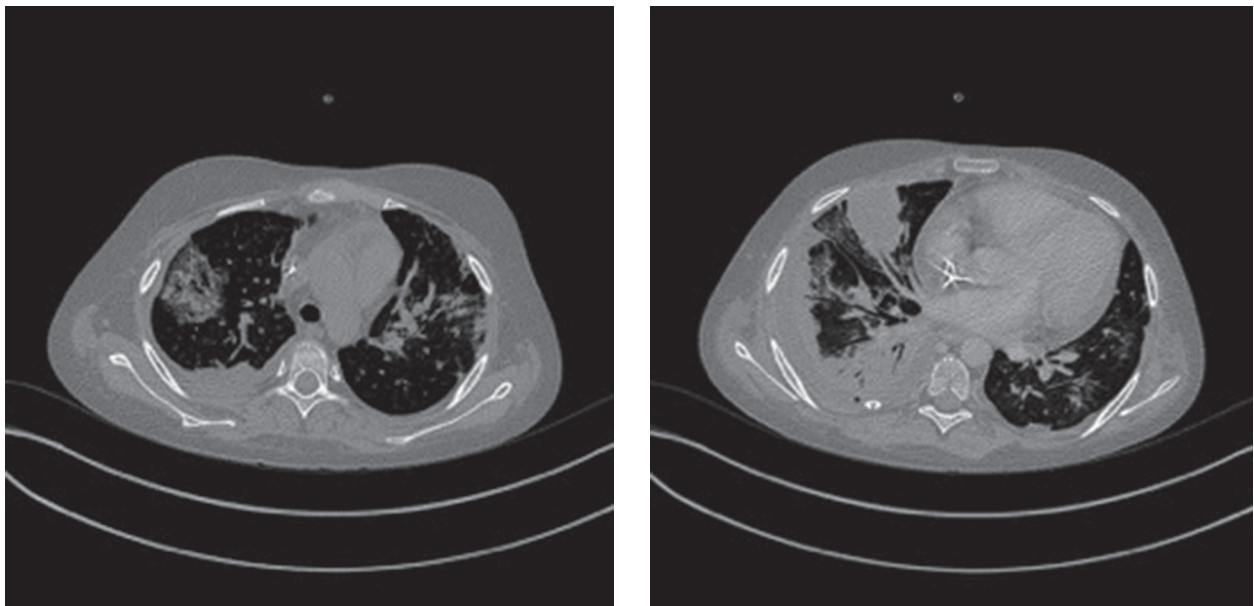


FIGURE 2.
Chest CT revealed diffuse parenchymal densities in both lungs, nodular lesions, inflammatory and atelectatic lesions, and fluid in the right pleural cavity.



Both serum and BAL GM titres were low (< 0.5). The antifungal therapy was modified, with voriconazole and micafungin replaced by the lipid formulation of amphotericin B (ABLCL) at a dose of 5 mg/kg/24 h. Additionally, levels of B and T lymphocytes were found to be significantly decreased, which is why a single donor lymphocyte infusion (DLI) was performed, transfusing 50 000 T lymphocytes/kg of recipient body weight.

The patient's clinical condition gradually improved, and the follow-up chest CT revealed gradual resolution previously reported lesions (fig. 3). ABLCL treatment was continued for 28 days and was subsequently followed by voriconazole administered orally at the dose of 2 × 200 mg/24 h. Management algorithm for that stage of treatment has been presented in figure 4.

FIGURE 3.

The follow-up chest CT revealed significant regression of the previously reported lesions (with the fluid in the right pleural cavity still there).

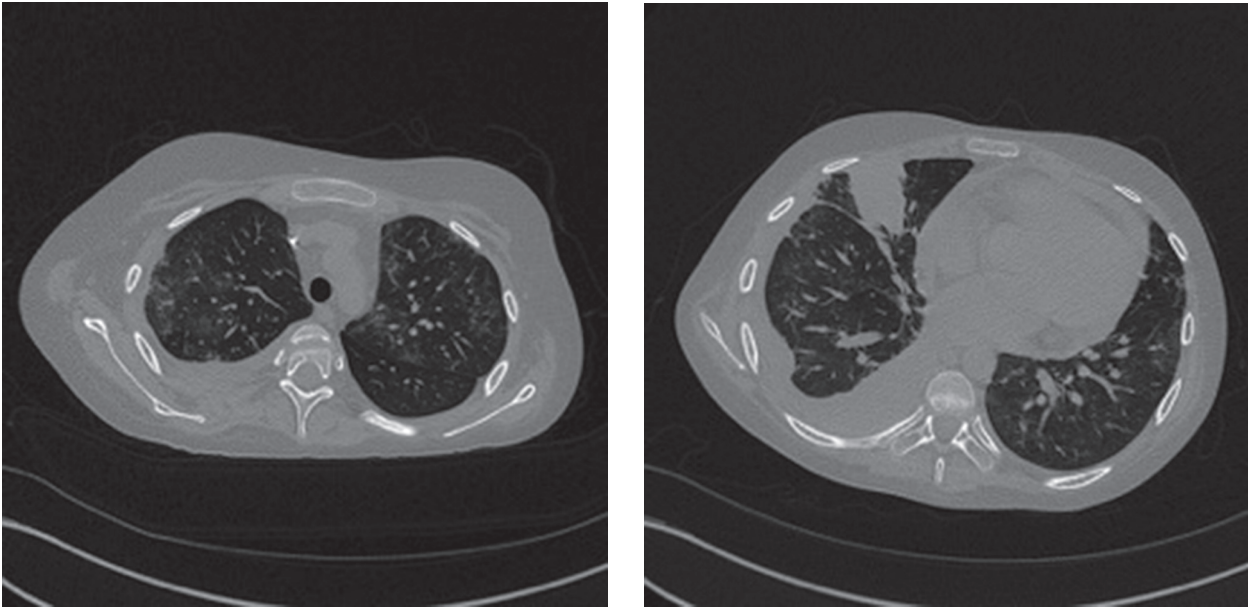
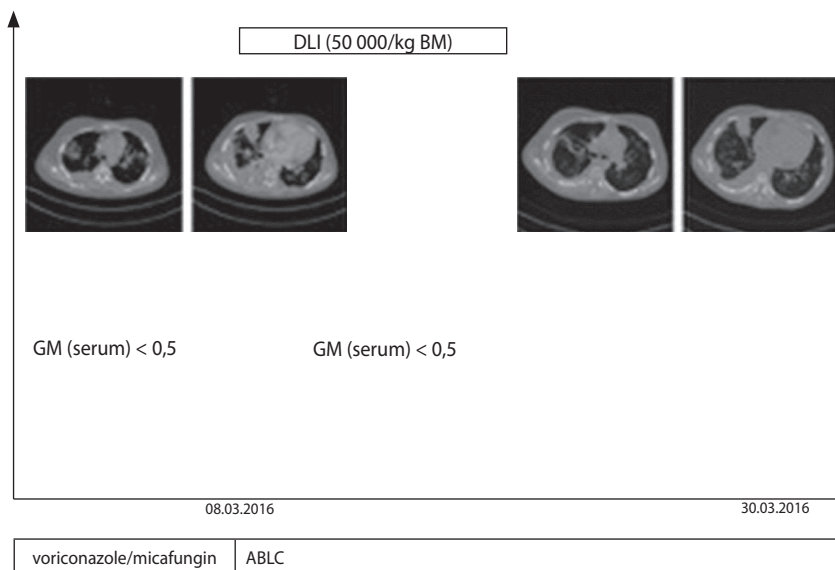


FIGURE 4.

Diagnostic and therapeutic algorithm in recurrent/breakthrough IA.



DISCUSSION

Prolonged neutropenia, transplantation of hematopoietic stem cells, and immunological disturbances associated with the procedure are all significant risk factors for IFI development [2]. Early diagnostics and introduction of a new generation anti-fungal agents, have led to a considerable reduction of mortality related to IA [4]. Another important factor which improves prognosis is IFI prophylaxis in high risk patients. However IFI is

still significant cause of therapeutic failure particular in hematopoietic stem cell recipients [5].

Identification of the potential infection is mostly based on serology and/or imaging tests (*probable fungal infection*), and much less frequently on histopathological or microbiological examination of the material harvested from a previously sterile site (*proven fungal infection*). Despite the fact that international guidelines (e.g. ECIL, ESCMID) on probable or proven fungal in-

fections treatment are quite precise, a disproportionately large number of therapeutic decisions is still taken without identification of the pathogen responsible for the development of IFI [2, 6]. The Department of Paediatrics, Paediatric Haematology and Oncology of the Public Clinical Hospital in Szczecin identified 44 cases of IFI among children with malignancy (0.92 case per patient) in the years 2014–2015. 10 out of 44 (22.7%) were probable fungal infections, 5 (11.4%) were proven fungal infections, and as many as 29 (65.9%) were possible fungal infections. In the last group, the decision on the initiation of antifungal treatment (and indirectly on IFI diagnosis) stemmed from a lack of clinical effect of a broad spectrum antibiotic therapy.

In light of the historical publications on a dramatic increase in mortality along with the delayed initiation of appropriate antifungal treatment, early antifungal therapy (i.e. empirical therapy in most cases) is the only available procedure that significantly reduces mortality in IFI [7, 8].

In author personal view, attempting to identify the species responsible for the infection (or confirming the fact with other methods, including GM, PCR, and β -glucan assays) is attractive, but may delay the decision on treatment initiation which may adversely translate into overall survival in patients with “real” IFI.

In reported case, initial IFI diagnosis was based on the detection of a high galactomannan antigen titre (*probable infection*), macroscopic image of bronchial mucosa, and positive BAL culture (*Aspergillus flavus*). It is worth noting that there were no lesions typical of IA in chest CT. Therefore, invasive tracheobronchial aspergillosis seems to be the most probable diagnosis. On the other hand, lesions detected on chest CT in children are highly atypical (sometimes scarce, most frequently taking the form of subpleural and interstitial nodules) and are significantly different from those reported in adult patients (the halo and air crescent signs, cavitations, etc.) [9, 10]. Voriconazole treatment (recommended in IA), involving dose escalation (by 25%), proved efficacious. It should be emphasised here that therapeutic drug monitoring (TDM) is essential in children since the drug’s pharmacokinetics is significantly different in paediatric patients, and they usually require doses that are higher than the recommended ones in order to achieve the reference concentrations [11]. Once the symptoms of infection resolved, and in light of the necessity to continue glucocorticosteroid therapy (for the chronic GvHD cutaneous exacerbations), it was decided that IFI prophylaxis should be continued with the use of posaconazole. Such management is recommended for high risk patients, with its efficacy pointed out in many papers [12–14].

Irrespective of the prophylactic treatment, though, symptomatic pneumonia developed (preceded by a severe infection, most likely of bacterial aetiology). Despite the low GM titre, chest CT was performed, revealing the presence of infiltrative and nodular lesions, visualized predominantly in the right lung. That clinical picture corresponded best with a breakthrough infection or evolution of the previous bronchial infection into an interstitial one. Second line therapy, including voriconazole and micafungin, was not successful, which is why ABLC therapy was administered, leading to a gradual improvement of the patient’s condition, and to the regression of the interstitial lesions. ECIL guidelines on second line IA treatment recognise all available drugs and combined regimens as equivalent. Some of the earlier concerns related to IFI prophylaxis and its negative impact on the efficacy of second line treatment were dismissed in the work of Pagano et al. [14].

It should be also underline that the DLI procedure was concurrent with the subsidence of the pulmonary lesions and the overall improvement of the patient’s clinical condition. Reconstitution of the immune system by means of (as long as it is possible) reduced intensity of immunosuppressive treatment, transfusions of granulocytes and the use of granulocyte colony stimulating factors, appear to be an equally important elements in IFI management [15–18].

CONCLUSIONS

1. Children following hematopoietic stem cell transplantations are especially exposed to the risk of IFI development.
2. In those high risk groups of patients, prophylaxis appears to be indispensable to minimise the risk of IFI development.
3. Despite the prophylactic treatment, IFI may still develop in the high risk groups, especially during immunosuppressive therapy or in a situation of persisting immunological disturbances.
4. Early modification of the antifungal therapy, based on the broadest spectrum drugs, appears to be necessary to achieve remission in patients who do not respond to first line treatment.
5. Correction of immunological deficits may be crucial for final resolution of infection.

Acknowledgments

Author report no conflict of interest.

References

1. Berman JN, Look T. Pediatric Myeloid Leukemia, Myelodysplasia, and Myeloproliferative Disease. In: Orkin SH, Fisher DE, Ginsburg D et al. (ed.). Nathan and Oski's Hematology and Oncology of Infancy and Childhood. Elsevier Saunders, Philadelphia 2015: 1555-1613.
2. Groll AH, Castagnola E, Cesaro S et al. Fourth European Conference on Infections in Leukaemia (ECIL-4): guidelines for diagnosis, prevention, and treatment of invasive fungal diseases in paediatric patients with cancer or allogeneic haemopoietic stem-cell transplantation. *Lancet Oncol* 2014; 15(8): e327-340.
3. Wattier RL, Dvorak CC, Hoffman JA et al. A Prospective, International Cohort Study of Invasive Mold Infections in Children. *J Pediatric Infect Dis Soc* 2015; 4(4): 313-322.
4. Domenech C, Leick-Courtois C, Bienvenu AL et al. Improvement in the Outcome of Invasive Aspergillosis in a Pediatric Hematology Department: A 10-Year Review. *J Pediatr Hematol Oncol* 2015; 37(7): 560-565.
5. Styczynski J, Czynewski K, Wysocki M et al. Increased risk of infections and infection-related mortality in children undergoing haematopoietic stem cell transplantation compared to conventional anticancer therapy: a multicentre nationwide study. *Clin Microbiol Infect* 2016; 22(2): 179.e1-179.e10.
6. Hope WW, Castagnola E, Groll AH et al. ESCMID guideline for the diagnosis and management of Candida diseases 2012: prevention and management of invasive infections in neonates and children caused by Candida spp. *Clin Microbiol Infect* 2012; 18(suppl 7): 38-52.
7. Chamilos G, Lewis RE, Kontoyannis DP. Delaying amphotericin B-based frontline therapy significantly increases mortality among patients with hematologic malignancy who have zygomycosis. *Clin Infect Dis* 2008; 47(4): 503-509.
8. Morrell M, Fraser VJ, Kollef MH. Delaying the empiric treatment of candida bloodstream infection until positive blood culture results are obtained: a potential risk factor for hospital mortality. *Antimicrob Agents Chemother* 2005; 49(9): 3640-3645.
9. Roilides E, Pana ZD. Application of diagnostic markers to invasive aspergillosis in children. *Ann NY Acad Sci* 2012; 1272: 1-8.
10. Tragiannidis A, Roilides E, Walsh TJ et al. Invasive aspergillosis in children with acquired immunodeficiencies. *Clin Infect Dis* 2012; 54(2): 258-267.
11. Kang HM, Lee HJ, Cho EY et al. The Clinical Significance of Voriconazole Therapeutic Drug Monitoring in Children With Invasive Fungal Infections. *Pediatr Hematol Oncol* 2015; 32(8): 557-567.
12. Cornely OA, Maertens J, Winston DJ et al. Posaconazole vs. fluconazole or itraconazole prophylaxis in patients with neutropenia. *N Engl J Med* 2007; 356(4): 348-359.
13. Döring M, Müller C, Johann PD et al. Analysis of posaconazole as oral antifungal prophylaxis in pediatric patients under 12 years of age following allogeneic stem cell transplantation. *BMC Infect Dis* 2012; 12: 263.
14. Pagano L, Verga L, Busca A et al. Systemic antifungal treatment after posaconazole prophylaxis: results from the SEIFEM 2010-C survey. *J Antimicrob Chemother* 2014; 69(11): 3142-3147.
15. Peng XG, Dong Y, Zhang TT et al. Immune Reconstitution of CD4+T Cells after Allogeneic Hematopoietic Stem Cell Transplantation and its Correlation with Invasive Fungal Infection in Patients with Hematological Malignancies. *Asian Pac J Cancer Prev* 2015; 16(8): 3137-3140.
16. Nikolajeva O, Mijovic A, Hess D et al. Single-donor granulocyte transfusions for improving the outcome of high-risk pediatric patients with known bacterial and fungal infections undergoing stem cell transplantation: a 10-year single-center experience. *Bone Marrow Transplant* 2015; 50(6): 846-849.
17. Kadri SS, Remy KE, Strich JR et al. Role of granulocyte transfusions in invasive fusariosis: systematic review and single-center experience. *Transfusion* 2015; 55(9): 2076-2085.
18. Lehrnbecher T, Kalkum M, Champer J et al. Immunotherapy in invasive fungal infection – focus on invasive aspergillosis. *Curr Pharm Des* 2013; 19(20): 3689-3712.