

Invasive fungal infection in an acute myeloid leukaemia patient

Magdalena Szczepańska, MD, Grzegorz Charliński, MD, PhD

*Haematology Ward, Nicolaus Copernicus Specialist Hospital in Toruń, Poland
Ward Coordinator: Grzegorz Charliński, MD, PhD*

Received: 6.06.2016. Accepted: 8.09.2016.

ABSTRACT

Invasive fungal infections (IFI) are one of the most severe complications of treatment in patients with acute myeloid leukaemia (AML) that are diagnosed during the myelosuppression period following intensive chemotherapy. Due to a high mortality rate reaching up to 30–70%, IFI require an adequate prevention, and once an active infection is diagnosed – a rapid diagnosis and an effective antifungal therapy. Modern therapy models are based on expensive treatment regimens and are often associated with long-term hospitalization and the need for intensive supportive treatment.

KEY WORDS: invasive fungal infections, diagnostic tests, prophylaxis, treatment

Correspondence:

Magdalena Szczepańska, MD

Haematology Ward, Nicolaus Copernicus Specialist Hospital in Toruń

87-100 Toruń, ul. Batorego 17/19

e-mail: magzal@vp.pl

INTRODUCTION

Over the last few decades, the incidence of invasive fungal infections (IFI) in patients with haematologic malignancies has grown considerably [1] which, paradoxically, is the result of progress in medicine. Due to advanced therapies, an increasing number of patients receive intensive cytostatic treatment, radiotherapy and immunosuppression, and we are seeing an improved efficacy of antibacterial treatments [2]. The IFI high-risk group includes a subgroup of patients who undergo intensive haematological treatment, including patients with acute myeloid leukaemia (AML).

The most commonly detected fungal pathogens in humans are *Candida* and *Aspergillus* species. In most cases, yeast infections are of endogenous origin, while mould infections are of exogenous origin. Recently, IFI caused by other types of mould such as *Fusarium spp.*, *Scedosporium spp.* and *Zygomycetes* have been diagnosed most frequently. Infections started by these pathogens are associated with a high mortality rate (only 13–21% patients survive 90 days after the diagnosis) [3]. One of the key reasons for the high mortality in IFI is late diagnosis.

The diagnosis is based on a risk factor analysis, clinical symptoms, as well as mycological analysis and radiologic scans. The criteria related to clinical symptoms involve identification of abnormalities specific for a given site on the basis of imaging studies, and presence of clinical symptoms that cannot be explained otherwise, e.g. persistence of neutropenic fever for more than 96 hours despite implementation of broad-spectrum antibiotics.

A proven IFI diagnosis is when evidence is provided by histopathological analysis of a lesion or a positive result of a culture test based on a material that was collected in a sterile manner.

A probable IFI is diagnosed when at least one of the following criteria are met: patient's condition, presence of fungi and clinical symptoms.

IFI is understood to be **possible** when at least one criterion from two out of the three categories named above are met [4].

Empiric antifungal therapy is implemented when the infection cannot be confirmed in accordance with clinical or microbiological criteria and the neutropenic fever persists for more than 96 hours despite using broad-spectrum antibiotics. According to ECIL-3 (European Conference on Infections in Leukaemia) guidelines, antifungal therapy in AML patients should be based on liposomal amphotericin B and caspofungin [5].

The following is a report on an AML patient diagnosed with IFI in the myelosuppression period triggered by chemotherapy.

CASE REPORT

In April 2015, a male patient aged 53 was diagnosed with RAEB-1 myelodysplastic syndrome (indirect risk – 2). After 6 months of follow-up, the condition progressed to AML. As a result, chemotherapy based on a combination of daunorubicin with cytosine arabinoside was initiated to induce remission. In December 2015, following a complete remission, the patient received treatment based on a combination of cytosine arabinoside in high doses with mitoxantrone (HAM) to consolidate remission. Antifungal treatment was continued throughout both induction and consolidation therapy. It was based on posaconazole at 200 mg/24 h. On the 12 day of chemotherapy (during agranulocytosis, with white blood count (WBC) at 0.23 g/l) the patient developed a fever of 38°C. A physical exam did not show any clinical symptoms of an infection. Culture tests were performed on peripheral blood as well as blood from the central venous catheter. Antibacterial therapy using piperacillin with tazobactam was initiated. Due to persistent fever, presence of abnormal auscultation sounds at the bottom of the lungs and an increase in the level of C-reactive protein (CRP) to 237 mg/l, the patient was switched to different antibiotics: meropenem in combination with amikacin. A thoracic radiological exam did not show any signs of inflammation in the lungs.

The peripheral blood culture grew methicillin-resistant *Staphylococcus aureus* (MRSA), therefore vancomycin was added to the existing medication. Antifungal therapy based on posaconazole was continued. However, broad-spectrum antibiotics did not improve the patient's status. Hectic fever persisted. In addition, the patient experienced dyspnoea with persistent abnormal auscultation sounds over the lung fields. Further cultures of blood and sputum did not grow any microorganisms. Other pathogens, like *Pneumocystis jiroveci*, cytomegalovirus and influenza virus were ruled out. In addition, the patient was initiated on voriconazole. A thoracic high-resolution computed tomography (HRCT) scan showed a picture typical of bilateral fungal pneumonia (fig. 1). An immunoenzymatic test was performed multiple times but did not confirm presence of *Candida* and *Aspergillus spp.* antigens. A galactomannan test was not performed due to technical reasons. A bronchoscopy was not performed, either, due to myelosuppression and thrombocytopenia identified by the CBC as well as limited possibilities available at the treating facility.

FIGURE 1.

Thoracic HRCT scan prior to antifungal treatment (from the authors' collection).

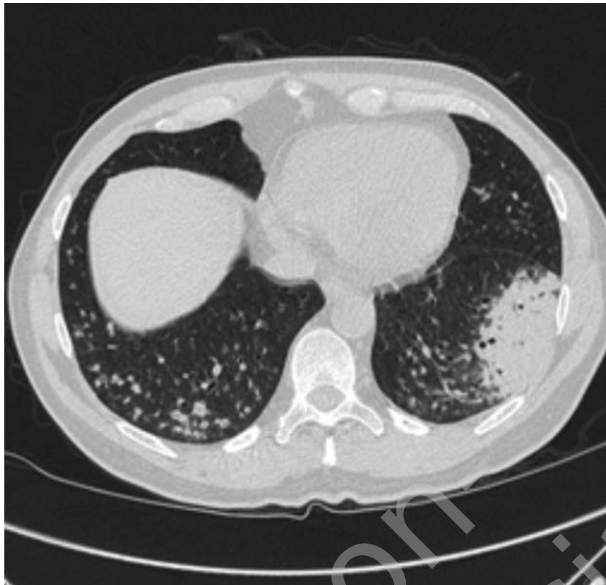
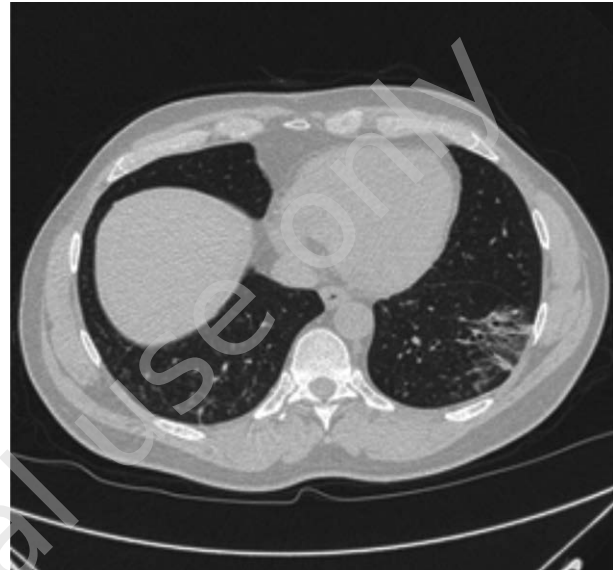

FIGURE 2.

Thoracic HRCT scan after antifungal treatment (from the authors' collection).



Based on the HRCT scan, voriconazole therapy was accompanied by amphotericin B lipid form (persistent fever of up to 39°C and WBC at 0.16 g/l in peripheral blood). The combination therapy was continued for 18 days. On the 11th day of therapy, the body temperature returned to normal levels, with WBC at 0.94 g/l and neutrophil count at 0.53 g/l. Despite that, a follow-up HRCT performed on the 18th day of the combination antifungal treatment showed that the fungal lesions in the lungs seen previously progressed. For this reason, the antifungal therapy used to date was replaced by a combination of voriconazole with caspofungin. The patient tolerated the treatment well and his health status was satisfactory, therefore the therapy was continued for 29 consecutive days. It reduced the inflammatory infiltrations in the lungs by 20%. Given that the therapy was moderately efficacious, a decision was made to replace caspofungin with micafungin. Finally, after 30 days of combination antifungal treatment, the inflammatory lesions evolving towards fibrosis regressed (fig. 2). No inflammation was identified by means of bronchoscopy while a mycologic and galactomannan tests of the bronchoalveolar lavage were negative. Bearing in mind that inflammatory lesions progressed while the patient was receiving voriconazole, the present maintenance therapy is based on itraconazole.

The patient was considered eligible for a hematopoietic stem cell transplantation from a family donor and is currently waiting for the procedure. As a bridging therapy before the scheduled

HSCT, the patient received a single cycle of DA (daunorubicin and cytarabine) chemotherapy to maintain remission. No progression of inflammatory abnormalities was identified during that treatment. In the course of the patient's hospital stay he received itraconazole as antifungal maintenance therapy which he has continued until the present day.

DISCUSSION

The case report shows that IFI are difficult to diagnose and treat. In addition, they have a vital effect on the prognosis, as was the case with the AML patient from the report. On the one hand, the patient needs antifungal treatment while on the other hand he must be treated for his primary disease which is cancer. What is more, persistent IFI may make a patient ineligible for a high-dose therapy which is supported by a hematopoietic stem cell transplantation.

The guidelines on diagnosing and empiric treatment of IFI which are based on risk factors and clinical criteria allow for the use of antifungal agents of all groups, while at the same time highly recommend amphotericin B lipid form and caspofungin. The patient had all the risk factors for IFI due to severe neutropenia persisting for more than 10 days and fever that continued for more than 96 hours despite receiving broad-spectrum antibiotics. The clinical criterion related to specific radiological symptoms shown by a HRCT scan was also met. Microbiolo-

gic analysis relying on the immunoenzymatic method did not reveal fungal antigens. Admittedly, the galactomannan test was not performed for that patient but due to exposure to piperacillin, tazobactam and posaconazole the test result would not have been credible. As a result, a possible IFI was diagnosed which provided basis for initiation of voriconazole, amphotericin B, caspofungin and micafungin. Long-term combination therapy resolved the fungal pneumonia, which made it possible for the patient to receive high-dose chemotherapy to be followed by a hematopoietic stem cell transplantation. This gives the patient a chance to survive AML.

SUMMARY

A report on the diagnostic process and treatment of an AML patient with a possible IFI provides evidence that this condition

is difficult to diagnose due to non-specific clinical symptoms and low sensitivity of diagnostic tests. Undeniably, development of uniform criteria for assessment of progression and response to treatment on the basis of the radiological picture would be helpful.

It seems that apart from the launch of new antifungal agents, the future of IFI therapies may bring about a change in the route of administration, from intravenous to e.g. subcutaneous, oral or through inhalation. This would enable patients to continue treatment at home, which would definitely reduce the cost of therapy.

Acknowledgments

Authors report no conflict of interest.

References

1. Pagano L, Caira M, Candoni A et al. The epidemiology of fungal infections in patients with hematologic malignancies: the SEIFEM – 2004 study. *Haematologica* 2006; 91: 1068-1075.
2. Bhatt VR, Viola GM, Ferrajoli A. Invasive Fungal Infections in Acute Leukemia. *Ther Adv Hematol* 2011; 2(4): 231-247.
3. Leroux S, Ullmann AJ. Management and diagnostic guidelines for fungal diseases in infectious diseases and clinical microbiology: critical appraisal. *Clin Microbiol Infect* 2013; 19(12): 1115-1121.
4. Czyż A. Powikłania infekcyjne w hematologii. *Hematologia* 2016; 1(10): 108-118.
5. Maertens J, Marchetti O, Herbrecht R et al; Third European Conference on Infections in Leukemia: European guidelines for antifungal management in leukaemia and hematopoietic stem cell transplant recipients: summary of the ECIL 3-2009 update. *Bone Marrow Transplant* 2012; 47: 846-854.

Authors' contributions:

Magdalena Szczepańska: 50%
Grzegorz Charliński: 50%