

Sleep apnea and dry eye: how sleep apnea affects the eye surface

Catherina M. Bommert, Christina N. Grupcheva,
Mladena N. Radeva, Dimitar I. Grupchev, Maria R. Boyadzieva

Department of Ophthalmology and Visual Sciences,
Faculty of Medicine, Medical University of Varna, Bulgaria
Head of Department: Prof. Christina Grupcheva, MD, PhD



HIGHLIGHTS

Early identification of dry eye disease and choosing the appropriate treatment is indispensable for preserving ocular and visual function and improving quality of life in patients with obstructive sleep apnea (OSA) and continuous positive airway pressure (CPAP).

ABSTRACT

Purpose: The purpose of this study was to determine the presence of dry eye disease and possible treatment options in patients with obstructive sleep apnea and continuous positive airway pressure.

Materials and methods: A total of 72 patients (midlife age) with obstructive sleep apnea and continuous positive airway pressure therapy underwent a comprehensive eye examination. Fluorescein staining of the anterior ocular surface and tear break-up test were performed. All of the patients who were diagnosed with dry eye disease received personalized therapy. One month later, re-examination was performed using the same methodology and clinical settings.

Results: On the first examination, 48 of 72 patients (66.67%) were diagnosed with dry eye disease. Floppy eyelid syndrome was reported in 26 patients (54.17%) with dry eye disease. The treatment of 40 patients included artificial tear supplements during the day in combination with high-viscosity topical gels before bedtime. In more severe cases (10.42% of all participants), the application of bandage contact lenses for 3 months was necessary. Because of excessive lid laxity, surgical reconstruction of the eyelids was performed in three patients (6.25%).

Conclusions: A multidisciplinary approach is essential for obstructive sleep apnea. Practitioners from different specialties must be well acquainted with risk factors, signs, and symptoms. The early detection of dry eye disease in patients with obstructive sleep apnea and appropriate treatments are important for improving the quality of life in this patient group.

Key words: continuous positive airway pressure, dry eye disease, obstructive sleep apnea

INTRODUCTION

Dry eye disease (DED), is known to be the most commonly occurring ocular surface disorder throughout the world [1] with a worldwide varying prevalence of 5% to 34% [2]. Over the past decades we continuously improved understanding of the pathophysiology of this highly prevalent condition [3]. Although the National Eye Institute (NEI) in 1995 subdivided DED into aqueous-deficient DED and hyperevaporative DED [4], it is worth to consider DED also as a multifactorial disease [5], in which additionally exogenous factors interfere with the microenvironment and affect the homeostasis of the ocular surface.

The ocular surface is continuously lubricated and moisturized by tear secretion to maintain comfort, as well as conjunctival and corneal health and function. The constitution of the lacrimal gland, Meibomian glands, goblet cells and the number of accessory glands secrete the components of the tear film. The presence and quality of each layer is essential for the consistency of the intact and stable tear film. Any disbalance leading to instability of the tear film may result in the dry eye [6].

Damage to the ocular surface with alteration of the ocular surface anatomy, such as in patients with obstructive sleep apnea (OSA) undergoing continuous positive airway pressure therapy have a high potential of developing chronic dry eye with the risk of threatening ocular side defects. Patients with OSA suffer from recurrent partial or complete upper airway obstruction during sleep with recurring airway respiratory tract blockade and reduced air inhalation [7]. Patients with moderate-to-severe OSA essentially require a mask that provides continuous positive airway pressure (CPAP) to prevent upper airway collapse [7, 8]. Most frequent side effects of CPAP treatment may include air leakage [9] with dry mouth and nose [10], irritation or redness of the skin, and ocular irritation secondary to air leakage. Besides ocular surface damage, further ocular manifestations of OSA include floppy eyelid syndrome (FES), glaucoma, nonarteritic anterior ischemic optic neuropathy and central serous retinopathy [11, 12]. Based on these observations in the published literature, an extensive ophthalmic examination should be implemented in patients with confirmed OSA [13].

Accompanying ocular problems are often not seen in connection with continuous positive airway pressure therapy, increasing communication between ophthalmologists and sleep medicine specialists recognizing DED in patients with OSA. Therefore, choosing the optimal treatment is essential in reducing the risk of irreversible ocular complications and vision loss in patients with OSA [14]. Due to the discordance between signs and symptoms of DED [15], cooperation between specialties is crucial for timely diagnosis.

Considering this, our team decided to determine the presence of DED and the possible treatment options in patients with OSA and CPAP.

MATERIALS AND METHODS

This study was carried out in the Department of Ophthalmology and Visual Science of the Medical University of Varna, Bulgaria.

All patients diagnosed with OSA and undergoing CPAP therapy underwent comprehensive eye examination. Eye examination included slit-lamp biomicroscopy with special emphasis on ocular surface health and adnexa, visual acuity using Snellen acuity chart, corneal fluorescein staining and tear break-up time (TBUT).

The diagnostic criteria for the presence of DED was evaluated according to DEWS 2017 [16] and took into consideration the subjective DED symptoms, patients medical history and clinical signs. The OSD questionnaire was used for subjective evaluation. The criteria for DED diagnosis included ocular surface disease index score of ≥ 13 accompanied by at least one of the following objective DED signs with TBUT ≤ 10 s, Schirmer score ≤ 5 mm/5 min and positive fluorescein corneal staining \geq grade 1 [17].

The tear film break-up time test (TBUT) was performed to determine the stability of the tear film and the time required for dry spots to appear on the corneal surface. The fluorescein strip that was carefully wetted with non-preserved saline was administered to the lower conjunctiva and time to the first tear film break-up was assessed. The tear film break-up time test result below 10 s was considered pathological. All patients underwent examination of the eyelid margin to reveal inflammation or any dysfunction of the Meibomian glands.

After evaluating the presence and severity of DED, proper therapy was implemented in all patients with DED. Patients with mild DED were treated with preservative-free lubricating eye drops (based on hyaluronic acid) for day treatment in combination with ophthalmic gel with high viscosity in order to achieve a prolonged contact time for night treatment. Patients with severe ocular surface disorders in DED with corneal erosions required bandage contact lenses. Surgical reconstruction of the eyelids was considered and performed in patients with persistent corneal disorder due to excessive lid laxity. One month after the examination and treatment all affected participants were re-examined and the results were evaluated.

RESULTS

This study included a total of 72 patients with OSA and continuous positive airway pressure therapy. Based on DED diagnostic criteria of the Ocular Surface Disease Index (OSDI) score ≥ 13 and the presence of one or more clinical signs of DED, the overall frequency of occurrence of DED exhibit 48 patients (66.67%) in the study population. Overall, 66.67% of our patients (48 of 72) were found

to have DED. Floppy eyelid syndrome was encountered in 26 (54.17%) of the diagnosed patients with DED.

The treatment method for 40 patients with mild DED included lubricating eye drops during the day in combination with high-viscosity gels before bedtime. After comparison of the results on the second visit both preparations showed similar efficiency. The application of bandage contact lens was indicated for 3 months prospectively in five patients with severe DED with corneal erosions. Due to excessive lid laxity surgical reconstruction of the eyelids was performed in 3 (6.25%) patients.

FIGURE 1

Patients with obstructive sleep apnea and continuous positive airway pressure therapy.

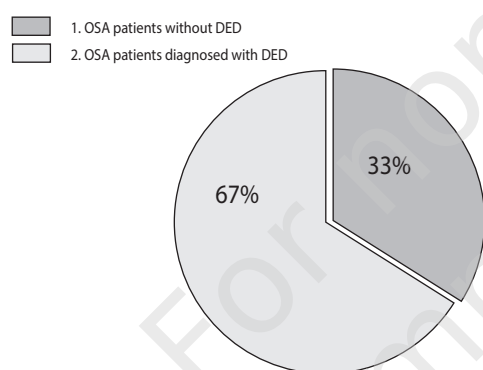
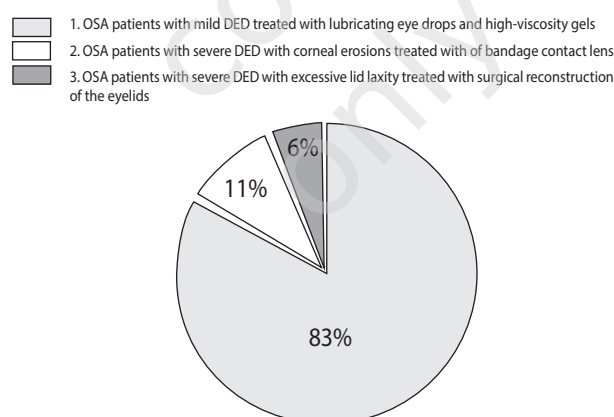


FIGURE 2

Treatment of DED in patients with obstructive sleep apnea and continuous positive airway pressure therapy.



DISCUSSION

Dry eye is a multifactorial disease resulting in discomfort, visual disturbance, and instability of the tear film [16] with variations in clinical presentation, severity, clinical signs as well as in its origin that requires multidisciplinary approach.

Ocular surface damage and the discomfort it causes has a significant bearing on quality of life and restricts daily activities, productivity as well as patients' well-being [18, 19]. The prevalence of DED has been steadily increasing in recent years with contributing factors such as an aging population [20], contact lenses wear [21] and more extensive use of smartphones and computers [22].

Dry eye disease significantly affects the visual function of patients with commonly reported symptoms of ocular discomfort, irritation and blurred vision, foreign-body sensation and reduced contrast sensitivity [18, 23]. Environmental factors like exposure to dry air, cigarette smoke, and dust are known to exacerbate DED [24] as well as the continuous exposure to air leakage from CPAP mask in OSA patients, which is a risk factor that should not be underestimated. Studies recently showed the association of ophthalmic manifestations with OSA, which is characterized by recurrent complete or partial upper airway obstructions during sleep [25].

Patients undergoing CPAP therapy have shown a significantly greater risk for ocular irritation [26] whereby FES appears to be most frequently diagnosed [11].

Highlighted as a multifactorial disease with complex ocular disorders involving diverse findings and symptoms resulting from various origins [27] is important to monitor patients with OSA for possible relating eye manifestations and being aware of the association. Previous studies have reported that early diagnosis of DED has clinical relevance in OSA patients due to greater inclination to develop DED [28, 29]. Identification of patients with ocular injuries is important, as these patients are at increased risk of developing alteration of the ocular surface anatomy and further ocular manifestations of which floppy eyelid syndrome (FES), nonarteritic anterior ischemic optic neuropathy, glaucoma and central serous retinopathy imbed [30, 31].

Dry eye disease emerging from ocular surface injury in OSA by continuous air leakage from the CPAP mask is a common complication and should not be underestimated. The potential of permanent damage of the ocular surface in patients with chronic DED, discomfort and visual loss should not be ignored.

CONCLUSIONS

Examination of ocular surface, early identification of DED and electing the most appropriate treatment regimen in patients with OSA and CPAP is indispensable for preserving ocular and visual function and improving their quality of life. Mindful patient education is essential to increase the awareness of patients with DED as multifactorial disorder, in which good cooperation between treating physician, patient and multiple disciplines is fundamental.

CORRESPONDENCE

Christina N. Grupcheva

Medical University of Varna

55 Marin Drinov Str.

Varna, Bulgaria

e-mail: cgrupcheva@gmail.com

ORCID

Christina N. Grupcheva – ID – <http://orcid.org/0000-0001-9965-1732>

References

1. Zhang X, M VJ, Qu Y et al. Dry Eye Management: Targeting the Ocular Surface Microenvironment. *Int J Mol Sci*. 2017; 18(7). <https://doi.org/10.3390/ijms18071398>.
2. Messmer EM. The pathophysiology, diagnosis, and treatment of dry eye disease. *Dtsch Arztebl Int*. 2015; 112(5): 71-81; quiz 82. <https://doi.org/10.3238/arztebl.2015.0071>.
3. Javadi MA, Feizi S. Dry Eye Syndrome. *J Ophthalmic Vis Res*. 2011; 6(3): 192-8. <https://www.ncbi.nlm.nih.gov/pmc/articles/PMC3306104>.
4. Lemp MA, Foulks GN. The Definition & Classification of Dry Eye Disease Guidelines from the 2007 International Dry Eye Workshop. *Ocul Surf*. 2008. <https://www.tearfilm.org/pdfs/OM-Definition&Classification.pdf>.
5. Report of the International Dry Eye Workshop (DEWS). *Ocul Surf*. 2007; 5(2). www.theocularsurface.com.
6. Holly FJ, Lemp MA. Tear physiology and dry eyes. *Surv Ophthalmol*. 22(2): 69-87. [https://doi.org/10.1016/0039-6257\(77\)90087-x](https://doi.org/10.1016/0039-6257(77)90087-x).
7. Sateia MJ. International Classification of Sleep Disorders-Third Edition. *Chest*. 2014; 146(5): 1387-94. <https://doi.org/10.1378/CHEST.14-0970>.
8. Lévy P, Kohler M, McNicholas WT et al. Obstructive sleep apnoea syndrome. *Nature Reviews Disease Primers*. 2015; 1(1): 15015. <https://doi.org/10.1038/nrdp.2015.15>.
9. Bachour A, Maasilta P. Mouth Breathing Compromises Adherence to Nasal Continuous Positive Airway Pressure Therapy. *Chest*. 2004; 126(4): 1248-54. <https://doi.org/10.1378/chest.126.4.1248>.
10. Pépin JL, Leger P, Veale D. Side Effects of Nasal Continuous Positive Airway Pressure in Sleep Apnea Syndrome. *Chest*. 1995; 107(2): 375-81. <https://doi.org/10.1378/chest.107.2.375>.
11. McNab AA. The eye and sleep apnea. *Sleep Med Rev*. 2007; 11(4): 269-76. <https://doi.org/10.1016/j.smrv.2007.03.006>.
12. Stein JD, Kim DS, Mundy KM et al. The association between glaucomatous and other causes of optic neuropathy and sleep apnea. *Am J Ophthalmol*. 2011; 152(6): 989-98.e3. <https://doi.org/10.1016/j.ajo.2011.04.030>.
13. Morsy NE, Amani BE, Magda AA et al. Prevalence and Predictors of Ocular Complications in Obstructive Sleep Apnea Patients: A Cross-sectional Case-control Study. *Open Resp Med J*. 2019; 13: 19-30. <https://doi.org/10.2174/1874306401913010019>.
14. Arda H, Birer, S Aksu M et al. Obstructive sleep apnoea prevalence in non-arteritic anterior ischaemic optic neuropathy. *Br J Ophthalmol*. 2013; 97(2): 206-9. <https://doi.org/10.1136/bjophthalmol-2012-302598>.
15. Sullivan BD, Crews LA, Messmer EM et al. Correlations between commonly used objective signs and symptoms for the diagnosis of dry eye disease: clinical implications. *Acta Ophthalmol*. 2014; 92(2): 161-6. <https://doi.org/10.1111/aos.12012>.
16. Craig JP, Nichols KK, Akpek EK et al. TFOS DEWS II Definition and Classification Report. *Ocul Surf*. 2017; 15(3): 276-83. <https://doi.org/10.1016/j.jtos.2017.05.008>.
17. Hashemi H, Khabazkhoob M, Kheirkhah A et al. Prevalence of dry eye syndrome in an adult population. *Clin Exp Ophthalmol*. 2014; 42(3): 242-8. <https://doi.org/10.1111/ceo.12183>.
18. Mertzanis P, Abetz L, Rajagopalan K et al. The relative burden of dry eye in patients' lives: comparisons to a U.S. normative sample. *Invest Ophthalmol Vis Sci*. 2005; 46(1): 46-50. <https://doi.org/10.1167/iovs.03-0915>.
19. Friedman NJ. Impact of dry eye disease and treatment on quality of life. *Curr Opin Ophthalmol*. 2010; 21(4): 1. <https://doi.org/10.1097/ICU.0b013e32833a8c15>.
20. Moss SE, Klein R, Klein BEK. Prevalence of and Risk Factors for Dry Eye Syndrome. *Arch Ophthalmol*. 2000; 118(9): 1264. <https://doi.org/10.1001/archophth.118.9.1264>.
21. Pritchard N, Fonn D, Brazeau D. Discontinuation of contact lens wear: a survey. *Int Contact Lens Clin*. 1999; 26(6): 157-62. [https://doi.org/10.1016/s0892-8967\(01\)00040-2](https://doi.org/10.1016/s0892-8967(01)00040-2).
22. Akkaya S, Atakan T, Acikalin B et al. Effects of long-term computer use on eye dryness. *North Clin Istanb*. 2018; 5(4): 319-22. <https://doi.org/10.14744/nci.2017.54036>.
23. Rolando M, Lester M, Macrí A et al. Low Spatial-Contrast Sensitivity in Dry Eyes. *Cornea*. 1998; 17(4): 376. <https://doi.org/10.1097/00003226-199807000-00006>.
24. Alves M, Novaes P, Morraye M de A et al. Is dry eye an environmental disease? *Arq Bras Oftalmol*. 2014; 77(3): 193-200. <https://doi.org/10.5935/0004-2749.20140050>.
25. Santos M, Hofmann RJ. Ocular Manifestations of Obstructive Sleep Apnea. *J Clin Sleep Med*. 2017; 13(11): 1345-8. <https://doi.org/10.5664/JCSM.6812>.

26. Hayirci E, Yagci A, Palamar M et al. The Effect of Continuous Positive Airway Pressure Treatment for Obstructive Sleep Apnea Syndrome on the Ocular Surface. *Cornea*. 2012; 31(6): 604-8. <https://doi.org/10.1097/ICO.0b013e31824a2040>.
27. Şimşek C, Doğru, M, Kojima T et al. Current Management and Treatment of Dry Eye Disease. *Turk J Ophthalmol*. 2018; 48(6): 309. <https://doi.org/10.4274/TJO.69320>.
28. Karaca EE, Akçam HT, Uzun F et al. Evaluation of Ocular Surface Health in Patients with Obstructive Sleep Apnea Syndrome. *Turk J Ophthalmol*. 2016; 46(3): 104. <https://doi.org/10.4274/TJO.57778>
29. Acar M, Firat H, Acar U et al. Ocular surface assessment in patients with obstructive sleep apnea-hypopnea syndrome. *Sleep Breath*. 2013; 17(2): 583-8. <https://doi.org/10.1007/s11325-012-0724-0>.
30. Huon LK, Liu SYC, Camacho M et al. The association between ophthalmologic diseases and obstructive sleep apnea: a systematic review and meta-analysis. *Sleep Breath*. 2016; 20(4): 1145-54. <https://doi.org/10.1007/s11325-016-1358-4>.
31. Dhillon S, Shapirpo CM, Flanagan J. Sleep-disordered breathing and effects on ocular health. *Can J Ophthalmol*. 2007; 42(2): 238-43. https://doi.org/10.3129/can_j_opthalmol.i07-029.

Wkład autorów:

Wszyscy autorzy mają taki sam wkład w opracowanie idei i konstrukcji artykułu, zebranie danych klinicznych, ich analizę oraz przygotowanie manuskryptu.

Konflikt interesów:

Nie występuje.

Finansowanie:

Nie występuje.

Etyka:

Treści przedstawione w artykule są zgodne z zasadami Deklaracji Helsińskiej, dyrektywami EU oraz ujednoliconymi wymaganiami dla czasopism biomedycznych.

Authors' contributions:

All authors have equal contribution to the paper and research behind.

Conflict of interest:

None.

Financial support:

None.

Ethics:

The content presented in the article complies with the principles of the Helsinki Declaration, EU directives and harmonized requirements for biomedical journals.