

Ocular myasthenia – symptoms, diagnostics, treatment

Emilia Nowowiejska¹, Radosław Różycki²

¹ Department of Ophthalmology, Provincial Hospital, Skierniewice, Poland
Head of Department: Edyta Zielińska, MD, PhD

² Department of Ophthalmology, Military Institute of Aviation Medicine, Warsaw, Poland
Head of Department: Radosław Różycki, MD, PhD



HIGHLIGHTS

The distinction between ptosis associated with myasthenia gravis and ptosis associated with other aetiologies is essential for successful therapeutic management.

ABSTRACT

Myasthenia gravis (MG) is an autoimmune disease in which antibodies are damaging receptors of the neuromuscular junction. One of its main symptoms is ptosis, term that refers to the drooping of the eyelid that may lead to a reduction of the vision field and the compensatory chin-up position.

Contrary to sensile (involutional) ptosis, in which surgical treatment is a method of choice, in case of ptosis with myasthenic aetiology, pharmacotherapy is recommended and surgery is relatively contraindicated.

Surgical procedures are rarely performed, only in the case of stable ptosis and ineffectiveness of pharmacotherapy. Since the majority of isolated drooping eyelids of a different aetiology can be successfully surgically corrected, ruling out the diagnosis of myasthenia gravis is essential before deciding on appropriate treatment.

Key words: myasthenia gravis, ocular myasthenia gravis, ptosis, drooping eyelid, diplopia

INTRODUCTION

Myasthenia gravis (MG) is an autoimmune disease in which autoantibodies are damaging receptors of the neuromuscular junction. It can be a cause of an impairment of the neuromuscular conduction resulting in weakening and weariness in certain groups of skeletal muscles – mostly extra-ocular, bulbar and limb muscles. 90% of patients with confirmed MG are suffering from ophthalmological symptoms. With that being said, those symptoms are the first ones to be noticed and are the reason for searching for a medical examination in 60% of cases. The levator palpebrae superioris (the muscle that elevates the upper eyelid) and extra-ocular muscles are particularly susceptible to damage when developing MG. For that reason, it is recommended to consider this disease when running diagnostics in every case of droopy eyelids, as well as nonspecific eye movement disorders and manifesting double vision.

THE EPIDEMIOLOGY OF MYASTHENIA GRAVIS

The occurrence of MG in world's population is estimated at circa 0.04–5/100,000 a year. In Poland, the intensity is assessed to be from 15 to 1,900 cases a year. The first symptoms can develop in every age group. However, it has been assessed that, it is most likely for them to transpire in the third decade of humans' life. It is very rare for these symptoms to develop in patients under 10 years old and above 70 years old. MG cases in adolescents and children are relatively rare. In addition, around 10–15% of babies born to mothers with MG may have its temporary form. This occurs when antibodies are passively crossing from mother to the foetus through the placenta. The ratio between women and men developing MG is 3 : 2; however, men tend to have greater predilection to present symptoms of ocular MG. Six thousand people are confirmed to suffer from myasthenia gravis in Poland.

PATHOPHYSIOLOGY AND CLINICAL PICTURE

Myasthenia is an auto-aggressive disease aimed against cholinergic receptors of skeletal muscles. Immunological researches are certifying the presence of IgG class of antibodies, targeting the acetylcholine receptors (AChRabs) in 85% of cases of generalised myasthenia gravis. In addition, about 10% of cases without AChRabs antibodies are confirmed to develop IgG antibodies against muscle-specific kinase tyrosine (MuSK). Existence of antibodies against contractile units of skeletal muscles (titin) and against low-density lipoprotein receptor-related protein type 4 (LRP4) is also characteristic in MG cases. At present, there is no confirmed correlation between the existence of antibodies and the intensity of symptoms. Moreover, the quan-

tity of antibodies showing after the treatment is not a sign of getting better – in 15% of cases with generalised MG the immunological tests show no presence of any specific antibodies at all.

It is worth mentioning that patients with MG tend to develop other autoimmune diseases, like thyroid diseases, rheumatoid arthritis, systemic lupus erythematosus, multiple sclerosis, more frequently than other patients. What is more, people with AChRabs-seropositive generalised myasthenia are disposed to have remaining thymus and 10–15% of those cases are diagnosed with thymoma. In addition, those cases are more likely to have positive anti-titin antibodies and generally speaking, the whole course of the disease is more dynamic. It should be mentioned that, there is a slim chance of diagnosing thymoma in cases with positive anti-MuSK antibodies, as well as the fact that in other cases there was no proven coexistence between being positive with anti-LRP4 and developing the tumour.

The heterogenic clinical picture is yet another hallmark of MG. Symptoms consistency depends on several factors i.e. the time of the day, one's activity and the general state of health. Some factors like infection, physical and psychological stress, fever, menstruation, pregnancy, usage of certain drugs and hormonal imbalance (resulting from thyroid diseases) can lead to patient deterioration. On the other hand, symptoms can be alleviated by resting and getting enough sleep. Considering all of the above, it is difficult to schedule a long-term treatment plan and it is not unusual to adjust it in the course of therapy following medical advice. When the clinical image of the disease consists only of isolated ophthalmological symptoms then it is qualified as ocular myasthenia. In more than half of cases, from appearance of the first ocular symptoms, it can take several days to 2 years for ocular myasthenia to degenerate into its generalised form. The bulbar muscles are affected that results in difficulties making facial expressions, drooping of jaw muscles, speech disorders, problems with chewing and difficulties with swallowing. Fluctuating muscle weakness is often the reason for development of myopathic face resulting in an expressionless facial appearance. MG can spread to upper and lower limbs, especially arm muscles, proximal leg muscles, neck and in some cases respiratory muscles which can manifest in shortness of breath on exertion. The myasthenic crisis takes place when a patient is in an advanced stage of the MG, general symptoms are intensifying, and acute respiratory failure is occurring. It is a life-threatening state, which often calls for intubation and mechanical ventilation. About 20% of patients are experiencing myasthenic crisis, despite many years of research, medical practice and the whole arsenal of scientifically proven medication.

OCULAR MYASTHENIA

90% of patients with confirmed MG are suffering from ophthalmological symptoms. These symptoms are the first ones to be noticed and are the reason to seek a medical examination in 60% of cases. Only in 15% of cases patients have solely ocular symptoms, in the great majority the disease deteriorates into generalised myasthenia.

Ocular muscles affected by MG can be divided into three groups depending on their function: the levator palpebrae superioris (muscle that elevates the upper eyelid), the extra-ocular muscles (muscles responsible for eye movement) and lastly, the group of muscles that help with the closing of the eyelids, orbicularis oculi. These muscles weakening can lead to symptoms such as ptosis, diplopia and dry eyes. The latter is the rarest of the three, more likely to occur in advanced stages of MG.

In cases with general weakness of the skeletal muscles, without ophthalmological symptoms, the likelihood of diagnosing myasthenia is low.

Ptosis

Ptosis is the most frequent ophthalmological symptom of MG, associated with elevated muscle fatigue of the levator palpebrae superioris (fig. 1, 2). Drooping of the eyelids can affect one or both eyes – it is often asymmetrical. The intensity of ptosis often varies over time. It is not unusual for it to withdraw from one eye in order to affect the other. It was scientifically proven that the intensity of symptoms for seronegative MG patients is less variable over time than those with positive AChRs and MuSK antibodies.

FIGURE 1

Ptosis with compensatory chin-up position.

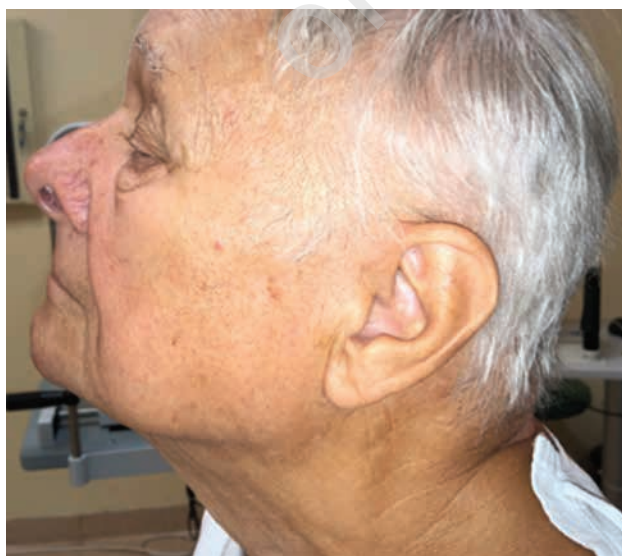
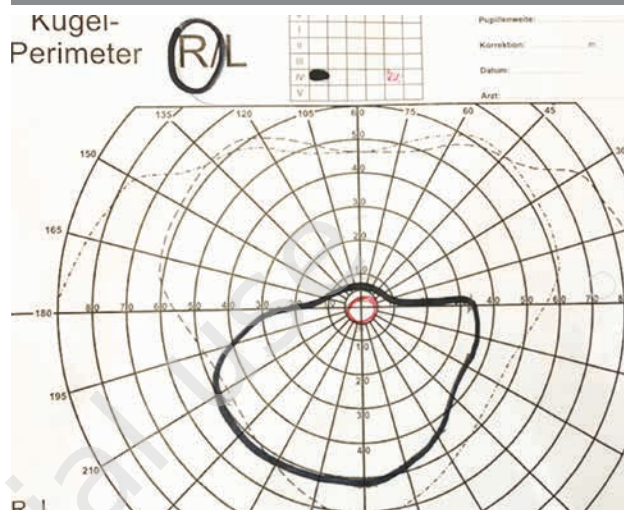


FIGURE 2

Droop of upper eyelid narrowing the vision field.



Generally, symptoms are getting worse at the end of the day and reducing or resolving after awakening. It is typical for ptosis to intensify from prolonged upward gaze during eye examination. Another distinctive symptom would be Cogan's lid twitch which consists of a brief twitch upwards of the eyelid following a sudden return of the eyes to primary position after a period of down-gazing (for a minimum of 15 s). Cogan's lid twitch is common but not pathognomonic for myasthenia. In cases of the upper eyelid drooping on one side, contralateral ptosis causing a pseudo eyelid retraction caused by Hering's law is sometimes noticeable. For the same reason, manual elevation of the ptotic eyelid decreases the muscle strength required to keep the lid elevated, so the contralateral levator palpebrae superioris relaxes and causes ptosis to aggravate.

All of the above characteristic traits of ptosis in MG cases are highly valuable when differentiating drooping of the upper eyelid with different aetiology.

Diplopia

Diplopia is yet another very frequent symptom of MG. In $\frac{2}{3}$ of cases it occurs simultaneously with ptosis. The reason behind the exceptional tendency of extra-ocular muscles to early damage from MG could be found in the difference in structure of the muscle fibres and neuromuscular junctions. Among the dissimilarities between this particular muscles area and skeletal muscles, e.g. limb muscles, the extra-ocular muscles are distinctive for: lower innervation ratio (one axon innervates significantly fewer nerve fibres), decreased number of postsynaptic acetylcholine receptors (AChRs), increased density of ryanodine receptors in sarcoplasmic

reticulum, characteristic structure of muscle fibre with high diversity of myosin heavy chain isoforms (with the majority of type IIa fast myosin heavy chain isoforms). Those features translate to higher contraction rates and in generating less strength comparing to skeletal muscles, which results in high precision movements and allows them to stay on standby for most of the time. All of the above could be explained by the head paraxial mesoderm origin of extra-ocular muscles, whereas skeletal muscles are derived from segmented mesoderm.

The vast majority of patients are showing horizontal and vertical diplopia symptoms simultaneously. Statistically speaking, the first muscle to show fatigue is the medial rectus, with superior rectus being the close second. Diplopia, as well as drooping of the upper eyelid, has a changeable character. It is not unusual for patients manifesting diplopia when gazing to the one side during their first medical examination, to display the symptoms when gazing to the opposite site with consecutive visits. For that reason, it is crucial to check the eye movement in every direction during each examination. It is recommended to observe the muscle fatigue of the patient resulting from their exhaustion, rather than decreased function of the muscles itself. Some patients exhibit pseudo-internuclear ophthalmoplegia or eye movements resembling to nystagmus when gazing in an extreme lateral position.

DRY EYE DISORDER

The orbicularis oculi muscle fatigue can be the cause of a decrease in blinking, lid lag and lower lid retraction. All the above results in the appearance of typical symptoms for the exposure keratopathy such as: burning, foreign body sensation, pain and eye redness. The dryness of conjunctive and cornea epithelium that patients develop in inferior quadrant is caused by rare and incomplete eyelid blinks. If that is the case, the incomplete eyelid closure causes insufficient distribution of the tear film and develops in disease of the whole ocular surface. The disease is usually a mild condition to treat. The treatment involves lubricating of the cornea with eye drops and seems to be sufficient in most of the cases.

THE DIAGNOSTICS PROCESS

Comprehensive gathering of the medical history, thorough physical examination and numerous expert examinations are paramount when determining a right diagnosis and starting the proper treatment. The differential diagnosis in myasthenia has a broad spectrum of the disease entities: genetic predispositions, inflammatory, post-traumatic, caused by nerve paralysis, demyelination and others, manifesting ophthalmological symptoms such as ptosis or ambiguous disorders of ocular rotations.

Additional examinations

Identification of antibodies

It is recommended to run tests to detect and measure the level of anti-AChR antibodies in every patient with suspected MG diagnosis. This examination has 70–95% sensitivity for generalised MG and 50–75% for its ocular form. The positive result confirms the diagnosis (with 100% specificity), and the negative result is not a reason to rule out MG – it is an indication for detection and measurement of the other specific antibodies.

Around 10% of cases without AChRAbs antibodies, have MuSK antibodies, distinctive for muscles kinase tyrosine. Examinations for antibodies against titin or anti-LRP4 are performed less frequently.

The edrophonium test

Edrophonium is an acetylcholinesterase inhibitor that has a rapid onset and a rather short duration. It has the function of competitive prevention of acetylcholinesterase in neuromuscular junction which increases level of acetylcholine and maximises its saturation in the receptors. The purpose of this test is to identify a temporary decrease of the symptoms such as ptosis and diplopia after intravenous administration of the medicine. To obtain an objective evaluation it is recommended to document the symptoms by photographing them, getting the exact measurement of the ptosis and the extent of eye movements before the injection. The test dose of edrophonium is 1–2 mg. The result is visible after around 30–60 s and lasts for 5–10 min. Whenever a patient does not show idiosyncratic reaction, it is acceptable to inject another 3–4 mg after 2 min. After noticing distinctive improvement, the test is terminated promptly. If in 60 s after the injection there is no reaction to it, it is advised to administer another dose of 8–9 mg.

In order to minimise the risk of experiencing side effects of edrophonium, prophylactic intravenous administration of 0.3 mg of atropine is suggested. The side effects of muscarinic receptors hyperactivity frequently include; lacrimation, increased salivation, hyperhidrosis and excessive intestinal contractility. Occasionally, patients can experience; bradycardia, bronchospasm, hypotension and fainting. For that reason, it is not recommended to run this particular test when the patient is elderly, especially having a history of bronchial asthma or heart diseases. This examination has 88% sensitivity rate for generalised and 92% for ocular MG type.

The Ice Pack Test

A bag of ice is applied to the surroundings of the affected eyelid (or other concerned muscle) for approximately 2 min. A low temperature decreases the activity of acetylcholinesterase and thereby increases the level of acetylcholine in neuromuscular junction. MG can be diagnosed

when a significant decrease of ptosis is observed directly after removing the ice pack. This examination has 77–89% sensitivity and high ratio of specificity of around 98–100%.

The Sleeping Test

Another way of diagnosing MG is observing the moderation of ptosis or eye movement disorders after 30-minute nap and recurrence of symptoms after 30 s to a 5-minute period after resumption of muscle activity.

The electromyography

Electromyography (EMG) with repetitive nerve stimulation (RNS) it is an electrodiagnostic MG test which measures the amplitude of muscle responses to the electrical stimulation of corresponding peripheral nerve. A decremental response on low frequency stimulation at the rate of 3–5 Hz matches muscle fatigue and weakness in patients with MG. In generalised type of MG, the test result is positive for around 80% of cases, whereas in ocular MG it is around 30–50%. This method is not useful when distinguishing MG from Lambert-Eaton myasthenic syndrome, as the late decrement pattern in both disorders is comparable.

Single-fibre electromyography (SFEMG) is one of the most highly sensitive and helpful tests when diagnosing MG. Carrying it out is always worth considering when there is suspected impaired neuromuscular transmission and the result of the repetitive nerve stimulation test is negative. To confirm MG diagnosis, it is necessary to assess the abnormal variation in time between consecutive electrical discharges within single motor unit potentials. The examination has 99% sensitivity rate for generalised and 80 % for ocular MG type.

Imaging examinations

It is crucial to run chest imaging examinations, such as CT, MRI or PET-CT scan, for every patient with suspected MG, in order to identify an abnormal thymus gland (confirmed in around 70% of MG cases) or a thymus gland tumour (10% of cases).

Other methods of diagnosing

It is worth to consider running further examinations for evaluation of thyroid functions, as around 4–5% of MG patients are confirmed with autoimmune diseases of this gland.

TREATMENT STRATEGIES FOR MG

Depending on the severity of clinical symptoms, presence of thymus disorders, patients' age and coexistence of the other conditions, a treatment strategy should be picked individually for every MG patient.

Acetylcholinesterase inhibitors

This group of medications is always the first one to try when treating myasthenia. It is a symptomatic treatment which puts the breakdown of acetylcholine to an end, improving transmission in motor end plates. Pyridostigmine and ambenonium in oral tablets are the only two drugs of that type available in Poland. The choice of medicine is individual. Due to frequent occurrence of cholinergic side effects, it is crucial to determine a safe, well-tolerated, but also effective, drug dose for every patient.

Immunosuppressive drugs

Immunosuppressive treatment is introduced when symptomatic treatment has no visible effect or patients show low tolerance on their side effects. The first drugs to try in immunosuppressive therapy are glucocorticoids. Prednisone is the most frequently used in Poland. Recommended doses for ocular type myasthenia are usually smaller than in the generalised type. In addition, the use of glucocorticoids has a positive impact on slowing down the generalisation of the symptoms of myasthenia and conversion of ocular type to generalised type of MG.

The alternative medications for patients with contradictory effects on long-term glucocorticoids therapy are; azathioprine, cyclosporine type A, cyclophosphamide, methotrexate, mycophenolate mofetil.

Immunomodulators

Generalised MG type patients dealing with myasthenic crisis are frequently treated with immunomodulators. In this therapy hospitalisation of the patient is necessary. The treatment consists of intravenous application of immunoglobulins (IV Ig) or plasmapheresis.

Even though, this form of treatment has rapid effects, it is not recommended as a long-term therapy, due to improvement being only temporary.

Thymectomy

In the case of thymoma being diagnosed when running imaging examinations, patients are rushed into thymectomy procedure. When thymoma is not diagnosed, the surgery of removing the thymus is an elective type of procedure.

Moreover, use of some medications is not recommended, or even contraindicated, when dealing with MG. This group involves; neuromuscular blocking agents, some groups of antibiotics (amino-glycosides, fluoroquinolones, ketolides, macrolides), some β -blockers, quinidine, procainamide, chloroquine, hydroxychloroquine, penicillamine and many others. Ill-advised usage of the medications above, can have a significant negative effect on the course of myasthenia.

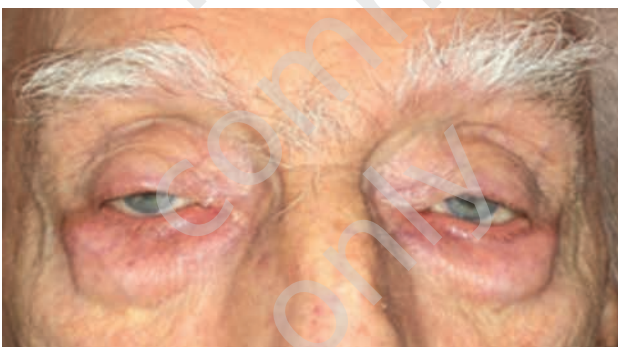
Treatment of ocular myasthenia

Patients with type-specific ocular myasthenia are rarely responding to symptomatic treatment with acetylcholinesterase inhibitors. For that reason, if the patient is experiencing persistent diplopia or ptosis, it is worth beginning glucocorticoids therapy.

Usually, patients react well to prednisone in 5–20 mg/24 h dose. It is also worth considering adding other immunosuppressive medications if a dose of 20 mg/24 h is not sufficient for therapy to be successful. Immunomodulators are used only in extremely severe cases. The thymectomy procedure is usually not very effective in ocular myasthenia. Alternatively, in patients with short-term diplopia which are elderly, unemployed or willing to put up with some inconvenience, non-pharmacological treatment can be considered, which consists of temporarily blocking the vision in one eye. Non-pharmacological help for patients experiencing ptosis, such as mechanical supports for eyelids attached to eyeglasses, are also available. As a last resort, when medications are not effective and the patient is not accepting suggested alternatives to cope with persistent ptosis, surgical procedure should be considered.

FIGURE 3

Ptosis with compensatory chin-up position.



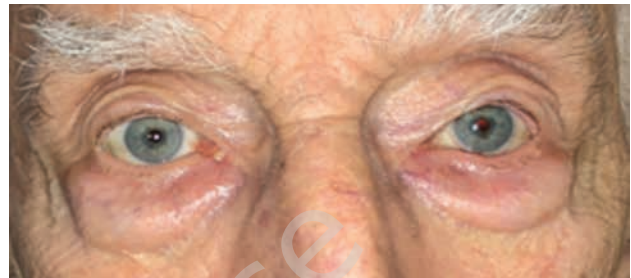
CORRESPONDENCE

Emilia Nowowiejska, MD

Department of Ophthalmology, Provincial Hospital,
Skierniewice, Poland
96-100 Skierniewice, Rybickiego 1
e-mail: enowowiejska@gmail.com

FIGURE 4

Ptosis after eyelid elevation surgery.



Documenting of long-standing stability in the course of myasthenia, at least for the period of 6 months, is mandatory for patients willing to proceed with surgery. The recommended procedure is frontalis suspension. Its aim is to achieve comfortable vision by lifting the upper eyelids above the level of the optic axis.

In patients dealing with eye movement disorders, the injection of botulinum toxin can be considered. In extreme cases, performing a surgery on extra-ocular muscles should be taken into consideration, provided that the disorder deviation is stable.

CONCLUSION

There are multiple diseases with persisting ophthalmic symptoms occurring along with general symptoms. In the case of myasthenia gravis, ophthalmic symptoms are very often first and the only ones that a patient would complain about. Whenever ptosis or diplopia are the only symptoms present in a clinical picture, it is extremely easy to misdiagnose when basing judgment only on superficial examination. Therefore, it is paramount, that the deceptive scarcity of symptoms and what it might seem like an obvious first diagnosis would not lull into false sense of security and would not lead into undertaking poor therapeutic decisions.

Figures: from the author's own materials.

ORCID

Emilia Nowowiejska – ID – <https://orcid.org/0000-0001-5525-6941>
Radosław Różycki – ID – <https://orcid.org/0000-0001-7040-026X>

References

1. Bowling B. Kanski's Clinical Approach, 8th ed. Edra Urban & Partner, Wrocław 2017: 41-5.
2. Nair AG, Patil-Chhablani P, Venkatramani D et al. Ocular myasthenia gravis: A review. Indian J Ophthalmol. 2014; 62(10): 985-91.
3. Mainak B, Hansa D, Debopam S. Neonatal myasthenia gravis. StatPearls [Internet]. 2020.

4. Kostera-Pruszczyk A. Postępowanie terapeutyczne w miastonii. *Pol Przegl Neurol.* 2013; 9(1): 11-5.
5. Kupersmith MJ, Latkany R, Homel P. Development of generalized disease at 2 years in patients with ocular miastenia gravis. *Arch Neurol.* 2003; 60: 243-8.
6. Sathasivam S. Diagnosis and management of myasthenia gravis. *Prog Neurol Psychiatry.* 2014: 6-14.
7. De Meel RHP, Raadsheer WF, van Zwet EW et al. Ocular Weakness in Myasthenia Gravis: Changes in Affected Muscles are a Distinct Clinical Feature. *J Neuromuscul Dis.* 2019; 6(3): 369-76.
8. Majerczak J, Żołędź JA, Duda K. Charakterystyka strukturalna, biochemiczna i funkcjonalna mięśni zewnętrznych gałki ocznej. *Postępy Biologii Komórki.* 2005; 32(3): 395-408.
9. Meriggioli MN, Sanders DB. Autoimmune myasthenia gravis emerging clinical and biological heterogeneity. *Lancet Neurol.* 2009; 8(5): 475-90.
10. Trobe JD. Szybkie rozpoznanie w okulistyce. *Neurookulistyka.* Elsevier Urban & Partner, Wrocław 2011: 104-6.
11. Emeryk-Szajewska B. Elektrofizjologiczna diagnostyka obwodowego układu nerwowego w zespołach paranowotworowych. *Pol Przegl Neurol.* 2008; 4(4): 190-8.
12. Monsul NT, Patwa HS, Knorr AM et al. The effects of prednisone on the progression from ocular to generalized myasthenia gravis. *J Neurol Sci.* 2004; 217: 131-3.

Wkład autorów:

Emilia Nowowiejska: 50%; Radosław Różycki: 50%.

Konflikt interesów:

Nie występuje.

Finansowanie:

Nie występuje.

Etyka:

Treści przedstawione w artykule są zgodne z zasadami Deklaracji Helsińskiej, dyrektywami EU oraz ujednoliconymi wymaganiami dla czasopism biomedycznych.

Authors' contributions:

Emilia Nowowiejska: 50%; Radosław Różycki: 50%.

Conflict of interest:

None.

Financial support:

None.

Ethics:

The content presented in the article complies with the principles of the Helsinki Declaration, EU directives and harmonized requirements for biomedical journals.