

Pediatric cataract surgery – indications for surgery, treatment techniques and postoperative procedures

Marek E. Prost

Department of Ophthalmology, Military Institute of Aviation Medicine, Warsaw, Poland

Head Department: Radosław Różycki, MD, PhD

Center for Pediatric Ophthalmology, Warsaw, Poland

Head Center: Ewa Oleszczyńska-Prost, MD, PhD



HIGHLIGHTS

Surgical procedures should be performed in infants over 2nd month of life due to the more frequent occurrence of glaucoma in earlier operated patients. It is also not recommended to implant intraocular lenses in infants under 7th month of life.

ABSTRACT

Currently, surgery methods of pediatric cataracts allow obtaining good visual acuity in operated children. The operation should be performed in infants over 2 months of age because of more frequent occurrence of glaucoma in earlier operated patients. In children under 10 years of age posterior capsulotomy and anterior vitrectomy are required during surgery to prevent opacification of the posterior lens capsule after surgery. Due to the frequent occurrence of opacities in the visual axis, it is recommended not to implant intraocular lenses in infants under 7th month of life (2nd year of life according to some recommendations).

Key words:

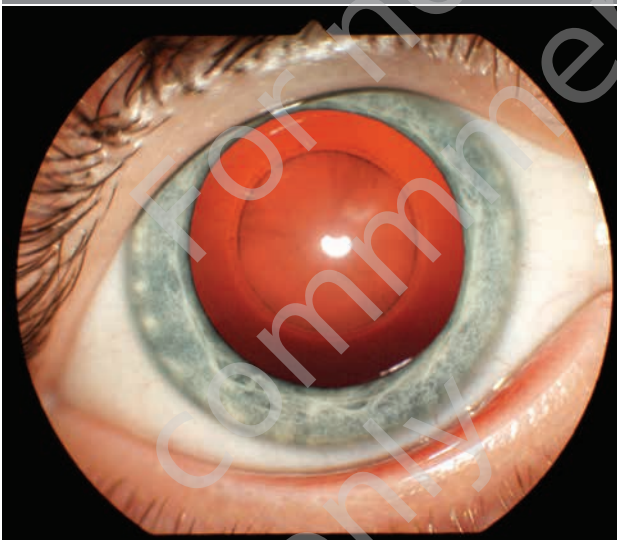
pediatric cataract, technique of surgery, postoperative procedures, postoperative complications

INTRODUCTION

Strategies of cataract treatment varies widely between children and adults. In children, the disease causes not only visual impairment due to visual axis opacification, but also neurophysiological changes related to the disturbance in the development of visual functions (sensory deprivation amblyopia, abnormal development of binocular vision, strabismus, nystagmus) (fig. 1). The eye (especially of a small child) also reacts differently to the surgery itself (more frequent occurrence of postoperative reactions, inflammations, proliferation of LEC and fibrous, very frequent and rapid opacification of the posterior capsule). Therefore, despite significant advances in cataract surgery in children, these operations are still much more controversial than in adults.

FIGURE 1

Perinuclear cataract in a 4-months-old child.



The aim of this study is to present the current views on indications for treatment, time of surgery, techniques of surgery, the problem of implantation of intraocular lenses, postoperative care and postoperative complications in the cataract management in children.

ETIOLOGY

The most common causes of cataracts in children are genetic changes, inherited in an autosomal, recessive, sex-linked or isolated mutations causing changes in the lens protein coding and disruption of their structure. They account for over 50% of cataracts in this age group [1, 2]. Much rarer are viral infections (rubella, cytomegaly, herpes, and others), protozoal infections (toxoplasmosis), metabolic disorders (galactosemia), ocular anomalies (microphthalmia,

PFV syndrome, congenital iris and choroid colobomas), systemic syndromes, injuries, drugs (glucocorticosteroids), chemicals and ionizing radiation.

INDICATIONS FOR CATARACT SURGERY

The vast majority of congenital cataracts are diagnosed in the first year of life. Therefore, indications for surgical treatment are based on the assessment of morphological changes in the lens, and not, as in adults, on eye function tests. In the case of total cataract, the decision is obvious, while in partial cataracts it is usually based on the subjective assessment by an ophthalmologist based on the degree of visual axis opacification and its impact on the child's visual development. If a child has strabismus, nystagmus, lack of interest in the environment or lack of eye contact with the parents in the 6th–8th week period, this indicates the presence of disorder affects the development of vision and that the early surgery is necessary.

WHEN TO OPERATE

In cataract surgery in a child, it seems logical that this procedure should be performed as early as possible to allow for the earliest development of vision. Delayed surgery increases the risk of future visual acuity by 0.1 logMAR for every 3 weeks of delay [3, 4]. There are, however, conflicting opinions in which age the procedure should be performed [3–6]. Observations of children undergoing surgery at various times after birth have shown that the earlier a child is operated on, the more often glaucoma occurs later [1, 6, 8]. The risk of developing glaucoma increases by 1.6 times with each month of earlier surgery [7, 8]. Glaucoma was most common in children operated in the 1 month of age. The incidence of glaucoma in 5 years after cataract surgery is 4 times higher in patients operated in the 1 month of age compared to children operated on after 8 weeks of age [9]. Taking into account the above two factors, most authors now believe that the best age for a unilateral cataract surgery is 6th–8th week of life, and for binocular cataracts, 6th–10th week of life [1, 8].

TECHNIQUES OF SURGERY

The technique of cataract surgery in children differs from that in adults. The main differences are related to the different rigidity of the cornea, sclera and lens capsule, very rapid opacification of the lens posterior capsule after surgery in young children, and the need to operate under general anesthesia.

In children, the cornea and sclera are much more elastic than in adults. Therefore, the anterior chamber collapse quite easy during the procedure. Therefore, after opening

the chamber, viscoelastic preparations of higher viscosity, preferably cohesive, are usually used. Some authors use a continuous infusion of Ringer's fluid with the use of an anterior chamber maintainer. One of the most difficult elements of the procedure is anterior capsulorhexis. The lens capsule in children is very elastic, resembling the rubber of surgical gloves. This makes it very difficult to control the tear of the anterior capsule which easily breaks to the circumference.

The majority (over 50%) of surgeons perform anterior capsulorhexis manually, because the edge of the capsulorhexis is stronger in this method [1, 18]. A modification of manual capsulorhexis is the technique proposed by Nishal, consisting in making two incisions of the anterior capsule paracentrally superior and inferior, and then connecting them (the so-called two-incision push – pull capsulorhexis). Capsular dyes are used more often in children than in adults because they stiffen the capsule and improve the visibility of its edge during manipulation aiding the performance of capsulorhexis [1].

Another technique is capsulotomy with a vitrectome (called vitrectorhexis). However, vitrectome must function in the Venturi system. One can also perform capsulorhexis by means of high-frequency radio waves, with the use of the tip, which is equipped with some coagulation devices (Klōti capsulotomy tip). This technique is much simpler to perform, but its edge is not as strong and breaks more easily compared to manual or vitrectorhexis capsulorhexis, and it requires appropriate equipment only for this purpose [10]. Another method is capsulorhexis using the Fugo plasma knife. The plasma generated at the tip of the device is used to cut the capsules. However, this technique is rarely used as the device costs 20,000 dollars and the cost of a disposable tip is 20 dollars. Unlike other methods, however, the Fugo knife can be used to perform capsulorhexis in the case of capsule fibrosis. Animal studies have shown that the strongest (resistant to lateral breaks) and the most even edge of the capsulorhexis can be obtained by the manual method, followed by a Fugo knife, after vitrectorhexis, and the weakest, most uneven and easily tearable to the circumference after the use of radio waves [11, 12]. Another device using plasma for capsulorhexis is the Carl Zeiss Meditec PEAK-fc probe micropulse knife [13]. However, this knife is currently not commercially available.

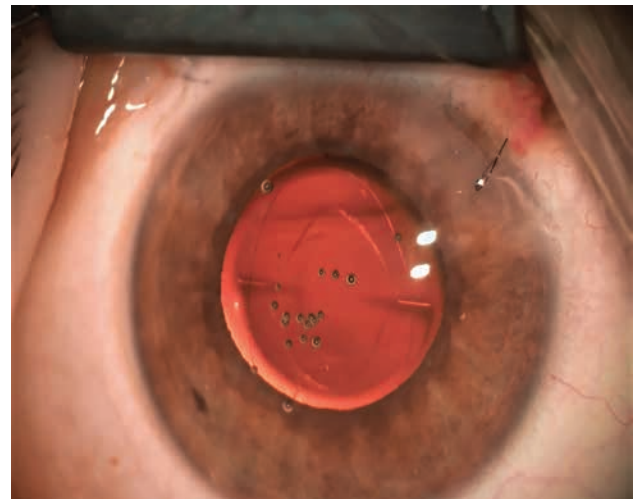
The nucleus and cortex of the lens in children are very soft and can be removed by irrigation and aspiration and therefore phacoemulsification is not used.

Due to the very rapid opacification of the posterior capsule, posterior capsulorhexis/capsulotomy and anterior vitrectomy (to remove the scaffold for proliferation of lens epithelial cells) are routinely performed in young children [1, 14] (fig. 2). It is most often performed with the help of a vitrector (it is easier and at the same time you can perform an

anterior vitrectomy), much less manually. There are various techniques for doing it: before IOL implantation through the main wound, through the pars plana of the ciliary body after lens implantation using a vitrector, or after implantation through the main wound after tilting the IOL upwards with the hook [1, 14]. Better stabilization the IOL one can obtain with optic capture, a deliberate positioning of the IOL optic through in the posterior capsulorhexis/capsulotomy behind the posterior capsule [1, 15]. It also reduces the occurrence of posterior capsule opacification. There is no specific age limit to which capsulorhexis/capsulotomy should be performed, but it is assumed to be 7–10 years [1, 14].

FIGURE 2

The appearance of the eye of a 1-year-old child on the second day after cataract surgery with an implanted refractive, asymmetric multifocal Lentis MPlus IOLs. Visible anterior capsulorhexis, posterior capsulotomy, lens positioning markers and corneal edema at the main wound caused by intraoperative wound sealing. The anterior capsulorhexis and posterior capsulotomy are usually oval because the capsular bag diameter in young children is smaller than in adults, and the IOL is slightly oversized because it is designed for adult eye.



In older children, cataract surgery is performed without posterior capsulorhexis/capsulotomy, as YAG capsulotomy can be performed on them [16].

The cornea and sclera in children is much more elastic than in adults. Besides, children very often rub their operated eyes after surgery. As a result, even a small postoperative wound in children is often not hermetic if it is not sutured. Besides, both wound layers in the operating tunnel may shift with subsequent development of astigmatism [17]. Therefore, the majority (81%) of pediatric cataract surgeons suture the main incision [18].

Recently, a new method of sealing the main postoperative wound in children with the use of cohesive viscoelastics (viscosealing) has been described [19]. It consists in injecting viscoelastic into the area of the wound and applying air to the anterior chamber in order to press the layers of the wound to each other.

AT WHAT AGE TO IOLS SHOULD BE IMPLANTED IN CHILDREN?

At present, the standard in adult cataract surgery is simultaneous removal of the cataract and implantation of an intraocular implant (IOL). In children (especially small ones), implantation of lenses began much later than in adults, and has always been a subject of controversy. In the late 1990s, attempts were made to implant IOLs in newborns. However, clinical observations showed that this was the cause of a number of intra- and postoperative complications in these children. IOLs manufactured for adults were used for implantations, whereas the diameter of the lens capsular bag in adults is 10.5 mm on average, while in a newborn child less than 7 mm, at 2 years old 9 mm and at 5 years old 10 mm [20]. To date, on the market there are no available IOLs designed for children. The only such lens dedicated to children was produced briefly in the 90's (Kidlens by IOL Technologies). In addition, operated children often developed secondary cataracts, despite the performance of posterior capsulotomy and anterior vitrectomy, as well as postoperative inflammatory reactions [1, 8, 21]. This was the reason for the conduction of randomized clinical trials in the USA and Canada comparing the results of cataract surgery in children under 7 months of age in whom were either IOLs were implanted or were using contact lenses after surgery (Infant Aphakia Treatment Study Group) [22, 23]. Similar clinical trials were also conducted in Great Britain and Ireland (British Isles Congenital Cataract Interest Group IoLunder2 prospective study) [24]. The studies of the Infant Aphakia Treatment Study Group showed that both 4.5 and 10.5 years after surgery, visual acuity and binocular vision are similar in both groups of patients [22, 23]. In the group with implanted IOLs visual axis opacifications (pupillary membrane, lens surface membranes, pupil displacement) were 10 times more common (4% for contact lenses, 40% after operations with IOLs) [22]. It required repeated operations to clear the visual axis. These operations were 5 times more common in children with IOLs [22]. In some children with IOLs, even five operations were required to maintain clear visual axis. Glaucoma developed in 16% of children with contact lenses and in 19% of children with IOLs. It required anti-glaucoma surgery (4% in the contact lens group and 9% in the intraocular lens group [22]. In the case of contact lenses, however, there were corneal complications, keratitis punc-

tata, abrasions of the corneal epithelium, and rarely corneal ulcerations (in 18% of operated patients) [22].

The authors of the Infant Aphakia Treatment Study Group conclude that the implantation of IOLs in children under 7 months of age does not result in better visual acuity and binocular vision, but is associated with frequent repeated surgeries [22, 23].

The British Isles Congenital Cataract Interest Group IoLunder2 prospective study also showed that visual acuity after implantation of IOLs is the same as in children wearing contact lenses, both in monocular and binocular cataracts [24]. In the group with IOLs much more often it was necessary to perform reoperation in order to clear the visual axis (5 times more often in the case of binocular cataracts, 20 times more often in the case of monocular cataracts groups).

Due to the results of these studies, the implantation of intraocular lenses in children under 7 months of age is not recommended in the USA and Canada [21–23] and this is also the official position of the American Academy of Ophthalmology [8], and in Great Britain and Ireland in children under 2nd year of life [24]. The exceptions to this rule are the cases of children with significant developmental disorders, in whom application of contact lenses may be difficult and for social reasons (financial problems of long-term use of contact lenses, lack of manual skills of parents to apply such lenses).

Surveys of ophthalmologists operating cataracts in children conducted in the USA, Asia and Europe have shown that the vast majority of them do not implant IOLs in patients under 7 months of age [25].

In younger children surgery is performed with a vitrector through pars plana or corneal limbus and consists with nucleus and cortex removal, circular anterior and posterior capsulectomy of about 5mm and anterior vitrectomy.

Most pediatric ophthalmologists implant monofocal IOLs in children. Recently, however, multifocal lenses have been implanted more and more often. The author of the work for 10 years implants only multifocal IOLs in children [26].

INTRAOPERATIVE INFECTION PROPHYLAXIS

Before the surgery, it is recommended to apply a 5% solution of povidone-iodine to the conjunctival sac. In Europe, most ophthalmologists use 1 mg cefuroxime in 0.1 ml intracameral injection at the end of surgery, as recommended by the European Society of Cataract & Refractive Surgeons [27]. In the USA, the use of cefuroxime is not as widespread as in Europe. Other antibiotics used for this purpose are vancomycin (1 mg in 0.1 ml) or moxifloxacin (0.1 mg in 0.1 ml prepared from commercial eye drops). [28]. As postoperative inflammatory reactions in children are much greater than in adults, most surgeons at the end of the operation inject dexamethasone in the anterior cham-

ber at a dose of 0.4 mg in 0.1 ml and/or under the in the lower conjunctival fornix in a dose of 2 to 4 mg in 1 ml.

POSTOPERATIVE MANAGEMENT

Intracameral penetration of bacteria through the postoperative wound is possible in the period when it is not covered with epithelium, i.e. for the first 2–3 days. Therefore, after the operation for a few days (5–7 days), it is recommended to use antibiotics in the eye drops.

Since postoperative reactions and inflammation following surgery are more common in children than in adults, glucocorticosteroids are usually given in the eye drops (usually dexamethasone or loteprednol). These drugs should not be used for more than 4–6 weeks as they may then cause retardation of child growth, Cushing's syndrome and suppression of the hypothalamus–pituitary–adrenal axis [1]. Alternatively, instead of using steroid drops after surgery for 4 weeks, 1 ml of methylprednisolone acetate can be administered on the operating table under the conjunctiva in the lower fornix [29]. This preparation is released under the conjunctiva and through the sclera into the vitreous and anterior chamber for 3–4 weeks, thus avoiding the use of corticosteroids drops that is always poorly tolerated by children and their instillation is a big problem for parents.

POSTOPERATIVE COMPLICATIONS

The most common complication of cataract surgery in children is opacification of the visual axis, which occurs more often the younger the child is operated on and after the implantation of an IOLs (see above). The second most common complication is glaucoma. It occurs in 10% to 25% of operated children [1], but in some publications it was even 58% [30]. Glaucoma may develop even several decades after cataract surgery, and therefore these patients must have their intraocular pressure tested for the rest of their lives. IOL implantation is not a factor that reduces the incidence of glaucoma [7–9, 21, 22, 24], although glaucoma was less common in children with IOLs in some previous clinical trials [31, 32].

Prostaglandins, β -blockers and carbonic anhydrase inhibitors are used to treat this form of glaucoma. α_2 -adrenergic drugs should not be used in children due to their suppressive effects on the central nervous system in this

age group. If conservative treatment is not effective, anti-glaucoma surgery is required. In children filtering fistulas overgrowth by fibrous tissue and its closure at the external opening is often observed in aphakic and pseudophakic eyes. Therefore, cyclophotocoagulation and anti-glaucoma valve implants are used in children much more often than in other forms of glaucoma. In the latter operations, the implant tube should be implanted into the posterior chamber, because after implantation into the anterior chamber, the cornea often decompensates due to its high elasticity and increased possibility of contact of the tube with the endothelium. Some authors use 360° *ab externo* suture trabeculotomy, but it is a technically difficult procedure (problems with finding Schlemm's canal in such a young children) and frequent postoperative complications (anterior chamber hemorrhages, hypotonia) [33].

Studies carried out as part of the Infant Aphakia Treatment Study Group showed that the thickness of the cornea after the surgery is the same in the group of children with aphakia and pseudophakia (605 μ m and 637 μ m, respectively, while the number of endothelial cells was lower after intraocular lens implantation (3445/mm² and 3921/mm²) [34]. Studies by the Infant Aphakia Treatment Study Group 5 years after surgery also showed that in both groups of patients, the increase in the length of the eyeball and the incidence of strabismus are similar [35, 36]. However, in 5% of the operated children explanation the IOLs was performed to due to very high myopia (–7.50 to –19.00 D).

CONCLUSIONS

Surgery methods of pediatric cataracts allow nowadays to obtain good visual acuity in operated children. The operation should be performed in children over 2 months of age because of more frequent occurrence of glaucoma in earlier operated patients. In children under 10 years of age posterior capsulotomy and anterior vitrectomy are required during surgery to prevent opacification of the posterior lens capsule after surgery. Due to the frequent occurrence of opacification of the visual axis, it is recommended that IOLs should not be implanted in children under 7th month of life (under 2th year of life according to some recommendations).

Figures: from the author's own materials.

CORRESPONDENCE

Prof. Marek E. Prost, MD, PhD

Department of Ophthalmology,
Military Institute of Aviation Medicine, Warsaw, Poland
01-755 Warsaw, Zygmunta Krasińskiego 54/56
e-mail: mprost@wiml.waw.pl

ORCID

Marek E. Prost – ID – <http://orcid.org/0000-0002-56204171>

References

1. Self JE, R Taylor R, Solebo AL et al. Cataract management in children: a review of the literature and current practice across five large UK centres. *Eye*. 2020. <https://doi.org/10.1038/s41433-020-1115-6>.
2. Francis PJ, Moore AT. Genetics of childhood cataract. *Curr Opin Ophthalmol*. 2004; 15: 10-5.
3. Birch EE, Stager DR. The critical period for surgical treatment of dense, congenital, unilateral cataracts. *Invest Ophthalmol Vis Sci*. 1996; 37: 1532-8.
4. Birch EE, Cheng C, Stager DR Jr et al. The critical period for surgical treatment of dense congenital bilateral cataracts. *J AAPOS*. 2009; 13: 67-71.
5. Abadi RV, Forster JE, Lloyd IC. Ocular motor outcomes after bilateral and unilateral infantile cataracts. *Vis Res*. 2006; 46: 940-52.
6. Watts P, Abdoell M, Levin AV. Complications in infants undergoing surgery for congenital cataract in the first 12 weeks. *J AAPOS*. 2003; 7: 81-5.
7. Beck AD, Freedman SF, Lynn MJ et al. Glaucoma-related adverse events in the Infant Aphakia Treatment Study: 1-year results. *Arch Ophthalmol*. 2012; 130: 300-5.
8. Lambert SR, Aakalu VK, Hutchinson AK et al. Intraocular lens implantation during early childhood: A report by the American Academy of Ophthalmology. *Ophthalmology*. 2019; 126: 1454-61.
9. Vishwanath M, Cheong-Leen R, Taylor D et al. Is early surgery for congenital cataract a risk factor for glaucoma? *Br J Ophthalmol*. 2004; 88: 905-10.
10. Comer RM, Abdulla N, O'Keefe M. Radiofrequency diathermy capsulorhexis of the anterior and posterior capsule in pediatric cataract surgery: Preliminary results. *J Cataract Refract Surg*. 1997; 23: 641-4.
11. Trivedi RH, Wilson ME, Bartholomew LR. Extensibility and scanning electron microscopy evaluation of 5 pediatric anterior capsulotomy techniques in a porcine model. *J Cataract Refract Surg*. 2006; 32: 1206-13.
12. Izak AM, Werner L, Pandey SK et al. Analysis of the capsule edge after Fugo plasma blade capsulotomy, continuous curvilinear capsulorhexis, and can-opener capsulotomy. *J Cataract Refract Surg*. 2004; 30: 2606-11.
13. Nguyen A, Kraus CL. Surgical steps. In: Kraus CL (ed). *Pediatric cataract surgery and IOL implantation: a case-based guide*. Springer Nature, Cham 2020: 89-104.
14. Vasavada AR, Praveen MR, Tassignon MJ et al. Posterior capsule management in congenital cataract surgery. *J Cataract Refract Surg*. 2011; 37: 173-93.
15. Vasavada AR, Vasavada V, Shah SK et al. Postoperative outcomes of intraocular lens implantation in the bag versus posterior optic capture in pediatric cataract surgery. *J Cataract Refract Surg*. 2017; 43: 1177-83.
16. Choi SH, Kim YD, Yu YS et al. Long-term outcome of Nd:YAG laser posterior capsulotomy in children: procedural strategies and visual outcome. *Am J Ophthalmol*. 2019; 197: 121-7.
17. Basti S, Krishnamachary M, Gupta S. Results of sutureless wound construction in children undergoing cataract extraction. *J Pediatr Ophthalmol Strabismus*. 1996; 33: 52-4.
18. Wilson ME, Bartholomew LR, Trivedi RH. Pediatric cataract surgery and intraocular lens implantation: Practice styles and preferences of the 2001 ASCRS and AAPOS memberships. *J Cataract Refract Surg*. 2003; 29: 1811-20.
19. Kaur S, Sukhija J, Jugran D et al. Viscosealing of ports in pediatric cataract surgery. *Clin Exper Vision and Eye Res*. 2019; 2: 1-4.
20. Wilson ME, Apple DJ, Bluestein EC et al. Intraocular lenses for pediatric implantation: biomaterials, designs, and sizing. *J Cataract Refract Surg*. 1994; 20: 584-91.
21. Lin AA, Buckley DG. Update on pediatric cataract surgery and intraocular lens implantation. *Curr Opin Ophthalmol*. 2010; 21: 55-9.
22. The Infant Aphakia Treatment Study Group. A randomized clinical trial comparing contact lens to intraocular lens correction of monocular aphakia during infancy: HOTV optotype acuity at age 4.5 years and clinical findings at age 5 years. *JAMA Ophthalmol*. 2014; 132: 676-82.
23. Lambert SR, Cotsonis G, DuBois L et al.; Infant Aphakia Treatment Study Group. Long-term effect of intraocular lens vs contact lens correction on visual acuity after cataract surgery during infancy. A randomized clinical trial. *JAMA Ophthalmol*. 2020; 138(4): 365-72. <https://doi.org/10.1001/jamaophthalmol.2020.0006>.
24. Solebo AL, Cumberland P, Rahi JS; British Isles Congenital Cataract Interest Group. 5-year outcomes after primary intraocular lens implantation in children aged 2 years or younger with congenital or infantile cataract: findings from the IoLunder2 prospective inception cohort study. *Lancet Child Adolesc Health*. 2018; 2: 863-71.
25. Koo EB, VanderVeen DK, Lambert SR. Global practice patterns in the management of infantile cataracts. *Eye Contact Lens*. 2018; 44(suppl 2): S292-6.
26. Prost M. Visual function after bilateral implantation of multifocal versus monofocal IOLs in children below 5 years of age. *Ophthalmology*. 2019; 6: 192-7.

27. Barry P, Seal DV, Gettinby G; ESCRS Endophthalmitis Study Group. ESCRS study of prophylaxis of postoperative endophthalmitis after cataract surgery: Preliminary report of principal results from a European multicenter study. *J Cataract Refract Surg.* 2006; 32: 407-10.
28. Arsinoff SA. Dose and administration of intracameral moxifloxacin for prophylaxis of postoperative endophthalmitis. *J Cataract Refract Surg.* 2016; 42: 1730-41.
29. Prost M. Czy można nie stosować kropli sterydowych po operacjach wewnątrzgałkowych u dzieci? Referat wygłoszony na 48. Zjeździe Okulistów Polskich, Kraków 2017.
30. Chen TC, Bhatia LS, Halpern EF et al. Risk factors for the development of aphakic glaucoma after congenital cataract surgery. *Trans Am Ophthalmol Soc.* 2006; 104: 241-51.
31. Asrani S, Freedman S, Hasselblad V et al. Does primary intraocular lens implantation prevent “aphakic” glaucoma in children? *J AAPOS.* 2000; 4: 33-9.
32. Kirwan C, Lanigan B, O’Keefe M. Glaucoma in aphakic and pseudophakic eyes following surgery for congenital cataract in the first year of life. *Acta Ophthalmol.* 2010; 88: 53-9.
33. Beck AD, Lynn MJ, Crandall J et al. Surgical outcomes with 360-degree suture trabeculotomy in poor prognosis primary congenital glaucoma and glaucoma associated with congenital anomalies or cataract surgery. *J AAPOS.* 2011; 15: 54-8.
34. Morrison DG, Lynn MJ, Freedman SF et al.; Infant Aphakia Treatment Study Group. Corneal changes in children after unilateral cataract surgery in the Infant Aphakia Treatment Study. *Ophthalmology.* 2015; 122: 2186-92.
35. Wilson ME, Trivedi RH, Weakley Jr et al.; Infant Aphakia Treatment Study Group. Globe axial length growth at age 5 years in the Infant Aphakia Treatment Study. *Ophthalmology.* 2017; 124: 730-3.
36. Bothun ED, Lynn MJ, Christiansen SP et al.; Infant Aphakia Treatment Study Group. Sensorimotor outcomes by age 5 years after monocular cataract surgery in the Infant Aphakia Treatment Study (IATS). *J AAPOS.* 2016; 20: 49-53.

Conflict of interest:

None.

Financial support:

None.

Ethics:

The content presented in the article complies with the principles of the Helsinki Declaration, EU directives and harmonized requirements for biomedical journals.