

CD30-positive T-cell lymphoproliferation of the bulbar conjunctival mucosa showing spontaneous remission

Paula Marticorena Álvarez¹, Guadalupe Garrido Ceca¹,
Mercedes Guijarro Rojas²

¹ Department of Ophthalmology, Hospital Universitario La Princesa, Madrid, Spain

Head of Department: Juan Jacobo Gonzalez Guijarro, MD, PhD

² Department of Pathological Anatomy, Hospital Universitario La Princesa, Madrid, Spain

Head of Department: Javier Fraga Fernandez, MD, PhD



HIGHLIGHTS

There is insufficient scientific evidence regarding the clinical behavior and management of mucosal CD30-positive T-cell lymphoproliferative lesions.

ABSTRACT

Introduction: CD30-positive T-cell lymphoproliferative lesions represent a spectrum of heterogeneous disorders.

Clinical case: An incision biopsy was performed in a 25-year-old man with a lump in the bulbar conjunctiva. Immunohistochemistry indicated membrane positivity for CD3 and CD30 in over 75%. PCR identified the monoclonal nature of the T-cells. The hematological study was normal. Following biopsy, the conjunctival tumor diminished until disappear.

Conclusions: Mucosal CD30-positive T-cell lymphoproliferation could be ascribed to a reactive process but it is necessary to rule out a primary conjunctival tumor or the first manifestation of an anaplastic large cell lymphoma.

Key words: lymphoproliferative, CD30, T-cell, conjunctival

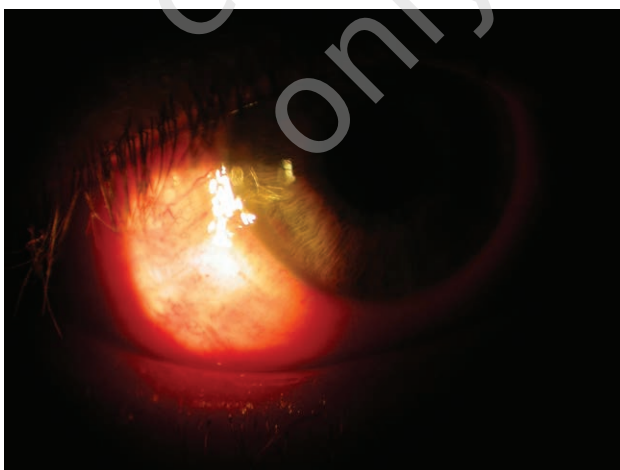
CASE REPORT

A 25-year-old man presented to the emergency room after noticing a pain-free lump in the temporal bulbar conjunctiva of the right eye. He reported the use of tobramycin-dexamethasone eye drops every 4 h in both eyes for the past 3 days, as treatment for conjunctivitis prescribed by his family doctor. The patient had -2D of myopia and occasionally wore contact lenses, which he had not used over the last few days. His medical records indicated no systemic diseases or prior trauma.

Best-corrected visual acuity was 1.0 in both eyes. A slit lamp exam without the need for fluorescein staining revealed a fixed conjunctival 4×6.5 mm mass stuck to the corneal limbus between 6 and 8 o'clock sparing the cornea. The conjunctiva appeared hyperemic in this zone (fig. 1). The eyelids showed a mild follicular response without secretions. Findings in the rest of the anterior pole exam along with intraocular pressure and a fundus exam were unremarkable as was the examination of the contralateral eye. The patient was prescribed tobramycin-dexamethasone eye drops every 8 h and artificial tears and was scheduled for an outpatient visit. Four days later, upon confirmation of no improvement, an emergency 2×1 mm incisional conjunctival biopsy was performed. During subsequent follow up visits, a gradual reduction in the size and thickness of the lesion was observed.

FIGURE 1

Image of the 4×6.5 mm mass in the bulbar conjunctiva adhered to the corneal limbus at 6–8 o'clock without invading the adjacent cornea.



INTERVENTION AND RESULTS

Biopsy observations revealed a partially eroded conjunctival mucosal epithelium with reactive characteristics. The underlying conjunctiva showed medium-large lymphoid cells intermixed with abundant small lymphocytes, eosin-

ophils, polymorphonuclear cells and histiocytes (fig. 2). The predominant cell type was immunolabeled as CD45+, CD3+, and showed cell membrane CD30 positivity in over 75% of this population and high nuclear positivity for Ki-67 (Mib-1) (fig. 3). The cells of the lesion were negative for ALK, VEB, CD15, EMA, CD56, perforin and granzyme B. Further tumors of the eye surface were ruled out. A PCR study of paraffinated tissue using primers targeting the TCR-gamma gene (VJA, VJB) revealed the T lymphoid monoclonal nature of the cells (fig. 4). The lesion was described as a lymphoproliferative disorder showing CD30-positive monoclonal T cells. Possible diagnoses given were anaplastic large cell lymphoma or lymphomatoid papulosis. The findings of a complementary study by the Hematology Unit were unremarkable (blood count, biochemistry, autoantibodies, HIV, HBV, HCV, peripheral blood immunofluorescence, cranio-facial, cervical-thoracic-abdominal and pelvic CT). In the one-month follow up visit, the lesion had completely resolved (fig. 5) and the patient was asymptomatic. After 18 months of follow up, the patient remains well with no signs of local recurrence or systemic lymphoma.

FIGURE 2

Conjunctival mucosa biopsy specimen (H&E, $\times 10$). Epithelium partially eroded with reactive characteristics overlying the conjunctiva, which shows atypical lymphoid cells. These cells were medium-large and intermixed with numerous small lymphocytes, eosinophils, polymorphonuclear cells and histiocytes. Inset shows an enlarged image ($\times 40$).

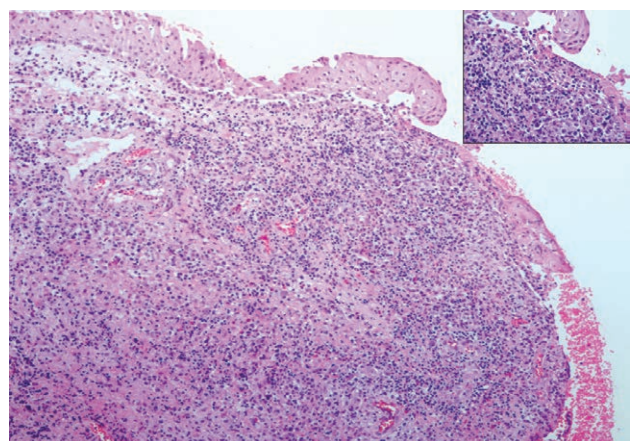


FIGURE 3

Atypical cells showed membrane positivity for CD3, CD30 in over 75% of the population and high nuclear positivity for Ki-67 (Mib-1) ($\times 4$, inset, $\times 20$).

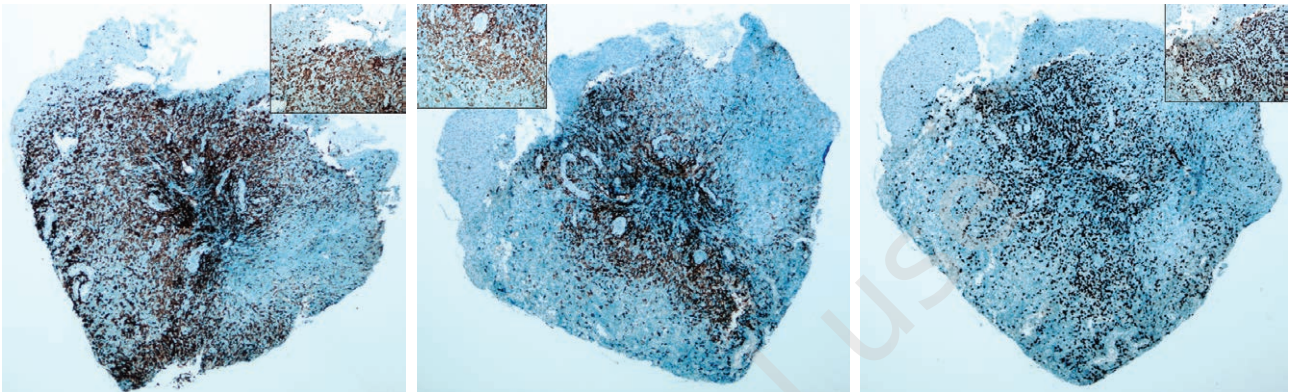


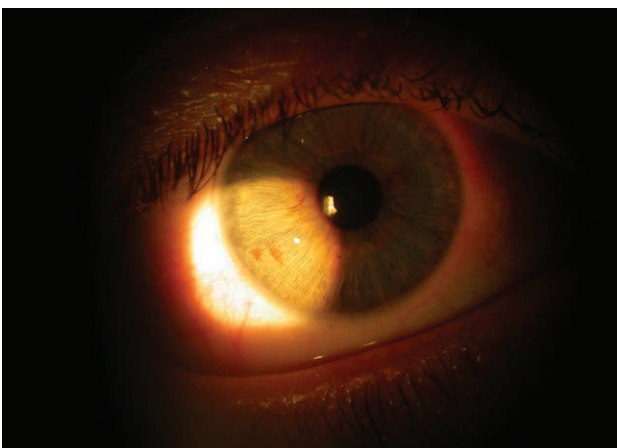FIGURE 4

Vertical polyacrylamide gel electrophoresis indicating TCR- γ gene rearrangements. Arrow indicates the positive monoclonal band.



FIGURE 5

At one month of follow up, the lesion had completely resolved.



DISCUSSION

We here describe the case of a lymphoproliferative process affecting CD30-positive T cells of the bulbar conjunctival mucosa that spontaneously resolved with no signs of recurrence one year later.

Despite a lack of clear diagnostic criteria for mucosal lymphoproliferations [1], in their series of 9 patients, Sciallis et al. at the Mayo Clinic observed the following common features [2]:

- Localized disease. In our patient, the right temporal conjunctiva was affected and there was no orbital or systemic extension.
- Pain free course (sometimes even spontaneous remission with recurrence or not in the future). In the present case, the lesion spontaneously resolved within a month and there were no signs of recurrence one year later.
- Epithelial ulceration. The epithelium in our patient was seen to be partially eroded in the pathological study (fig. 2, enlarged image).
- Presence of CD30-positive large T cells and numerous intermixed eosinophils. We observed this finding although accompanying eosinophils were scarce. The Mayo Clinic group described a varying degree of eosinophilia in their patient series and reported a lack of marked eosinophilia in the three mucosae outside the mouth (conjunctiva, orbit and nasal cavity) [2].
- Clonal T cell-receptor gene rearrangements. This was also observed in our case (fig. 4).

The report by the Mayo clinic [2] in which nine mucosal CD30-positive T-cell lymphoproliferations were examined (mucosal lesions in seven and mucocutaneous lesions in two patients), indicates clinical-pathological similarities between mucosal and primary cutaneous lymphoproliferative processes. However, owing to a lack of literature

reports there is insufficient scientific evidence regarding the clinical behavior and management of these lesions.

Shields et al. observed an association with systemic lymphoma in 31% of 117 patients with conjunctival lymphoid tumors and described an extralimbal tumor location (conjunctival fornix and middle bulbar conjunctiva) and the presence of multiple conjunctival tumors as predictive factors for developing systemic lymphoma [3]. Our patient showed one of these predictive factors: tumor location in the bulbar conjunctiva. However, we should mention that in Shields' series there was no case of CD30-positive T-cell lymphoproliferation such that results are not comparable to ours.

Its spontaneous remission and lack of recurrence suggest it to be some sort of reactive process [5]. We should nevertheless underscore that the findings of morphological, immunophenotypic and genetic tests in all these cases are identical, making them indistinguishable. To date, we lack sufficient reports of mucosal CD30-positive T-cell lymphoproliferative lesions to help us differentiate or predict the onset of lymphoma. This situation determines a need for full screening for systemic disease and close clinical follow up in patients presenting with these lesions.

Figures: from the author's own materials.

CONCLUSION

The lesion in the present patient could be ascribed to a reactive process, a primary conjunctival tumor or the first manifestation of an anaplastic large cell lymphoma [4].

CORRESPONDENCE

Dra. Paula Marticorena Álvarez

Department of Ophthalmology, Hospital
Universitario La Princesa, Madrid, Spain
Calle de Diego de León, 62
28006 Madrid, Spain
e-mail: paula.marticorena@salud.madrid.org

ORCID

Paula Marticorena Álvarez – ID – <http://orcid.org/0000-0003-4817-7350>
Guadalupe Garrido Ceca – ID – <http://orcid.org/0000-0002-3917-2446>

References

1. Wang W, Cai Y, Sheng W et al. The spectrum of primary mucosal CD30-positive T-cell lymphoproliferative disorders of the head and neck. *Oral Surg Oral Med Oral Pathol Oral Radiol.* 2014; 117(1): 96-104. <http://doi.org/10.1016/j.oooo.2013.10.002>.
2. Sciallis AP, Law ME, Inwards DJ et al. Mucosal CD30-positive T-cell lymphoproliferative of the head and neck show a clinicopathologic spectrum similar to cutaneous CD30-positive T-cell lymphoproliferative disorders. *Mod Pathol.* 2012; 25(7): 983-92.
3. Shields CL, Shields JA, Carvalho C et al. Conjunctival lymphoid tumors: clinical analysis of 117 cases and relationship to systemic lymphoma. *Ophthalmology.* 2001; 108(5): 979-84.
4. Clarke B, Legodi E, Chrystal V et al. Systemic anaplastic large cell lymphoma presenting with conjunctival involvement. *Arch Ophthalmol.* 2003; 121(4): 568-70.
5. Liu F, Li M, Zhang LY et al. Clinicopathologic features of primary mucosal CD30-positive T-cell lymphoproliferative disorders in head and neck region. *Zhonghua Bing Li Xue Za Zhi.* 2018; 47(6): 412-6.

Authors' contributions:

Paula Marticorena: 70%; Guadalupe Garrido: 20%; Mercedes Guijarro: 10%.

Conflict of interest:

None.

Financial support:

None.

Ethics:

The content presented in the article complies with the principles of the Helsinki Declaration, EU directives and harmonized requirements for biomedical journals.