

# Choroidal neovascularization related to melanocytic naevus — a single centre study

Emilia Zwolińska, Iwona Rospond-Kubiak

Ocular Oncology Service, Department of Ophthalmology, Poznan University of Medical Sciences  
Head: Prof. Jarosław Kocięcki, MD, PhD



## ABSTRACT

**Purpose:** To assess the angiographic and optical coherence tomography angiography (OCTA) features as well as the natural course of the choroidal neovascularization (CNV) associated with choroidal naevi.

**Setting/venue:** Ocular Oncology Service, Department of Ophthalmology, Poznan University of Medical Sciences

**Material and methods:** Retrospective chart analysis of the patients who presented to the Ocular Oncology Service in Poznan, Poland between 2011–2021 with the diagnosis of suspicious choroidal naevus. In all patients full ophthalmic examination and multimodal imaging, including fundus photography, autofluorescence, B-ultrasound, optical coherence tomography (OCT), OCT angiography (OCTA) and fluorescein angiography (FAF), were performed.

**Results:** There were 9 lesions in 9 patients, 9 women aged 14–79 years (mean age: 58.2 years). All the lesions were located in the posterior pole and most of them were pigmented (88.9%). CNVs associated with choroidal naevi were type I in 66.7% and type II in 33.3% of cases. 5 patients required treatment: anti-VEGF injection (alone or with transpupillary thermotherapy) was administered. The median follow-up was 24 months (range: 2–145). In two of all treated patients (40%), we observed BCVA gain (2–4 lines), in one patient (20%) it remained stable and in two (40%) it deteriorated. The final visual acuity was below 0.1 only in 1 patient. During the period of observation none of the lesions progressed to uveal melanoma.

**Conclusions:** CNV associated with choroidal naevus could be the reason for subretinal fluid (SRF) leakage and visual loss. The response to anti-VEGF treatment is satisfactory in the majority of patients. Choroidal naevi with accompanying CNV have none or very low malignant transformation potential.

**Key words:** choroidal naevus, choroidal neovascularization, subretinal fluid, optical coherence tomography angiography, CNV, OCTA

## HIGHLIGHTS

Choroidal neovascularization (CNV) might be associated with choroidal naevus and lead to a subretinal fluid (SRF) leakage. An anti-VEGF injection is a good treatment option in a majority of cases.

## INTRODUCTION

Choroidal naevus is the most common primary melanocytic lesion with the incidence of 2–25% in white Caucasian population [1, 2]. It is estimated that about 1 in 8000 naevi can undergo a malignant transformation [3], although it is still not clear whether the naevus stage in the development of malignant melanoma is required.

The presence of subretinal fluid (SRF) accompanying the choroidal melanocytic lesion is significant and the second most important factor for malignant transformation [4, 5]. However, it is often observed even with benign nevi as a result of chronic changes in retinal pigment epithelium (RPE) overlying the lesion [3, 6–8]. More rapid appearance of the SRF may also be related to less common occurrences of the choroidal neovascularization associated with the nevus [7, 9, 10]. Although CNVs associated with choroidal naevi have been described over 50 years ago [7, 8] due to the development of optical coherence tomography (OCT) and OCT angiography (OCTA) we now have a more detailed insight in their structure. The aim of the study was to assess the presentation and follow-up of the patients with CNV related to choroidal melanocytic naevus.

## MATERIALS AND METHODS

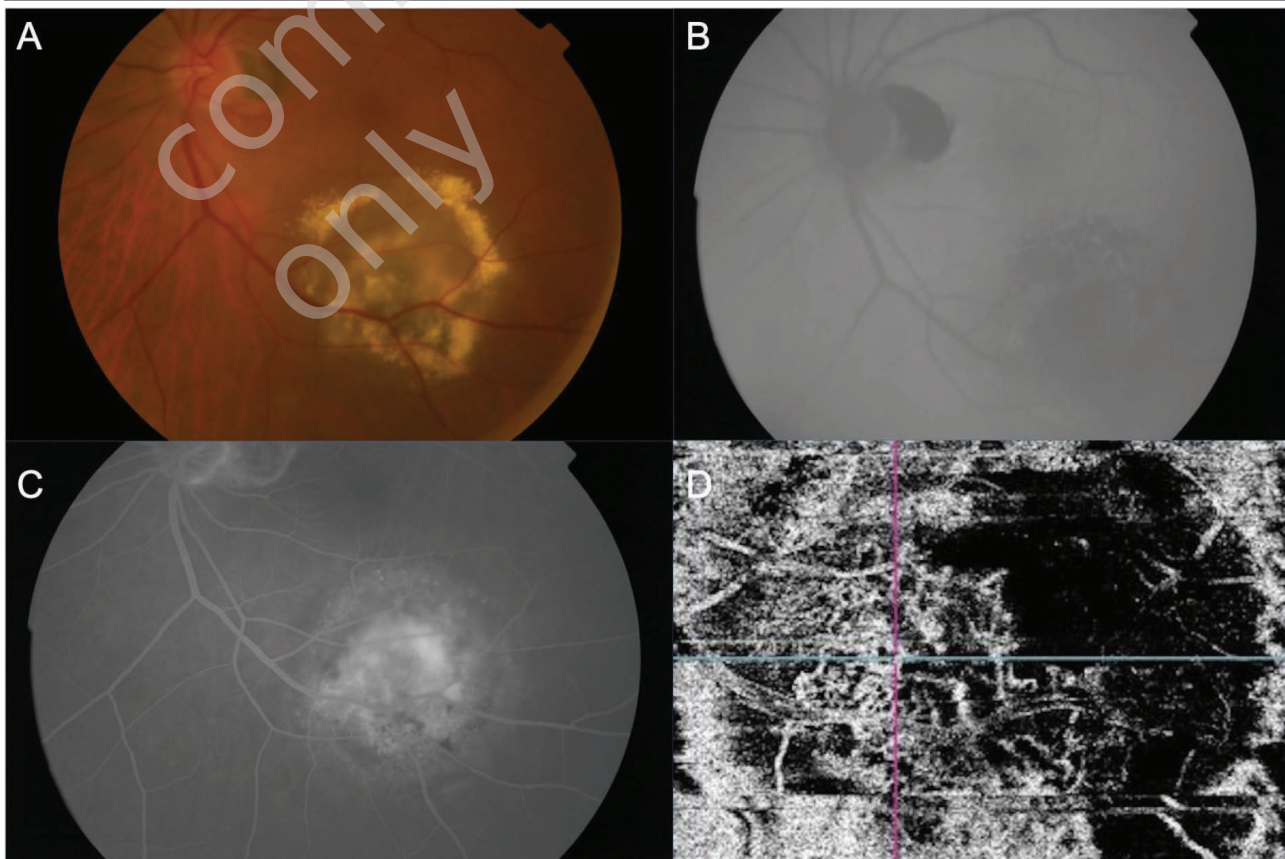
The medical records of the patients referred to the Ocular Oncology Service in Poznań, Poland, between January 2011 and December 2021 with a suspicion of malignant transformation of choroidal naevus, who were finally diagnosed with CNV accompanying melanocytic lesion were retrospectively reviewed.

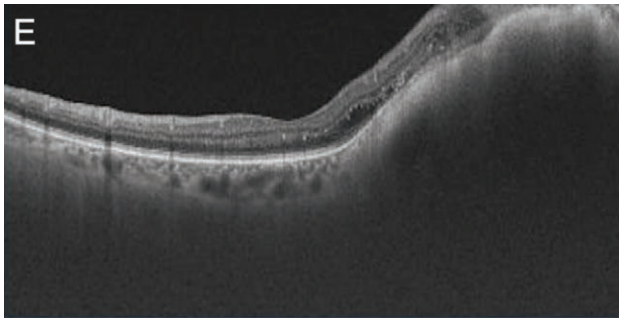
We performed full ophthalmological examination including Snellen best corrected visual acuity (BCVA) assessment, slit lamp fundus examination, colour fundus photography, OCT, OCTA, B-scan ultrasonography and fundus autofluorescence (FAF). To confirm the diagnosis, fluorescein angiography was performed for all patients (fig. 1).

OCT (DRI OCT Triton, Topcon Co., Tokyo, Japan) were acquired at each visit, as well as colour fundus images and FAF images, which were obtained with the fundus camera (TRC 50DX Type IA, Topcon Corporation, Tokyo, Japan), and B-scan ultrasonography examinations, which were performed with 10 MHz B-probe (Eyecubed, Ellex, Australia; 2015–2020) and 20 MHz B-probe (ABSolu, V1.03, Quantel Medical, France; 2020–2021). Since 2019, OCTA was performed at each visit (DRI OCT Triton, Topcon Co.,

FIGURE 1

Multimodal imaging in one of our patients. A. Colour photography. B. Fundus autofluorescence. C. Fluorescein angiography. D. Optical coherent tomography angiography. E. Optical coherent tomography.





Tokyo, Japan). Patients underwent FA examination (TRC 50DX Type IA, Topcon Corporation, Tokyo, Japan) at least once during the observation period – examinations were performed with the standard protocol [11].

Patients qualified for laser transpupillary thermotherapy were treated during the same visit with the 810 nm diode laser (Oculight SLx, Iridex, Mountain View, CA, USA). Those who required treatment with intravitreal anti-vascular endothelial growth factor (anti-VEGF) were referred to their local hospitals where the injections were performed.

## RESULTS

We identified 9 melanocytic choroidal lesions with accompanying CNV in 9 eyes. All patients were women aged 14–79 years (mean age 58.2 years). Median time of observation was 24 months (range 2–145 months). The patients demographic data are listed in table 1.

Demographic features.	
Feature (n = 9 patients)	N (%)
<b>Age: mean; median (range) [years]</b>	58; 65 (14–79)
<b>Race</b>	
Caucasian	9 (100)
Asian	0
African American	0
Hispanic	0
<b>Sex</b>	
Male	0
Female	9 (100)
<b>Laterality</b>	
Right	2 (22)
Left	7 (78)

All found lesions were located in the posterior pole. 8 lesions were pigmented (88.9%) and 1 was amelanotic (11.1%). CNV was located at the apex of the lesion in 7 cases (77.8%). CNV presented as type I (6 lesions – 66.7%; fig. 2) or type II (3 lesions – 33.3%; fig. 3). We found the sea-fan shape in 5 lesions (55.6%) and filamentous-shape in 2 lesions (22.2%). In 2 patients the morphology of the

CNV could not be clearly determined (22.2%). All patients presented with subretinal fluid leakage.

FIGURE 2

Woman, aged 68, CNV type I.

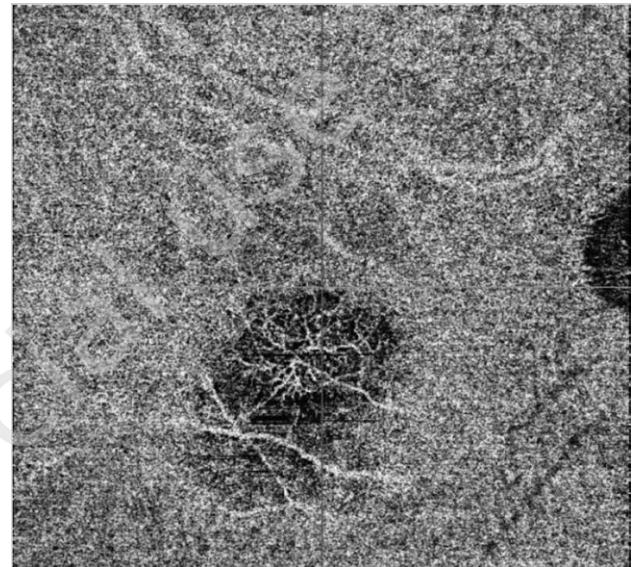
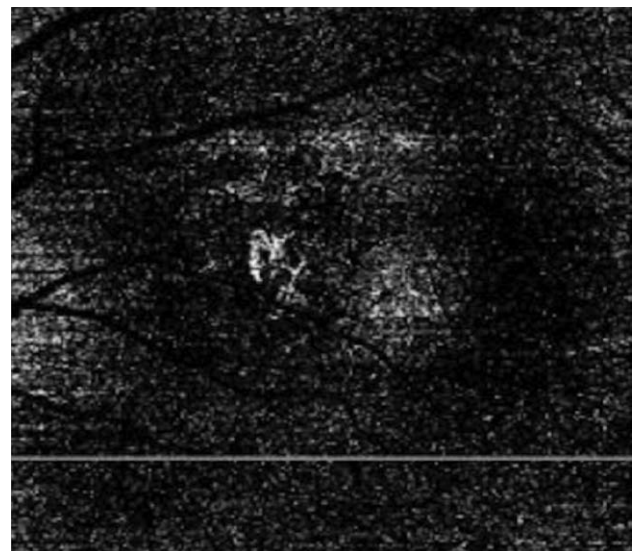


FIGURE 3

Woman, aged 14, CNV type II.



5 of the lesions (55.6%) required treatment due to progression of visual symptoms.

As a majority of the lesions we saw were extrafoveal, 4 out of 5 patients who required treatment received transpupillary thermotherapy (TTT) as an initial intervention. 3 (75%) of them were also treated with anti-VEGF. 2 patients (40%) were treated with anti-VEGF only. In 2 of all treated patients (40%), we observed BCVA gain (2–4 lines), in 1 patient (20%)

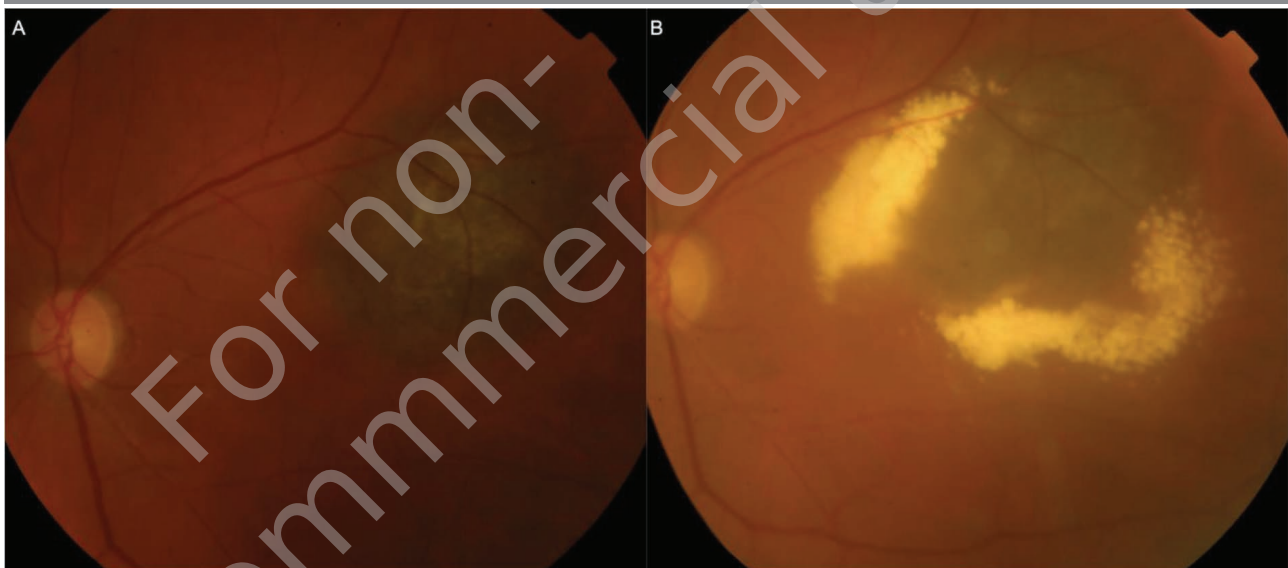


it remained stable and in 2 (40%) it deteriorated. Patients who showed improvement in BCVA were treated with anti-VEGF and one of those patients also received TTT. The final visual acuity was  $< 0.5$  in 4 out of 9 patients (44.4%) in general and in 1 out of 5 treated ones (20%). One patient recently developed neovascular membrane during a period of observation of 12 years and is currently awaiting treatment (fig. 4).

It is often doubtful whether the presence of intrinsic vasculature associated with melanocytic choroidal lesion represents a CNV or a malignant transformation. It is important to determine the reason for such a finding. A positive correlation between vascular density inside and around the naevus and its malignant transformation have been described in the past [16]. More recently, Ghassemi et al. presented quantitative results showing that surface microvasculature flow over the

FIGURE 4

Female, 69 years. A. Colour fundus photography at initial visit. B. Colour fundus photography after 12 years, documented development of choroidal neovascularization with presence of subretinal fluid and exudates around the lesion.



None of the observed lesions progressed to choroidal melanoma during the observation period.

## DISCUSSION

This is a small series of patients with CNV related to the presence of melanocytic nevus and with a median documented follow-up of 24 months which is the major strength of the study. The relative shortcomings are the retrospective character of the study and relatively small number of patients included. Nevertheless, CNV is a rare complication of choroidal naevus accounting for 1% of reported naevi [7, 9]. The largest series published comprised of 25 patients [12]. In our series the most frequent type of CNV was type I (occult). This is similar to the cohort reported by Pellegrini et al. [13] and Chiang et al. [14], with the prevalence of 64% and 100% respectively between groups. Type II (classic) of CNV was more common in the group described by Munie and Demirici and Zografos et al. reaching accordingly 83% and 100% of eyes, whereas type I in the former study was only 17% [12, 15].

melanoma is significantly lower than over the nevus. Another feature that may also be related to the presence of CNV is the SRF at the site of the choroidal lesion. Yu et al., suggested the appearance of SRF resulting from vascular compression around and over the lesion [17]. Those subtle features can be used to determine if the vasculature and SRF seen on multimodal imaging is a result of tumour compression of surrounding tissues or a CNV related to the chronicity of the benign lesion.

The diagnostic relevance of subretinal fluid related to a melanocytic lesion has long been investigated. In 1995 Shields et al., published a hallmark paper in the field of ocular oncology, identifying 5 clinical features of melanocytic choroidal lesions related to the probability of malignant transformation [4]. However, in that era only the subretinal fluid clinically visible was relevant. With the development of OCT the presence of subretinal fluid accompanying the lesion can be objectively assessed [6] and this led to the changes of Shields mnemonic To Find Small Ocular Melanoma into To Find Small Ocular Melanoma Doing Imaging (T – thickness  $> 2$  mm in ultrasound examination, F – subretinal fluid, S – Snellen visual acuity

≤ 20/50, O – orange pigment in autofluorescence, M – melanoma acoustic hollowness in ultrasound examination, DIM – diameter > 5 mm on fundus photography) – very useful in everyday practice [2, 4, 5]. However, the presence of subretinal fluid may be misleading for unexperienced ophthalmologists if it is associated with RPE changes overlying the nevus. Since the introduction of non-invasive OCTA, research on the nature of such fluid and its sources has been carried out.

There are only a few series of nevus-related CNV published in the literature [10, 12–15, 18]. Like in our study, the majority of the nevi with accompanying CNV in all groups described by other authors were pigmented, with its incidence ranging from 67% to 91% [10, 12, 13]. The more common apical location of the nevus, which is similar to our findings, was described in two papers [10, 13]. What is interesting, 100% of the CNV associated with nevus in the group described by Munie and Demirici were located at the margin of the lesion [12].

Pellegrini et al. recognized 2 vascular presentations of the studied CNV that could be evaluated on the OCTA – “sea-fan” and “filamentous”, with a 73% prevalence of the former and 27% of the latter [13]. In our group “sea-fan” appearance observed in the OCTA was also more common with an incidence of 55.6%. 2 CNVs’ morphology in our group could not be clearly defined due to the artifacts present on OCTA scans. There is a lack of information on such feature in the results of other previously mentioned studies.

5 patients in our series required treatment due to the progression of visual acuity loss. 2 patients who presented with an excessive amount of fluid at the initial visit were treated with TTT and then immediately referred for intravitreal anti-VEGF. 2 other patients received anti-VEGF without previous laser treatment. 2 of them responded well to anti-VEGF treatment (Snellen lines gain), one response can be considered satisfactory in terms of stable BCVA and one patient (after TTT and anti-VEGF) lost 4 lines in Snellen visual acuity test, though her vision remained better than 0.5 at the last

visit. One patient was treated with TTT only with the final Snellen visual acuity reaching 0.02 – this poor outcome is related to the naevus and accompanying CNV located in the fovea resulting in the fibrous changes involving the centre of the macula. The treatment options described in the literature comprise of argon laser, TTT, PDT, anti-VEGF and combined therapies. Argon laser was used mainly in the past for the extrafoveal lesions, due to the inevitable destruction of the treated areas, but it was proven to be effective in such cases [9, 19]. TTT alone, to our knowledge, has been described as a treatment for naevus-related CNV in only one article [20]. Although it has been widely studied as a treatment option for CNV in age-related macular degeneration, its role in dealing with CNV accompanying choroidal naevus is unclear [20, 21]. Photodynamic therapy seems to be a promising option for such treatment, however results of such management found in literature are not consistent in terms of improvement, with better outcomes as a rescue therapy combined with anti-VEGF for refractory cases of anti-VEGF monotherapy [12, 22–24]. In our study, treatment with anti-VEGF proved to be effective in preserving the visual acuity in terms of stabilizing or improving the visual outcomes of the therapy.

## CONCLUSIONS

The naevus related CNV is a rare finding, but it can be responsible for visual impairment and leakage of the subretinal fluid. In our series type I of CNV predominated but the results from other series are equivocal, considering the most common type. The response for our patients treated with anti-VEGF was satisfactory in 75% of cases. The weakness of this study, being the small series of patients, mainly contributes to the rarity of the CNV complicating the presence of the choroidal naevus. Thus, further research into this uncommon entity is still required.

*Figures: from the author's own materials.*

## CORRESPONDENCE

assistant prof. Iwona Rospond-Kubiak, MD, PhD

Department of Ophthalmology,  
Poznan University of Medical Sciences  
60-572 Poznań, ul. Szamarzewskiego 84  
e-mail: irospondkubiak@ump.edu.pl

## ORCID

Emilia Zwolińska – ID – <http://orcid.org/0000-0002-6667-6850>  
Iwona Rospond-Kubiak – ID – <http://orcid.org/0000-0002-8395-9588>

## References

1. Shields JA, Shields CL. Intraocular Tumors: An Atlas and Textbook [Internet]. Lippincott Williams & Wilkins; 2008. (Intraocular Tumors: An Atlas and Textbook). <https://books.google.nl/books?id=SYXYDY2DPtAC> (access: 21.11.2022).
2. Shields CL, Lally SE, Dalvin LA et al. White paper on ophthalmic imaging for choroidal nevus identification and transformation into Melanoma. 2021; 10(2): 1-10.

3. Kivelä T, Eskelin S. Transformation of Nevus to Melanoma. *Ophthalmology*. 2006; 113(5): 887-888.e1.
4. Shields CL, Shields JA, Kiritli H et al. Risk Factors for Growth and Metastasis of Small Choroidal Melanocytic Lesions. *Ophthalmology*. 1995; 102(9): 1351-61.
5. Shields CL, Dalvin LA, Ancona-Lezama D et al. Choroidal nevus imaging features in 3,806 cases and risk factors for transformation into melanoma in 2,355 cases. 2019; 39: 1840-51.
6. Fung AT, Guan R, Forlani V et al. Subclinical subretinal fluid detectable only by optical coherence tomography in choroidal naevi – the SON study. *Eye*. 2021; 35(7): 2038-44.
7. Naumann G, Hellner K, Naumann L et al. Pigmented nevi of the choroid: clinical study of secondary changes in the overlying tissues. *Trans Am Acad Ophthalmol Otolaryngol*. 1971; 75: 110-23.
8. Gass J. Problems in the differential diagnosis of choroidal nevi and malignant melanoma. XXXIII Edward Jackson Memorial lecture. *Trans Sect Ophthalmol Am Acad Ophthalmol Otolaryngol*. 1977; 83(1): 19-48.
9. Callanan DG, Lewis ML, Byrne SF et al. Choroidal Neovascularization Associated With Choroidal Nevi. *Arch Ophthalmol*. 1993; 111(6): 789-94.
10. Papastefanou VP, Nogueira V, Hay G et al. Choroidal naevi complicated by choroidal neovascular membrane and outer retinal tubulation. *Br J Ophthalmol*. 2013; 97(8): 1014-9.
11. Kanski JJ. *Clinical ophthalmology: a systematic approach*. 5 ed. Edinburgh: Butterworth-Heinemann; 2003.
12. Munie MT, Demirci H. Management of Choroidal Neovascular Membranes Associated with Choroidal Nevi. *Ophthalmol Retina*. 2018; 2(1): 53-8.
13. Pellegrini M, Corvi F, Say EAT et al. Optical coherence tomography angiography features of choroidal neovascularization associated with choroidal nevus. *Retina*. 2018; 38(7): 1338-46.
14. Chiang A, Bianciotto C, Maguire JJ et al. Intravitreal bevacizumab for choroidal neovascularization associated with choroidal nevus. *Retina*. 2012; 32(1): 60-7.
15. Zografos L, Mantel I, Schalenbourg A. Subretinal Choroidal Neovascularization Associated with Choroidal Nevus. *Eur J Ophthalmol*. 2004; 14(2): 123-31.
16. Zidlik V, Brychtova S, Uvirova M et al. The Changes of Angiogenesis and Immune Cell Infiltration in the Intra- and Peri-Tumoral Melanoma Microenvironment. *Int J Mol Sci*. 2015; 16(12): 7876-89.
17. Yu MD, Dalvin LA, Ancona-Lezama D et al. Choriocapillaris Compression Correlates with Choroidal Nevus-Associated Subretinal Fluid: OCT Analysis of 3431 Cases. *Ophthalmology*. 2020; 127(9): 1273-6.
18. Cennamo G, Montorio D, Fossataro F et al. Optical coherence tomography angiography in quiescent choroidal neovascularization associated with choroidal nevus: 5 years follow-up. *Eur J Ophthalmol*. 2021; 31(5): NP111-5.
19. Folk JC, Weingeist TA, Coonan P et al. The Treatment of Serous Macular Detachment Secondary Choroidal Melanomas and Nevi. *Ophthalmology*. 1989; 96(4): 547-51.
20. Parodi MB. Transpupillary thermotherapy for subfoveal choroidal neovascularization associated with choroidal nevus. *Am J Ophthalmol*. 2004; 138(6): 1074-5.
21. Caminal JM, Mejia-Castillo KA, Arias L et al. Subthreshold transpupillary thermotherapy in management of foveal subretinal fluid in small pigmented choroidal lesions. *Retina*. 2013; 33(1): 194-9.
22. García-Arumí J, Amselem L, Gunduz K et al. Photodynamic therapy for symptomatic subretinal fluid related to choroidal nevus. *Retina*. 2012; 32(5): 936-41.
23. Pointdujour-Lim R, Mashayekhi A, Shields JA et al. Photodynamic therapy for choroidal nevus with subfoveal fluid. *Retina*. 2017; 37(4): 718-23.
24. Stanescu D, Wattenberg S, Cohen SY. Photodynamic therapy for choroidal neovascularization secondary to choroidal nevus. *Am J Ophthalmol*. 2003; 136(3): 575-6.

**Authors' contributions:**

Emilia Zwolińska: collected the patients' data, prepared and drafted the manuscript;  
Iwona Rospond-Kubiak: was responsible for the clinical management of the patients,  
revised the manuscript.

**Conflict of interest:**

None.

**Financial support:**

None.

**Ethics:**

The content presented in the article complies with the principles of the Helsinki Declaration, EU directives and harmonized requirements for biomedical journals.