

Exudative retinal detachment and optic disc swelling in the course of posterior scleritis: case study and literature review

Małgorzata Michali, Rafał Pławszewski, Edyta Sutor

Clinical Department of Ophthalmology, Collegium Medicum in Opole, University of Opole
Head: Rafał Pławszewski, MD, PhD



HIGHLIGHTS

Posterior scleritis is a condition that requires systemic treatment.

First line of treatment is mainly based on topical steroid therapy and oral non-steroidal anti-inflammatory drugs.

Systemic steroid therapy is introduced when the first line of treatment is ineffective.

Immunosuppressive treatment is necessary if the disease process cannot be controlled with steroids.

ABSTRACT

Objectives: The objective of the present paper is to present a rare case of posterior scleritis with exudative retinal detachment and optic disc oedema.

Materials: The paper discusses a case of a 28-year-old patient with unilateral posterior scleritis, exudative retinal detachment and optic disc oedema. The patient presented with reduced visual acuity and inflammation within his right eyeball coat.

Test results: Upon admission, retinal detachment in all quadrants was diagnosed, with subretinal exudate, choroidal folds, but no pathology involving the anterior segment. B projection ultrasound revealed thickening of the posterior sclera of around 2.0 mm and complete retinal detachment in the right eye. Visual acuity results were OD = 1/50 Sc, OS = 45/50 Sc. Elevated intraocular pressure of the right eye was detected at 44.0 mmHg. A CT scan of the orbits with contrast revealed significant asymmetry of the eyeballs (right 22 × 22 mm, left 21 × 21 mm) as well as posterior thickening of the right eyeball coat to 2.0 mm. On top of that, on the second day of the patient's hospital stay, an ophthalmic exam showed obscured borders of the right optic nerve. Systemic treatment was initiated, comprising steroids, non-steroidal anti-inflammatory drugs and intraocular pressure lowering drugs. Additionally, topical treatment was provided with regard to the right eye. A number of laboratory tests were carried out to rule out systemic diseases that could have caused posterior scleritis. After discharge, the patient received follow up care from the hospital's ophthalmology clinic and remained on topical and systemic steroids. Oral systemic steroid therapy was maintained over a period of a few months, with gradual dose reduction. At follow-up visits, his visual acuity remained stable at OD = 40/50 Sc, OS = 45/50 Sc.

Conclusions: Posterior scleritis is a condition that requires prompt diagnosis and systemic treatment.

Key words: retinal detachment, exudative retinal detachment, posterior scleritis, retina, optic disc oedema

INTRODUCTION

Posterior scleritis is a rare and underdiagnosed condition affecting the sclera. It is a disorder of the outer layer of the eye, most common in middle-aged women [1]. The inflammation may be limited to the eyeball only, or it may signal a serious systemic disease [1]. According to literature, the age of patients diagnosed with posterior scleritis ranges from 8 to 87 years [2]. An accurate diagnosis requires differentiating against other causes that may produce similar symptoms, such as intraocular or orbital tissue inflammation, or orbital, choroidal or metastatic tumours [3]. About half of all posterior scleritis cases are bilateral, with 50% occurring simultaneously in both eyes, and another 50% presenting with a temporal delay [4]. Only around 28.3% of patients with posterior scleritis are diagnosed with a systemic disease [3]. The percentage increases with the patient's age, though. Records show an increased risk of posterior scleritis resulting from a systemic disease in patients over the age of 50 [3]. At the same time literature suggests idiopathic posterior scleritis to account for around 70.7% of all cases [3], with only 28.3% of cases attributable to a systemic disease. The case reviewed in the present paper is of unilateral idiopathic posterior scleritis in a young male.

CASE STUDY

A 28-year-old male, a citizen of Ukraine, was admitted to the Ophthalmology Clinical Unit with rapid deterioration of vision in his right eye. According to the patient's account, the sudden, painless deterioration of vision occurred 4 days previously. He denied increased physical exertion or any injury to the right eye. The medical history included a penetrating injury to the cornea of the left eye some 15 years previously.

On admission, a diagnosis of exudative retinal detachment in the course of posterior scleritis was made, based on local presentation of the right eye, B-projection ultrasonography of the right eyeball and orbital computed tomography. The patient denied any chronic conditions. On the day of admission, retinal detachment in all quadrants was diagnosed, with subretinal exudate, choroidal folds, but no pathology involving the anterior segment (fig. 1). B-projection ultrasound revealed thickening of the posterior sclera of around 2.00 mm and complete retinal detachment in the right eye (fig. 2). Visual acuity results were OD = 1/50 Sc, OS = 45/50 Sc. Elevated intraocular pressure of the right eye was detected at 44.0 mmHg. An ophthalmic examination did not show significant thickening of the choroid or ciliary body. No choroid detachment was observed, either. These signs helped rule out choroidal effusion.

Further testing involved a CT scan of the orbits with contrast, which revealed significant asymmetry of the eyeballs (right 22 × 22 mm, left 21 × 21 mm) as well as posterior

FIGURE 1

Fundal photo of the right eye showing optic disc oedema, choroidal folds, exudative retinal detachment and Paton's lines prior to initiation of treatment.

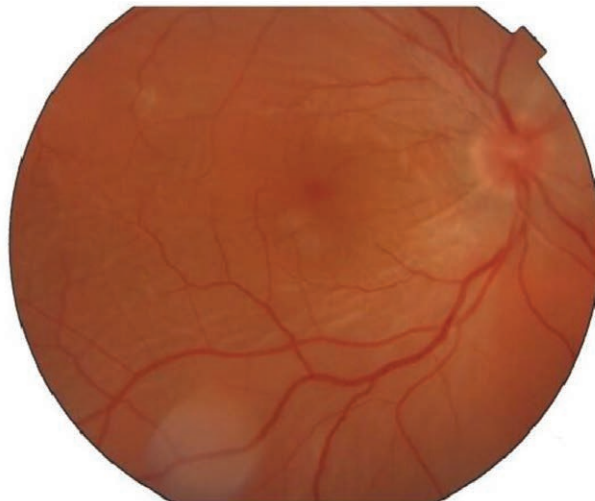
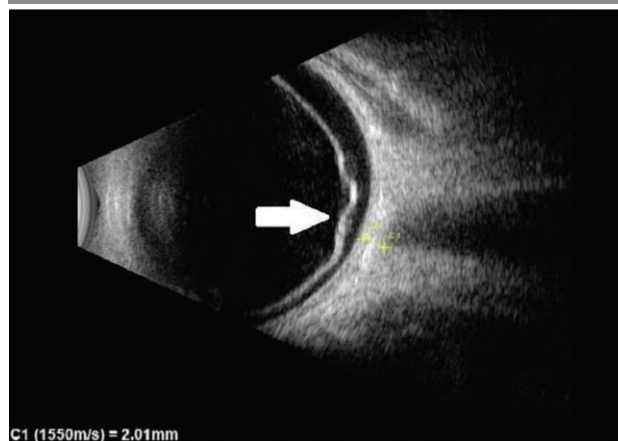


FIGURE 2

Ultrasound examination of the right eyeball in B-projection prior to treatment initiation. Both thickening of the posterior sclera and complete retinal detachment in the right eye are visible (arrow).



thickening of the right eyeball coat to 2.0 mm (fig. 3). On top of that, on the second day of the patient's hospital stay, an ophthalmic exam showed obscured borders of the right optic nerve. The overall clinical picture indicated exudative retinal detachment in the right eye in the course of posterior scleritis (fig. 4).

The patient had internal medicine, dental and ENT consultations. The dental examination revealed inflammatory foci local to three teeth; a subsequent extraction of all three was performed. No abnormalities were found in the ENT and internal medicine examinations. Further testing included

FIGURE 3

CT image showing thickening of the posterior part of the right eyeball. Status prior to initiation of treatment (arrow).

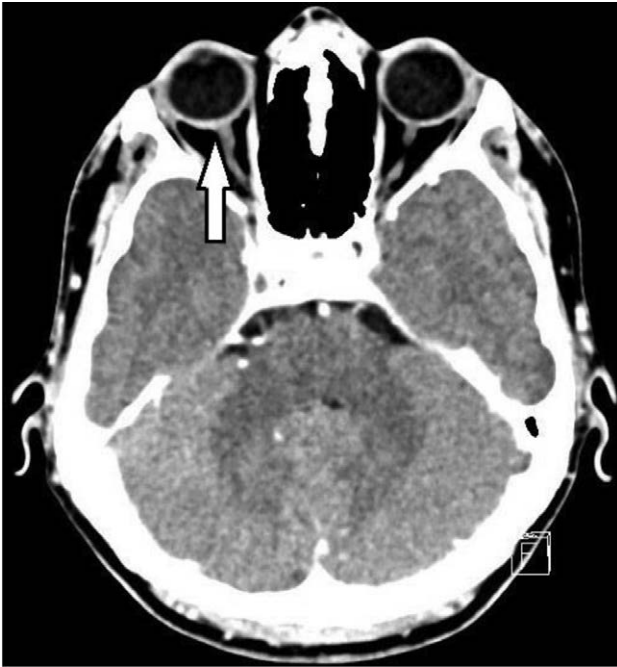
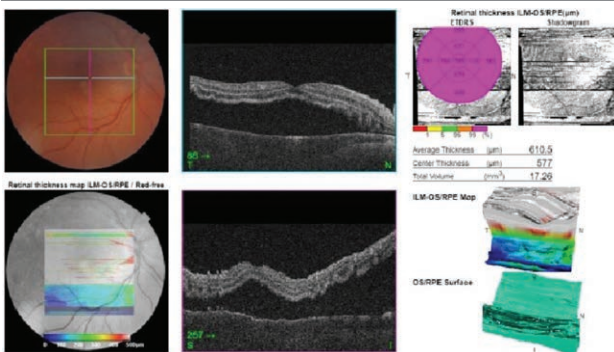


FIGURE 4

OCT scan of the right eye showing exudative retinal detachment prior to treatment initiation. Hyporeflective fluid space is visible under the neurosensory retina. Central retinal thickness at the fovea is 785 μm .



a chest X-ray, which also ruled out abnormalities. Due to optic disc oedema, elevated intraocular pressure and significant visual impairment, a decision was taken to initiate treatment urgently, prior to completing the full diagnostic workup. Hyperosmotic agent, mannitol (at 5 ml/kg body weight, in 20% aqueous solution I.V.), was administered to lower intraocular pressure, together with systemic carbonic anhydrase inhibitor, acetazolamide (at a dose of 250 mg 2 × daily, orally). Non-steroidal anti-inflammatory treat-

ment with naproxen (at a dose of 500 mg 2 × daily, orally) was introduced together with systemic steroid therapy with methylprednisolone (at a dose of 15 mg/kg/24 h I.V.) [3]. Additionally, topical treatment was provided with regard to the right eye: 2% dorzolamide + 0.5 timolol 2 × daily, 0.2% brimonidine 2 × daily, 0.1% dexamethason 5 × daily, and cycloplegic agents 3 × daily.

Over the course of the patient's hospital stay, the right eye condition stabilized. Intraocular pressure-lowering drugs were withdrawn gradually. Intravenous steroid therapy with methylprednisolone was continued for 10 days, with the dose reduced step by step. The patient continued to receive systemic oral steroid therapy with prednisolone (at a dose of 1 mg/kg/24 h).

A number of laboratory tests were carried out to look for systemic diseases that could have caused posterior scleritis. As a first step, the results of tests (urinalysis, C-reactive protein concentration, immunological parameters, auto antibody titers, uric acid concentration) and a rheumatology consultation ruled out rheumatological diseases. Infectious diseases were also taken into consideration. Test results helped rule out syphilis, tuberculosis, chickenpox, Lyme disease, toxoplasmosis as well as other infectious diseases.

Over the course of further hospitalization, systemic steroid therapy, anti-inflammatory treatment and topical treatment were continued. On the 10th day of the patient's hospital stay, significant improvement in the right eye condition was observed (fig. 5). Visual acuity results were OD = 40/50 Sc. Intraocular pressure of the right eye was 12 mmHg. Ophthalmic exam revealed flattening of the retinal detachment in all quadrants of the right eye (fig. 6). As there were no indications for continued hospitalization in the Ophthalmology Unit, and the condition of the right eye had stabilized, the patient was discharged. He received follow up care from the hospital's ophthalmology clinic and continued topical and systemic steroids. Systemic steroid therapy was maintained over a period of a few months, with gradual dose reduction. At follow-up visits, his visual acuity remained stable at: OD = 40/50 Sc, OS = 45/50 Sc. In ophthalmic exams, residual flat retinal detachment in the lower quadrants persisted. Slow reduction of the steroid dose helped prevent the recurrence of scleritis. With no recurrence, immunosuppressive treatment was not necessary.

CONCLUSIONS

Posterior scleritis is characterized by highly variable clinical presentation. Making an accurate as well as prompt diagnosis requires particular attention on the part of the clinician. Furthermore, the quick introduction of systemic treatment is necessary. Furthermore, treating patients with this type of condition is a multidisciplinary effort, involving various medical specializations. The treatment itself is a lengthy

FIGURE 5

OCT scan of the right eye showing exudative retinal detachment after 10 days of treatment. The hyporeflective fluid space under the neurosensory retina is significantly flattened. Central retinal thickness at the fovea is 598 μm .

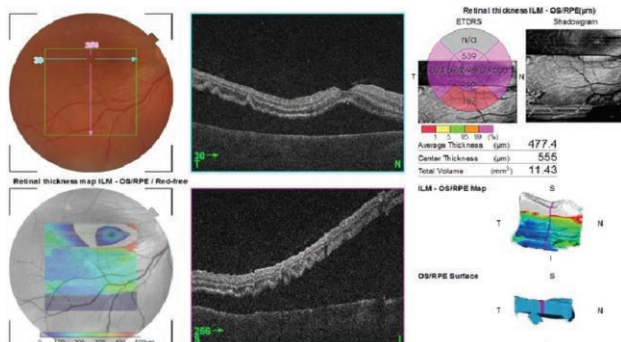
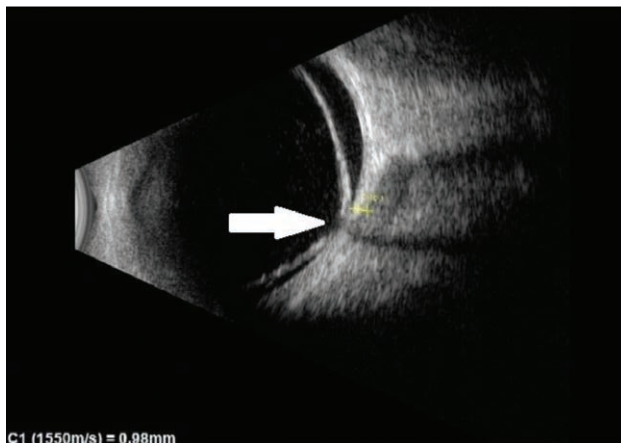


FIGURE 6

Ultrasound examination of the right eyeball in B-projection after 10 days of treatment: significant reduction in the thickening of the posterior sclera is visible. Both significant reduction in the posterior scleral thickening and flattening of the hypochoic space under the neurosensory retina are visible (arrow).



and unpredictable process, too. The most common symptoms of posterior scleritis include pain in or around the eyeball (61.11%) and headache (27.22%) [1]. Typical signs

the condition presents with include reduced visual acuity (50%), exudative retinal detachment, optic disc oedema (33.33%) [1], choroidal folds and subretinal exudates. The subretinal fluid is of retinal or choroidal vascular origin [5]. Available literature suggests inflammation to be a key factor associated with the development of exudative retinal detachment [6]. A combination of the clinical presentation and the visualization of scleral thickening in B-projection ultrasonography of the eyeball may help the clinician to reach an accurate diagnosis. Fluid in the space below Tenon's capsule gives the characteristic "T" sign [7] occurring in around 33.3% of patients with posterior scleritis [8]. The population mean scleral thickness in patients without signs of inflammation is 1.09 ± 0.29 mm, while in patients with posterior scleritis the respective value is 2.51 ± 0.81 mm [9, 10]. The first line of treatment is mainly based on topical steroid therapy and oral non-steroidal anti-inflammatory drugs. Systemic steroid therapy is introduced when the first line of treatment is ineffective, with additional clinical reasons supporting the decision [11]. Greater benefit is obtained with higher doses of steroids. It is important not to miss potential benefits steroids could provide by prescribing too low a dose. In the case described here, high dose steroid therapy was administered given the patient's young age and absence of comorbidities. The benefits of the aforementioned choice outweighed the possible side effects. Literature suggests that scleritis recurs when the steroid dose is reduced too quickly to < 0.5 mg/kg/24 h (in about 69.2% of patients) [12]. The key to preventing scleritis recurrence is to reduce the steroid dose slowly and to monitor the patient regularly, carefully checking for possible side effects caused by steroid therapy. Occasionally immunosuppressive treatment is introduced, too, when the disease process cannot be controlled with steroids [7]. Immunosuppressive treatment is necessary if the patient does not tolerate steroids [12]. Undoubtedly, a major advantage of immunosuppressive treatment is its possible long term character. Results obtained with immunosuppressive drugs are comparable to those achieved with steroids [12]. The case presented in the paper demonstrates the significant role the ophthalmologist plays in the diagnostic and treatment process.

Figures: from the author's own materials.

CORRESPONDENCE

Małgorzata Michali, MD

Clinical Department of Ophthalmology,
Collegium Medicum in Opole
45-401 Opole, al. W. Witosa 26
e-mail: malgorzata.michali@gmail.com

ORCID

Małgorzata Michali – ID – <http://orcid.org/0000-0001-6034-9210>

References

1. González-López JJ, Lavric A, Dutta Majumder P et al. Bilateral Posterior Scleritis: Analysis of 18 Cases from a Large Cohort of Posterior Scleritis. *Ocul Immunol Inflamm*. 2016; 24(1): 16-23. <http://doi.org/10.3109/09273948.2015.1045085>.
2. Dave VP, Mathai A, Gupta A. Combined anterior and posterior scleritis associated with central retinal vein occlusion: a case report. *J Ophthalmic Inflamm Infect*. 2012; 2(3): 165-8. <http://doi.org/10.1007/s12348-012-0066-x>.
3. McCluskey PJ, Watson PG, Lightman S et al. Posterior scleritis: clinical features, systemic associations, and outcome in a large series of patients. *Ophthalmology*. 1999; 106(12): 2380-6. [http://doi.org/10.1016/S0161-6420\(99\)90543-2](http://doi.org/10.1016/S0161-6420(99)90543-2).
4. Shukla D, Agrawal D, Dhawan A et al. Posterior scleritis presenting with simultaneous branch retinal artery occlusion and exudative retinal detachment. *Eye (London)*. 2009; 23(6): 1475-7. <http://doi.org/10.1038/eye.2008.217>.
5. Ghazi NG, Green WR. Pathology and pathogenesis of retinal detachment. *Eye (London)*. 2002; 16(4): 411-21. <http://doi.org/10.1038/sj.eye.6700197>.
6. Shah DN, Al-Moujahed A, Newcomb CW et al. Exudative Retinal Detachment in Ocular Inflammatory Diseases: Risk and Predictive Factors. *Am J Ophthalmol*. 2020; 218: 279-87. <http://doi.org/10.1016/j.ajo.2020.06.019>.
7. Kellar JZ, Taylor BT. Posterior Scleritis with Inflammatory Retinal Detachment. *West J Emerg Med*. 2015; 16(7): 1175-6. <http://doi.org/10.5811/westjem.2015.8.28349>.
8. Liu Z, Zhao W, Tao Q et al. Comparison of the clinical features between posterior scleritis with exudative retinal detachment and Vogt-Koyanagi-Harada disease. *Int Ophthalmol*. 2022; 42(2): 479-88. <http://doi.org/10.1007/s10792-021-02064-w>.
9. Dong ZZ, Gan YF, Zhang YN et al. The clinical features of posterior scleritis with serous retinal detachment: a retrospective clinical analysis. *Int J Ophthalmol*. 2019; 12(7): 1151-7. <http://doi.org/10.18240/ijo.2019.07.16>.
10. Zhu M, Tang A, Amatya N et al. Exudative retinal detachment. *Neth J Med*. 2011; 69(11): 527-30.
11. Shields RA, Schachar IH. Posterior Scleritis. *Ophthalmic Surg Lasers Imaging Retina*. 2019; 50(10): 660. <http://doi.org/10.3928/23258160-20191009-11>.
12. Cheung CM, Chee SP. Posterior scleritis in children: clinical features and treatment. *Ophthalmology*. 2012; 119(1): 59-65. <http://doi.org/10.1016/j.ophtha.2011.09.030>.

Authors' contributions:

Małgorzata Michali: conceptualization, writing – original draft preparation, writing – review and editing; Rafał Pławszewski: resources, supervision; Edyta Sutor: resources, writing – review and editing, supervision.

All authors have read and agreed to the published version of the manuscript.

Conflict of interest:

None.

Financial support:

None.

Ethics:

The content presented in the article complies with the principles of the Helsinki Declaration, EU directives and harmonized requirements for biomedical journals.