

# When a large refractive error is found in children, should we immediately order electroretinography?

Mateusz Zabochnicki<sup>1</sup>, Dorota Pojda-Wilczek<sup>2,3</sup>

<sup>1</sup> Students' Scientific Society, Department of Ophthalmology, Faculty of Medical Sciences in Katowice  
Head: Prof. Ewa Mrukwa-Kominek, MD, PhD

<sup>2</sup> Department of Ophthalmology, Faculty of Medical Sciences in Katowice, Medical University of Silesia in Katowice  
Head: Prof. Ewa Mrukwa-Kominek, MD, PhD

<sup>3</sup> Kornel Gibiński University Clinic Centre of Medical University of Silesia in Katowice  
Head: Prof. Ewa Mrukwa-Kominek, MD, PhD



## HIGHLIGHTS

This paper shows benefits of early ERG in pediatric patients with large refractive errors in diagnosing of the retinal diseases.

## ABSTRACT

Electroretinography is a useful tool used in diagnosing retinal disorders. Refractive errors are a common and increasing group of abnormalities, which, if undiagnosed, may lead to complications. Physiologically, i.e., refraction of the child's eye, evolves from myopic or hyperopic after birth, towards emmetropic. However, high refractive errors tend to present with retinal diseases. Early electroretinography is a great diagnostic test that allows its detection. Because of that, it can help avoid loss of eyesight and prevent future implications. Unfortunately, low accessibility and interpretational difficulties are main barriers in wider implementation of that method.

**Key words:** refractive error; electroretinography, pediatric ophthalmology, retinal dystrophy

## INTRODUCTION

An eyeball starts to grow intensively from the moment the baby is born. Its size and refraction are influenced by genetic, environmental and ethnical factors. Among premature babies, low myopia is common (approx.  $-1.0$  D). During the child's first year of life, the eyeball becomes hyperopic (up to  $+1.25$  D at 6–8 months of age), and then, the refractive error decreases until the age of 8 years. Since then, most of the children will develop myopia [1].

Refractive errors are very common among children and range from 19% prevalence in newborns with myopia to 25% in young adults [2]. It shows the tendency to progress rapidly during childhood and reaches stability around the age of 15 years [3]. Myopia is the most common type of refractive error with a whole range of factors, including genetic and environmental one that play an important role [4]. Refractive errors, eg. high myopia, are proposed to be used as a good marker of eye pathologies [5]. Considering the most typical pediatric patients, eye dysfunction is the leading cause of refractive errors among children and in that group myopia is occurring most profoundly [6]. Examining a child might be challenging for the ophthalmologist if a child is not cooperating correctly. Light sedation or even general anesthesia become the only way to carry out the procedure [7].

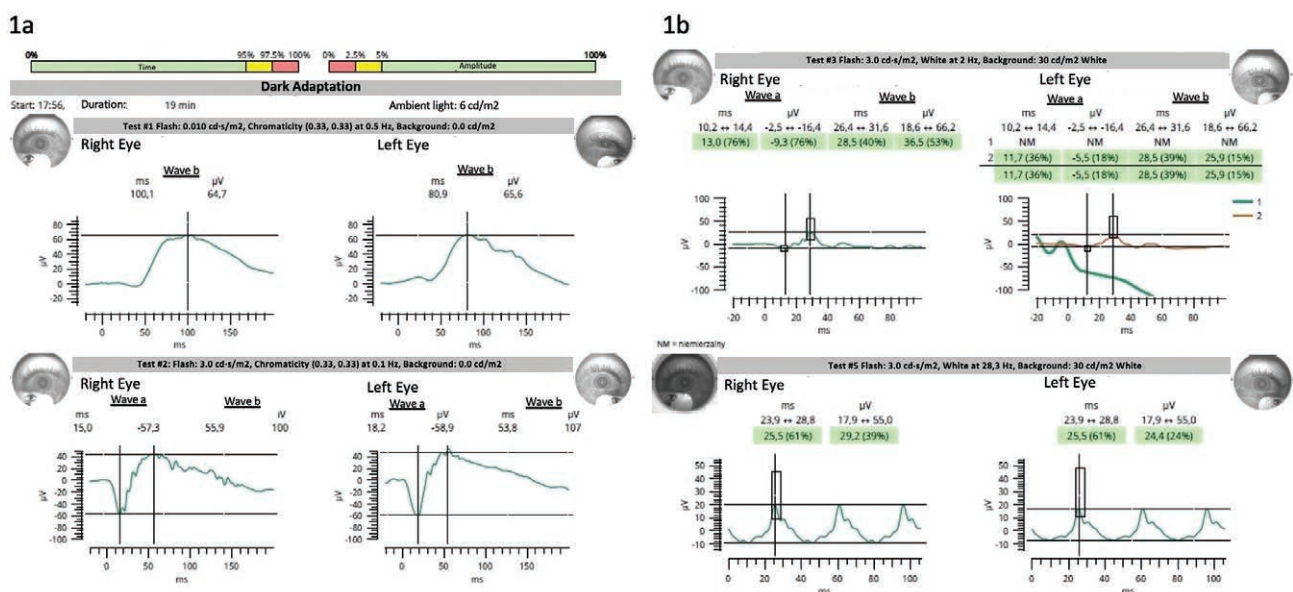
A whole range of screening tests might be performed to evaluate children and identify abnormalities: visual acuity test, stereoacuity test, ocular alignment test and autorefraction or skiascopy [8]. Undiagnosed and untreated refractive errors may impact children's psychical well-being,

social life and worsen their study skills [9]. Moreover, early detection of the refractive errors increases the chances of positive therapy outcome. The later the child is diagnosed, the more inevitable and irreversible refractive error is [10]. Electroretinography (ERG) is a crucial tool that allows for diagnosing retinal functional integrity and does not require verbal cooperation with the patient, which makes it useful in young children [11]. ERG mechanism is based on recording electrical potentials of the retina's cell sensitive to light, which allows for the assessment of retinal functioning [12]. Different types of ERG might be utilized, one of them is full-field ERG (ffERG). Its purpose is to distinguish between generalized outer and inner retinal abnormalities with usage of evoked retinal potentials [13]. There are some confirmed risk factors that should be taken into consideration when dealing with young patients with suspected refractive errors. Higher ametropia (above 6.0 D spherical and/or 1.5 D in astigmatism) significantly often coexists with retinal electrophysiological abnormalities. It was also hypothesized that retina affects eye development and emmetropization process and because of that retinal dysfunctions may lead to anomalies [14].

When it comes to refractive errors, the length of myopic eyes have been found to be notably longer than eyes with correct refraction [15]. Moreover, axial elongation of the eye stretches the retina and decreases photoreceptors density, which spaces them more widely [16]. High myopia (above 6.0 D) might lead to complications like retinal detachment, however not all patients develop refraction errors and retinal dysfunction. Also, there is no relation-

FIGURE 1

A 39-year-old woman with high myopia (right eye  $-9.0$  D and left eye  $-9.5$  D) and full visual acuity. Scotopic (fig. 1A) and photopic (fig. 1B) ffERG within normal limits.



ship between refraction error and retinal function [17, 18]. An example of normal fERG in a patient with high myopia is presented in figure 1. All fERG examinations presented in this paper were performed according to the ISCEV standard [13]. Portable device RETeval (LKC Technologies, Gaithersburg, USA) and sensor strip electrodes were used.

## PHYSIOLOGICAL ELECTRORETINOGRAPHY AND HEALTHY CHILD REFRACTION

ERG principle of operation is based on light. It is used to evoke, record, and later evaluate physiological impulses passing through sensorial structures of retina. According to the characteristic that is being examined, different light intensity, wavelength and dynamics is used [19]. There are three types of ERG: fERG, multifocal ERG and pattern ERG. Full-field type is using special Ganzfeld bowl to illuminate retina, pattern type is working with highly contrasted checkerboard and multifocal ERG is based on evaluating macula with the use of multiple hexagons shapes [20–22]. Focusing on fERG – the evaluation results are very useful in differential diagnosis of retinal abnormalities. The system requires few types of electrodes: recording electrodes (staying in contact with the skin, cornea, or conjunctiva) and reference electrodes (connected to orbital rim of the same eye as recording electrode). There is also ground electrode connected to the indifferent point, usually forehead or earlobe. Recommended protocol for ERG procedure includes 20 min of dark adaptation (DA) that enables assessment of rod dominated function of retina and 10 min of light adaptation (LA) to assess the cone function [13].

However, working with young and not always compliant patients may make diagnostic process, such as ERG, more difficult. Because such shortened and simplified algorithms have been introduced, they include reduced examination time, lack of corneal electrodes, and no pupil dilatation [23]. Standard ERG consists of two main waves: “a” and “b”. Ophthalmologist can assess their amplitude and implicit time (peak time) [7]. A-wave is characterized as the first negative deflection of the electroretinogram. It originates from activity of rod and cone photoreceptors. B-wave is a positive deflection at ERG and observed in the correct ERG should be higher than a-wave. It is generated by stimulation of bipolar, horizontal and amacrine cells. There is also a c-wave which presents as positive deflection after the b-wave, originating from hyperpolarized retinal pigment epithelium. Lastly, d-wave can also be spotted after intensive, prolonged light stimulation of bipolar cell in the cone [24, 25].

Physiologically, the mean amplitude of a-wave of photopic ERG expressed in microvolts ( $\mu\text{V}$ ) starts from around of  $4 \mu\text{V}$  in newly born children and rises up to around of  $13 \mu\text{V}$  in 17-years-olds. The duration of wave “a” expressed in milliseconds (ms), however decreases slightly from 27.5 ms to

24.5 ms. Another assessed factor is a/b complex and in that case amplitude growing with age can also be observed with decreased duration [26].

To measure children refraction, cycloplegia is required to exclude accommodation. After birth, eye refraction is usually ranging from  $-1.0 \text{ D}$  to  $-4.0 \text{ D}$  (myopia) or up to  $8.0 \text{ D}$  (hyperopia) with mean refraction around  $3.0 \text{ D}$  [27]. In the course of children growth and development, eyes usually become nearly emmetropic with possible hyperopia that is corrected with accommodational abilities of muscles [28]. With age, human eye’s optical power of visual components is decreasing gradually, but just enough to correct refractive errors, which is why emmetropization progresses [29].

## THE RELATIONSHIP BETWEEN REFRACTIVE ERRORS AND RETINAL DISEASES

High refractive dysfunctions occurring in childhood like high myopia (above  $6.0 \text{ D}$ ) are associated with ocular conditions. Logan et al., in a study examining children aged 3–10 years found that high myopia coexisted with retinal dystrophies (congenital stationary night blindness and achromatopsia) and amblyopia among 25% of children [2]. The examples of fERG in congenital stationary night blindness and achromatopsia associated with high myopia are presented in figure 2 and figure 3, respectively.

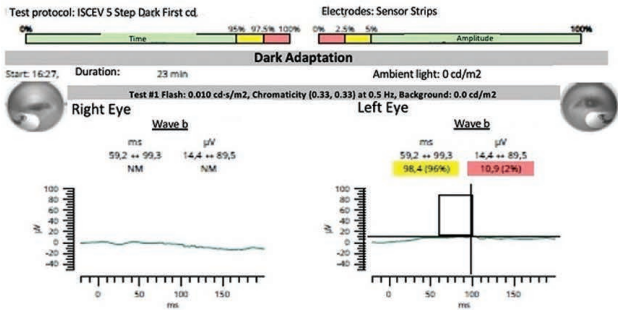
Moreover, high myopia can also be associated with systemic conditions. Marr et al. examined children older than 10 years with myopia above  $6.0 \text{ D}$  and concluded, similarly to Logan et al. study, that there is a significant association between refractive errors and ocular problems (38%) or systemic conditions regardless of ocular problem (54%), like developmental delay, prematurity or Down syndrome [5]. Another research, carried out in the group of 123 consecutive participants, presented that pediatric patients suffering from high spherical equivalent errors of refraction (myopia, hyperopia and astigmatism) were diagnosed more often with retinal dysfunction than other study participants with lower refraction errors. Moreover, not performing ERG in patients with high refraction errors might lead to incorrect clinical diagnoses and confusing real condition with others, such as ametropic amblyopia. These findings are supporting the thesis that retina is a significant factor influencing emmetropization of the human’s eye and its correct growth. Additionally, any abnormalities can possibly disrupt that process [14]. fERG of two brothers, 7- and 12-years old, suffering from nyctalopia since early childhood is presented in figure 4. fERG is typical for retinitis pigmentosa.

A 9-year-old girl suffered from low visual acuity from early childhood. It was attributed to her high myopia. Significantly abnormal retinal function was found in fERG and Severe Early Childhood Onset Retinal Dystrophy (SECORD) was suspected (fig. 5).

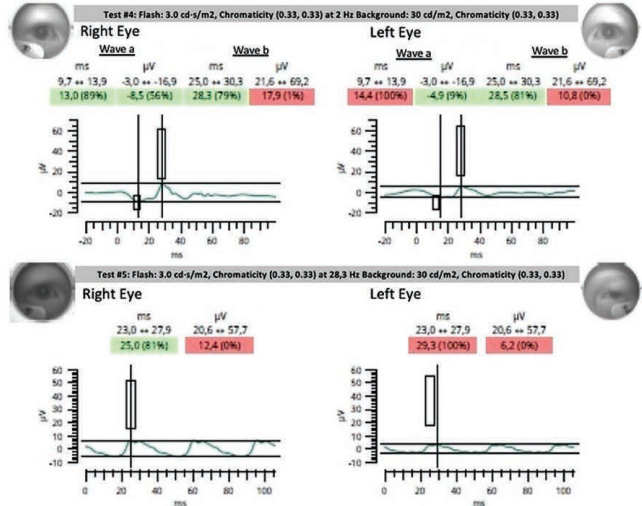
FIGURE 2

A 5-year-old boy, spherical equivalent (SE) of right eye refractive error -7.0 D (distance visual acuity [DVA] = 0.5; near visual acuity [NVA] = 0.5) and left eye -8.0 D (DVA = 0.2; NVA = 0.5) with congenital stationary night blindness type II (CSNB). fERG: in DA negative response (fig. 2A) and in LA decreased amplitudes of b-waves (fig. 2B) are seen. Abnormal function of bipolar cells was found in On-Off ERG protocol (fig. 2C). For comparing normal function of bipolar cells of 26-year-old woman is presented in figure 2D.

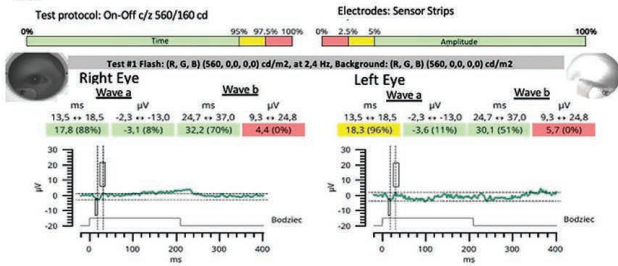
2a



2b



2c



2d

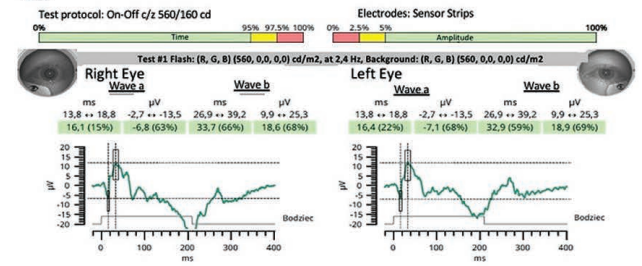
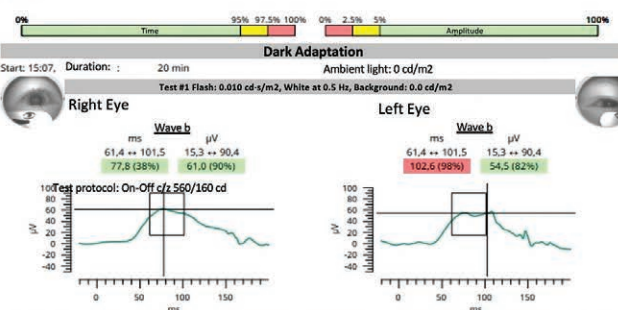


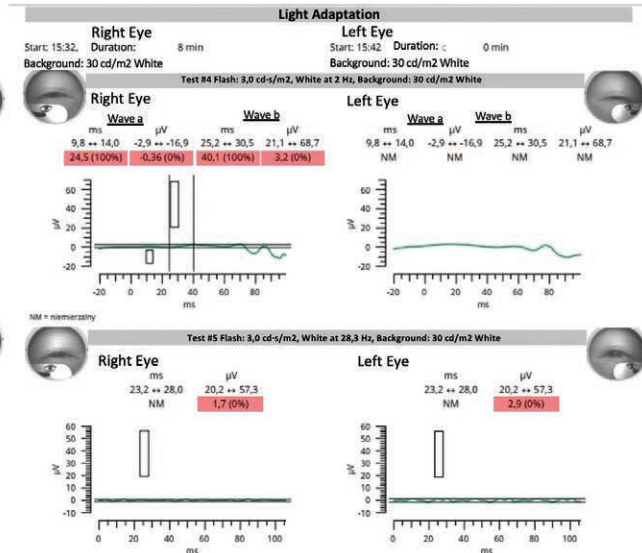
FIGURE 3

Achromatopsia. A 10-year-old boy: right eye / left eye SE: -10.0 / -9.0; DA ERG within normal limits (fig. 3A), LA ERG non-measurable (fig. 3B). The same results were found in his 12-year-old brother. DVA = 0.1-0.2; NVA = 3.0.

3a



3b



A 15-year-old girl suffered from high myopia and low vision. She had familial history of optic atrophy (patient's father and his family). Low function of retinal ganglion cells was confirmed in fERG in photopic negative response protocol (fig. 6).

### WHY SHOULD WE PERFORM ERG EARLY?

Early classification of pediatric patients is crucial to maintain eyesight and prevent future complications [14]. Certain diseases may remain asymptomatic or not diagnosed with other diagnostic procedures. It is also possible, if nec-

essary, to perform retinography in premature infants [30]. Ametropias like myopia and other retinal dysfunctions are being found in children that have been born prematurely [31]. In the case of hereditary diseases, it might be beneficial for patient's family to be tested as well, because they may have similar error [32]. Also, decreased retinal sensitivity can be found in myopic children [33].

For instance, in a 11-year-old girl with a history of retinopathy of prematurity, hydrocephalus, psychomotor retardation, divergent squint of the right eye, and low vision in both eyes. Normal LA ERG in both eyes means that the main problem of this patient is abnormal visual pathway and squint, not retinopathy (fig. 7).

FIGURE 4

Retinitis pigmentosa. fERG of two brothers, 7 and 12 years old. The younger brother right eye / left eye refractive error is -5.0 D / -4.5 D; DVA = 0.3 / 0.5; NVA = 1.0 / 0.75. The older brother right eye / left eye refractive error is -3.5 D spherical; -3.0 cylindrical / -3.0 D spherical; -3.0 cylindrical; DVA = 0.5 / 0.5; NVA = 0.5 / 0.5. The older brother has a few pigmentary changes on ocular fundus in both eyes. DA ERG is non-measurable or significantly reduced (fig. 4A, 4B). In LA ERG a-wave and b-wave amplitudes are very low and implicit times are significantly prolonged in younger brother (fig. 4C). More advanced changes are seen in older brother (fig. 4D).

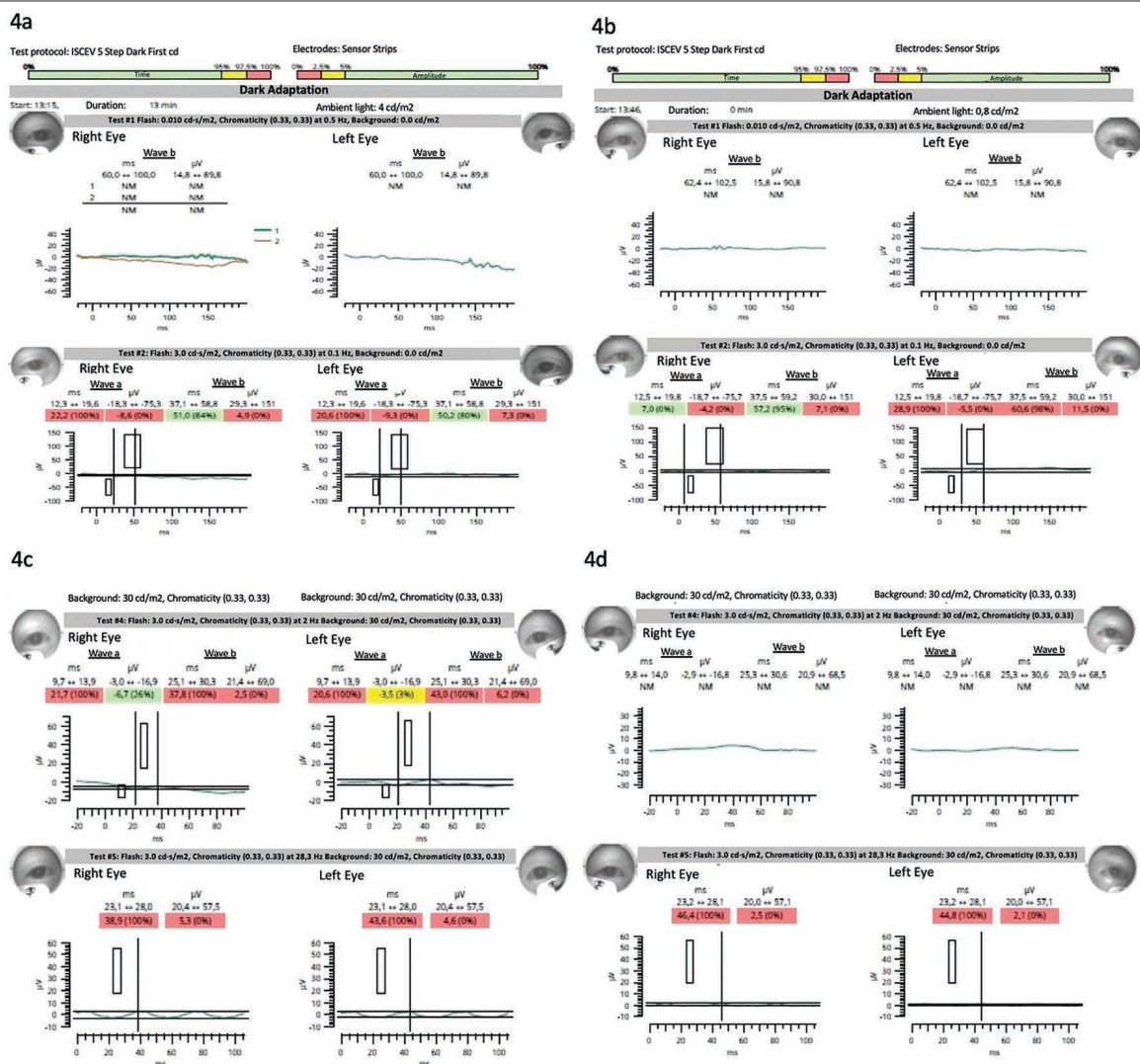


FIGURE 5

SECORD suspicion. A 9-year-old girl right eye / left eye SE -10.25 D / -11.0 D; DVA = 0.04 / 0.06; NVA = 6.0. DA and LA ERG is non-measurable (fig. 5A, 5B consecutively).

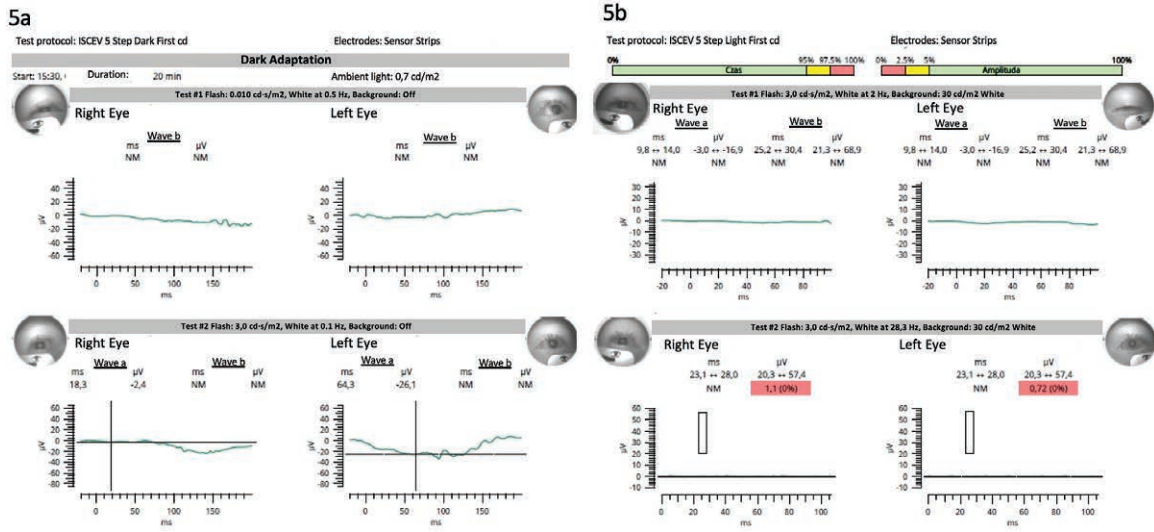


FIGURE 6

Familiar optic atrophy. A 15-year-old girl right eye / left eye SE -9.0 D / -8.0 D; DVA 0.06 / 0.08; NVA = 2.4 (both eyes open). fFERG is within normal limits (fig. 6A and 6B). Photopic negative response protocol revealed low amplitude of negative wave, which is attributed to ganglion cells' function (fig. 6C).

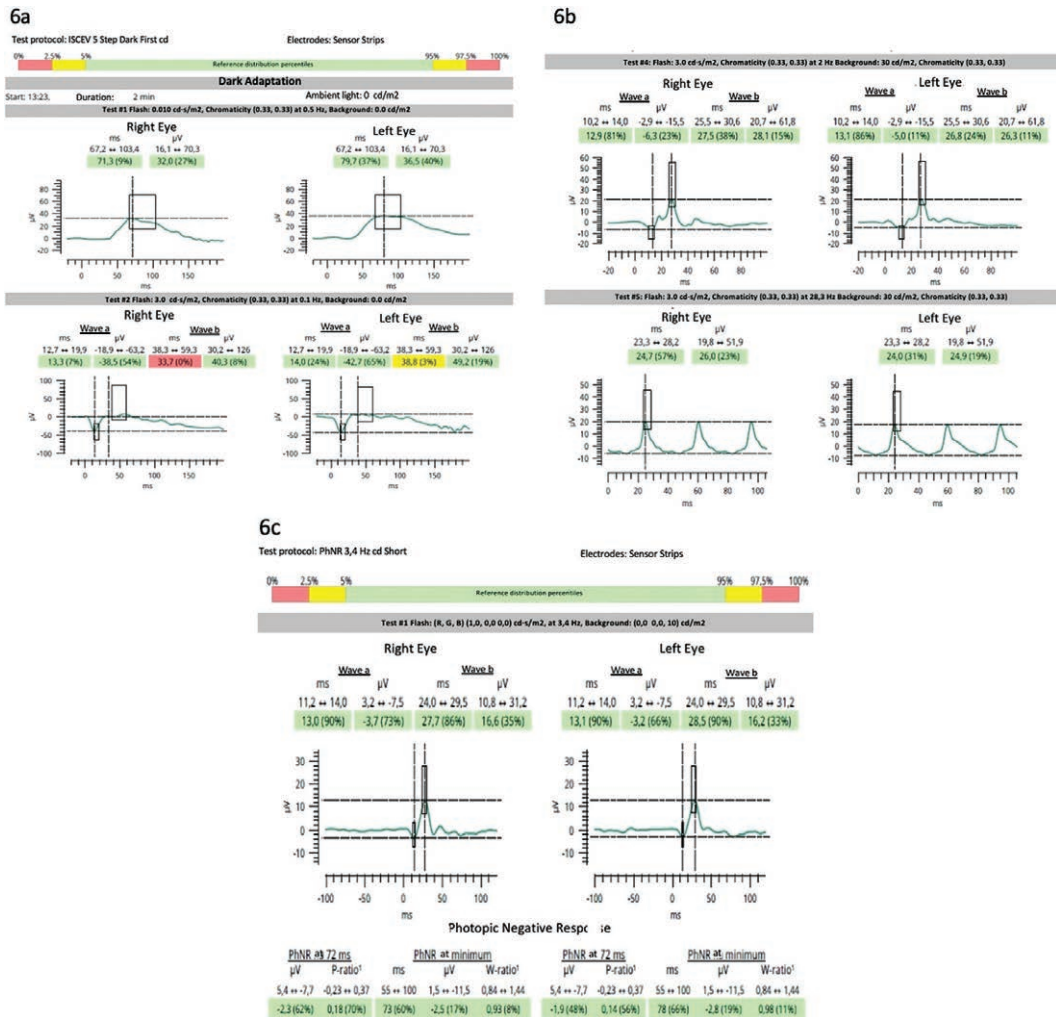
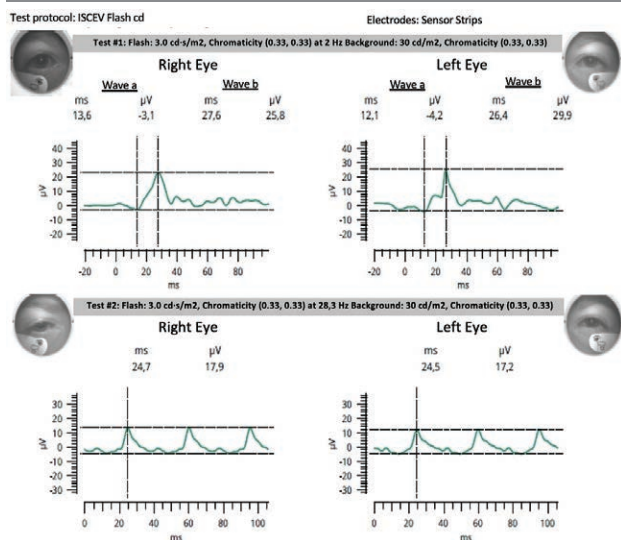


FIGURE 7

Normal LA ERG in both eyes. A 11-year-old patient right eye / left eye SE -4.5 D / -4.0 D; DVA = 0.2 / 0.4. Divergent squint of the right eye. Low vision is not caused by consequences of retinopathy of prematurity.



Focusing more deeply on specific diseases, the study on Leber Congenital Amaurosis found that patients may present with more than 6.0 D and no systemic abnormalities, but ERG test outcome proved some pathology [34]. Another example is a study in which certain haplotypes of opsin genes led to asymptomatic high myopia occurring in young patients and later progressed to the cone-rod dystrophy with deuteranopia and protanopia in older patients. However, after performing ERG it was possible to determine the group of patients that responded to the decreased number of cone photoreceptors [35]. It is also possible to discriminate between retinal dystrophy and optic nerve atrophy. Epidemiologically, research conducted in the United States revealed that in 2015 more than 174,000 children were visually impaired and in 69% of them it was due to uncorrected refractive error. Moreover, by 2060 this number is supposed to increase by 26% [36]. It is possible that properly planned screening and ERG testing could improve recogni-

tion of the visual impairments, reduce later complications, and improve treatment results [8]. Electroretinography can also be used to predict severity and progression of myopia [37].

Anisometric amblyopia may be caused not only by aniseikonia, but also by abnormal retinal function in eye with high refractive error. Early ERG helps to indicate the background of low vision and understand no improvement after treatment. High hypermetropia in some eyes is caused by the eye underdevelopment. An example of such a case can be a 5-year-old patient with anisometropia and amblyopia whose refractive error is 4.0 D in the right eye and 6.0 D in the left eye. DVA is 1.0 and 0.17 respectively. fERG revealed abnormal retinal function in DA and LA ERG in his left eye (fig. 8).

## CONCLUSIONS

Pediatric patients presenting with high myopia or high hypermetropia should undergo electroretinography, which is a good and sensitive examination that allows for to detect retinal abnormalities early. We consider high refractive defects as an urgent indication to perform it. Additionally, in case when patient is diagnosed with heteropsia ERG should also be considered.

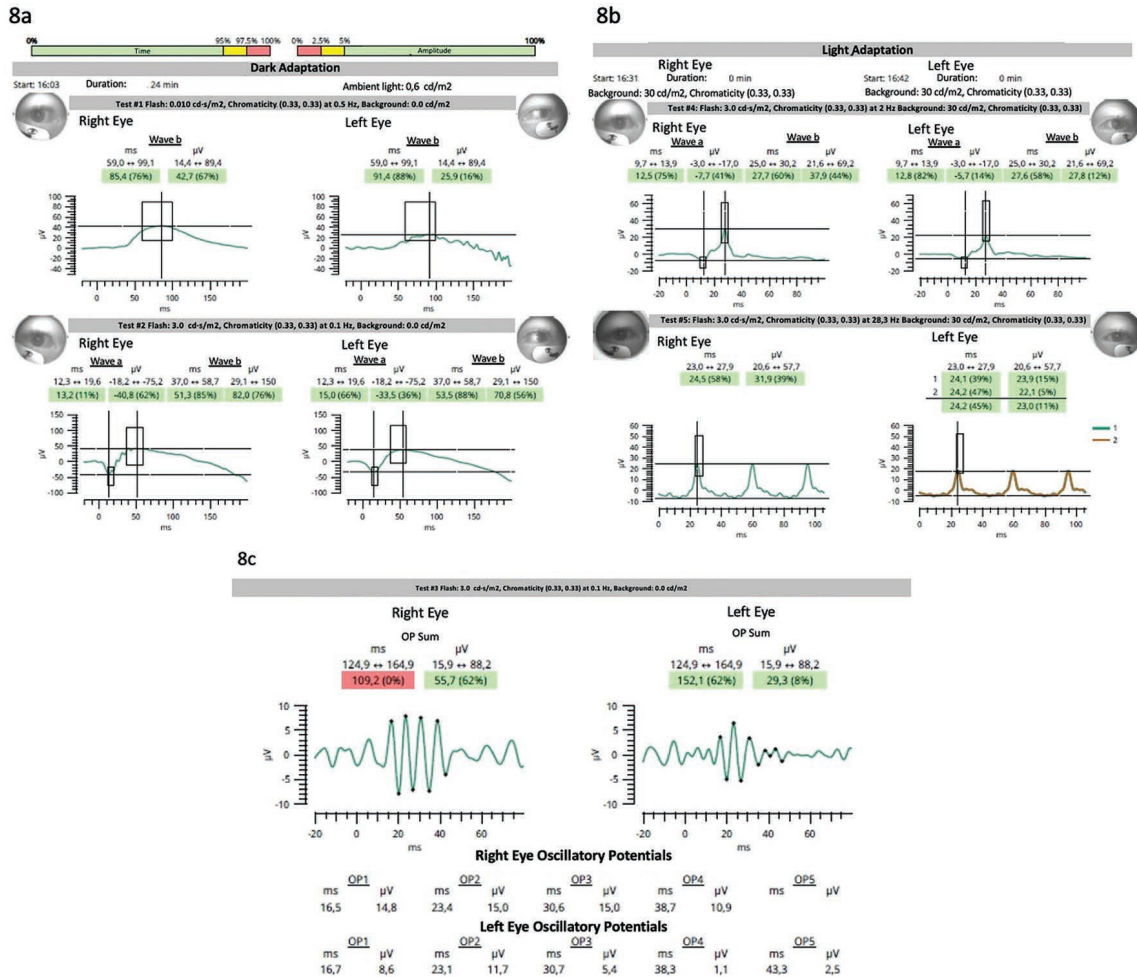
What are the general reasons why ERG is ordered rarely? The main causes are high price, interpretational difficulties, low accessibility in lower reference centers, prolonged time to receive the outcome because of a low number of specialized ophthalmologists that can evaluate the results of ERG. Nowadays, it is much easier to do ERG because easy applicable palpebral electrodes and portable devices make possible perform the examination in babies and small children, handicapped children, in any position (sitting, laying) and even under general anesthesia if it is required.

Gathering all of the benefits together – it is very favorable to perform electroretinography early among pediatric patients, because it allows to early recognize serious defects, may indicate on necessity of genetic diagnostics and is creating an opportunity to introduce therapy or prophylaxis early.

*Figures: from the authors' own materials.*

FIGURE 8

Unilateral underdevelopment of the retina. A 5-year-old boy right eye / left eye SE 4.0 D / 6.0 D; DVA = 1.0 / 0.17. FFERG abnormal in the left eye in DA and LA ERG (fig. 8A–C).



**CORRESPONDENCE**

**Mateusz Zabochnicki, MS**

Students' Scientific Society, Department of Ophthalmology, Faculty of Medical Sciences in Katowice, Medical University of Silesia in Katowice 40-514 Katowice, ul. Ceglana 35

**ORCID**

Mateusz Zabochnicki – ID – <http://orcid.org/0000-0002-6975-5693>  
 Doroa Pojda-Wilczek – ID – <http://orcid.org/0000-0002-7579-2546>

## References

1. Prost ME, Kocyla-Karczarewicz B, Chipczyńska B et al. Rozwój gałki ocznej u dziecka. Instytut „Pomnik – Centrum Zdrowia Dziecka” 2000: 2-5. [http://www.okulistykadziecieca.pl/images/zakres\\_badan/Rozw%C3%B3j\\_ga%C5%82ki\\_u\\_dziecka\\_.pdf](http://www.okulistykadziecieca.pl/images/zakres_badan/Rozw%C3%B3j_ga%C5%82ki_u_dziecka_.pdf) (access: 15.03.2023).
2. Logan NS, Gilmartin B, Marr JE et al. Community-Based Study of the Association of High Myopia in Children with Ocular and Systemic Disease. *Optom Vis Sci.* 2004; 81: 11-3.
3. Lee SS-Y, Mackey DA. Prevalence and Risk Factors of Myopia in Young Adults: Review of Findings From the Raine Study. *Front Public Health.* 2022; 10: 861044.
4. Pan C-W, Ramamurthy D, Saw S-M. Worldwide prevalence and risk factors for myopia: Prevalence and risk factors for myopia. *Ophthalmic Physiol Opt.* 2012; 32: 3-16.
5. Marr JE, Halliwell-Ewen J, Fisher B et al. Associations of high myopia in childhood. *Eye (Lond).* 2001; 15: 70-4.
6. Pi L-H, Chen L, Liu Q et al. Prevalence of Eye Diseases and Causes of Visual Impairment in School-Aged Children in Western China. *J Epidemiol.* 2012; 22: 37-44.
7. Camuglia JE, Greer RM, Welch L et al. Use of the electroretinogram in a paediatric hospital: The electroretinogram in children. *Clin Experiment Ophthalmol.* 2011; 39: 506-12.
8. Jonas DE, Amick HR, Wallace IF et al. Vision Screening in Children Aged 6 Months to 5 Years: Evidence Report and Systematic Review for the US Preventive Services Task Force. *JAMA.* 2017; 318: 845.
9. Alvarez-Peregrina C, Sánchez-Tena MÁ, Andreu-Vázquez C et al. Visual Health and Academic Performance in School-Aged Children. *IJERPH.* 2020; 17: 2346.
10. Epelbaum M, Milleret C, Buisseret P et al. The Sensitive Period for Strabismic Amblyopia in Humans. *Ophthalmology.* 1993; 100: 323-7.
11. Parness-Yossifon R, Mets MB. The electroretinogram in children. *Curr Opin Ophthalmol.* 2008; 19: 398-402.
12. Brodie SE. Tips and tricks for successful electroretinography in children. *Curr Opin Ophthalmol.* 2014; 25: 366-73.
13. Robson AG, Frishman LJ, Grigg J et al. ISCEV Standard for full-field clinical electroretinography (2022 update). *Doc Ophthalmol.* 2022; 144: 165-77.
14. Flitcroft DI. Retinal dysfunction and refractive errors: an electrophysiological study of children. *Br J Ophthalmol.* 2005; 89: 484-8.
15. Atchison DA, Jones CE, Schmid KL et al. Eye Shape in Emmetropia and Myopia. *Invest Ophthalmol Vis Sci.* 2004; 45: 3380.
16. Panda-Jonas S, Jonas JB, Jonas RA. Photoreceptor density in relation to axial length and retinal location in human eyes. *Sci Rep.* 2022; 12: 21371.
17. Perlman I, Meyer E, Haim T et al. Retinal function in high refractive error assessed electroretinographically. *Br J Ophthalmol.* 1984; 68: 79-84.
18. Ikuno Y. Overview Of The Complications Of High Myopia. *Retina.* 2017; 37: 2347-51.
19. Havens LT, Kingston ACN, Speiser DI. Automated methods for efficient and accurate electroretinography. *J Comp Physiol A.* 2021; 207: 381-91.
20. Fernandes A, Pinto N, Tuna AR et al. Can pattern electroretinography be a relevant diagnostic aid in amblyopia? – A systematic review. *Semin Ophthalmol.* 2022; 37: 593-601.
21. Hood DC, Odel JG, Chen CS et al. The Multifocal Electroretinogram. *J Neuroophthalmol.* 2003; 23: 225-35.
22. Birch DG. Standardized Full-Field Electroretinography: Normal Values and Their Variation With Age. *Arch Ophthalmol.* 1992; 110: 1571.
23. Marmoy OR, Moinuddin M, Thompson DA. An alternative electroretinography protocol for children: a study of diagnostic agreement and accuracy relative to ISCEV standard electroretinograms. *Acta Ophthalmologica.* 2022; 100: 322-30.
24. Mulak M, Pieniążek M, Misiuk-Hojło M. Elektrofizjologiczna diagnostyka zaburzeń widzenia w zespołach paranowotworowych. *Pol Prz Neurol.* 2008; 4: 199-202.
25. Pasmanter N, Petersen-Jones SM. A review of electroretinography waveforms and models and their application in the dog. *Vet Ophthalmol.* 2020; 23: 418-35.
26. Harden A, Adams GGW, Taylor DSI. The electroretinogram. *Arch Dis Child.* 1989; 64: 1080-7.
27. Enthoven CA, Tideman JW, Polling JR et al. The impact of computer use on myopia development in childhood: The Generation R study. *Prev Med.* 2020; 132: 105988.
28. Norton TT, Siegwart JT. Light levels, refractive development, and myopia – A speculative review. *Exp Eye Res.* 2013; 114: 48-57.
29. Saunders KJ. Early refractive development in humans. *Surv Ophthalmol.* 1995; 40: 207-16.
30. Mets MB, Smith VC, Pokorny J et al. Postnatal retinal development as measured by the electroretinogram in premature infants. *Doc Ophthalmol.* 1995; 90: 111-27.
31. Fulton AB, Hansen RM. Electroretinogram responses and refractive errors in patients with a history of retinopathy of prematurity. *Doc Ophthalmol.* 1995; 91: 87-100.

32. Goodman G, Ripps H. Electroretinography in the Differential Diagnosis of Visual Loss in Children. *Arch Ophthalmol*. 1960; 64: 221-35.
33. Chia A, Li W, Tan D et al. Full-field electroretinogram findings in children in the atropine treatment for myopia (ATOM2) study. *Doc Ophthalmol*. 2013; 126: 177-86.
34. Wagner RS, Caputo AR, Nelson LB et al. High Hyperopia in Leber's Congenital Amaurosis. *Arch Ophthalmol*. 1985; 103: 1507-9.
35. Orosz O, Rajta I, Vajas A et al. Myopia and Late-Onset Progressive Cone Dystrophy Associate to LVAVA/MVAVA Exon 3 Interchange Haplotypes of Opsin Genes on Chromosome X. *Invest Ophthalmol Vis Sci*. 2017; 58: 1834.
36. Varma R, Tarczy-Hornoch K, Jiang X. Visual Impairment in Preschool Children in the United States: Demographic and Geographic Variations From 2015 to 2060. *JAMA Ophthalmol*. 2017; 135: 610.
37. Luu CD, Foulds WS, Tan DTH. Features of the Multifocal Electroretinogram May Predict the Rate of Myopia Progression in Children. *Ophthalmology*. 2007; 114: 1433-8.

**Authors' contributions:**

Mateusz Zabochnicki: manuscript drafting, figure preparation; Dorota Pojda-Wilczek: manuscript drafting, ERG studies, figure preparation, supervision.

**Conflict of interest:**

None.

**Financial support:**

None.

**Ethics:**

The content presented in the article complies with the principles of the Helsinki Declaration, EU directives and harmonized requirements for biomedical journals.