

Surgical treatment of thyroid orbitopathy



**Mateusz Zabochnicki¹, Wojciech Szaraniec²,
Dorota Pojda-Wilczek^{2,3}**

¹ Students' Scientific Society, Department of Ophthalmology, Faculty of Medical Sciences in Katowice, Medical University of Silesia in Katowice, Poland
Head: Prof. Ewa Mrukwa-Kominek, MD, PhD

² Kornel Gibiński University Clinical Centre of Medical University of Silesia in Katowice, Poland
Head: Prof. Ewa Mrukwa-Kominek, MD, PhD

³ Department of Ophthalmology, Faculty of Medical Sciences in Katowice, Medical University of Silesia in Katowice, Poland
Head: Prof. Ewa Mrukwa-Kominek, MD, PhD

HIGHLIGHTS

Presented publication shows review of different surgical treatment options of thyroid orbitopathy including wall decompression, strabismus surgery, eyelid surgery and more.

ABSTRACT

Thyroid Orbitopathy is manifestation of Grave's Disease that affects eyes and orbital area. It occurs in the active and inactive phase, during which different signs are presented. When Thyroid Orbitopathy reaches its advanced phase it should be operated, to avoid complications like proptosis or optic nerve neuropathy. Usually, the first choice is orbital fat decompression. However, it is often not enough and bony decompression is necessary. Surgery of the strabismus is also crucial for patient's quality of life. Its aim is to restore visual field as wide as it is possible. Last step in surgical interventions is eyelid correction to prevent keratopathy and improve esthetic aspects.

Key words: thyroid orbitopathy, eye surgery, strabismus, Graves' Disease

INTRODUCTION

Graves' disease is an autoimmune and inflammatory disease, that affects thyroid, but also many different organs. Thyroid orbitopathy (TO) (Graves' orbitopathy or thyroid eye disease) is the complication of Graves' disease that affects eyes [1]. The disease presents in two different phases – inflammatory (active) and fibrotic (inactive). For active phase inflammation and infiltration of tissues by immune cells are characteristic. Signs and symptoms of clinically active thyroid orbitopathy are swelling, erythema and pain. During the inactive phase fibrosis and orbital remodeling occurs, but there is no inflammation. That lack of inflammation, allows to perform rehabilitative surgery, however if it is sight-threatening and do not responds to pharmacological treatment, urgent surgical decompression should be performed immediately [2, 3]. It is crucial to state the correct diagnosis of the thyroid orbitopathy to delay progression of the changes in the orbit area.

The most commonly used European classification is the EUGOGO (European Group on Graves' Orbitopathy) criteria, that supports physician in decision-making process. Another popular classification that can be used is VISA (Vision, Inflammation, Strabismus, Appearance). Both of these grading systems are valuable tools in the management of patients that suffer from thyroid orbitopathy [4].

The right choice of the treatment is also connected with severity and activity assessment. Activity describes inflammatory process and can be evaluated using Clinical Activity Score (CAS). If it is lower than 3 points it is inactive. Whilst, severity refers to the risk of vision loss and decrease in the patient's quality of life [5]. According to the studies, TO impairs life quality of the patient, also in mild manifestations cases [6, 7]. Severity can be evaluated with NOSPECS, that includes six class grading [8].

The most commonly occurring symptoms are: pain, edema, blurred vision, photophobia, increased tearing, swelling of the eyelids, double vision and in the end loss of the vision. When it comes to the signs, patients often present upper lids retraction, eyelid edema, erythema, strabismus, conjunctival injection, corneal ulceration and proptosis [9–12]. Thyroid orbitopathy affects patients with euthyroidism, hypothyroidism and less frequently with the Hashimoto's disease [13].

If thyroid orbitopathy is being suspected, other similarly presenting diseases are also possible and should be considered. Differential diagnosis of TO includes: idiopathic orbital inflammation (orbital pseudotumor, myositis), sarcoidosis (proptosis, myopathy), Sjögren syndrome (dry eye, conjunctivitis), vasculitis (pain, proptosis), orbital infectious diseases (pain, edema, proptosis, motility reduction) and orbital neoplasm (proptosis, diplopia, ptosis) [14–16]. That diagnostic uncertainty implicates necessity of enhanced diagnostics.

Diagnosis of thyroid orbitopathy requires laboratory testing (TSH, T4, TRAb) and additional imaging with CT or MRI (to exclude other diseases like orbital tumors). Typically, patients with suspected hyperthyroidism in course of TO should have investigated levels of free T4 and TSH in serum to confirm the diagnosis. However, correct outcomes do not exclude TO. If the tests results are within normal limits and no other explanation of the disease is possible – TSH-receptor antibodies (TRAb) and thyroid peroxidase antibody (TPO) levels should be assessed [10, 17, 18]. Radioactive Iodine Uptake test or Thyroid Ultrasonography can be considered as additional diagnostic tests [19].

It was also reported in the literature that non-inflammatory, but still active thyroid orbitopathy may occur, even besides low CAS score. In Dave et al. study choroidal thickness, that was proofed to change in certain diseases, was examined. Based on that, the authors have reported that choroidal thickness is notably higher in groups of patients with active TO as well as in non-inflammatory active TO compared to the control group and the inactive-disease group. That makes choroidal examination an useful tool to control the TO's course [20]. The same authors also examined Choroidal Vascularity Index (CVI) in terms of diagnostics of non-inflammatory active thyroid orbitopathy and found out that it was also increased, compared to control group with normal and inactive TO [21].

When it comes to different factors that might increase risk of thyroid orbitopathy development, the most important are: already suffering from thyroid dysfunction, elevated levels of thyrotropin receptor antibodies, selenium deficiency, hypercholesterolemia, gene polymorphism and radioactive iodine therapy. Older age and male sex are also described as risk factors [22–24]. The most important factor that increases chances of the development of TO is smoking, it is also correlated with severity of TO. Also early diagnosis of TO is the modifiable risk factor [22, 25]. TO might be described with usage of Rundle's curve. It states that disorders tend to worsen rapidly during the dynamic stage, reach the maximum severity point and then decrease to reach the static plateau stage, but without resolving completely within patients suffering from orbital and eyelid changes [26]. Going further, connecting curve with TO could apply to initial active phase of the disease (dynamic stage) and the following inactive phase with lower symptoms than during the active one (plateau stage). Depending on the curve and stage, different treatment options might be proposed to the patient (in general anti-inflammatory or immunosuppressive treatment during the active phase and surgical interventions during the inactive phase), also prevention of severe complications might be implemented [27].

TREATMENT

In TO, the most important pathophysiological processes that affects orbit and eye are: adipogenesis, glycosaminoglycans accumulation and inflammation. These mechanisms lead to the increase of tissues' volume within the orbit, which increases the pressure inside bone cavity. That pressure can cause neuropathy of the optic nerve and sight loss. Also, fibrotic muscles, especially rectus inferior during up gaze, increases the pressure and leads do glaucoma [28–32].

Many different treatments are available for thyroid orbitopathy (fig. 1). Usually, it is started with the medication treatment, but about 20% cases must be treated surgically [33]. In advanced stage of the disease the best treatment option is to perform surgical intervention [28, 34]. Generally, two options are available – orbital decompression (removal of one or more bone walls) and fat removal. These two technics can be combined to enhance the final effect [29]. In some cases of persistent diplopia, strabismus surgery is indicated. During that intervention surgeon recesses fibrotic oculomotor muscles. Finally, because of incorrect corneal protection provided by the eyelids or esthetic reasons eyelid surgery may be performed [1, 8]. Sometimes, different procedures might be combined in order to achieve better outcomes, for instance combining orbital decompression with strabismus surgery presented with over 80% of successful operations [33].

Another possible options for therapy are experimental, immunomodulatory treatments like anti-thymocyte globulin (ATG). In Świerkot et al. study ATG was administered to the patient with bilateral TO and optic neuropathy. After 12 weeks improvement in patient clinical were noted and color vision were recovered [35].

Non-surgical treatment

Generally, first line treatment are glucocorticoids. They are acting by inhibiting proinflammatory factors like IL-1, IL-6 and IFN- γ [10, 29, 36]. They can be applied as prophylaxis in patients undergoing radioactive iodine treatment. Intravenous therapy is conducted in cycles and every cycle includes usually one administration per week for 6 weeks. Maximum cumulative dosage for each cycle of therapy should not be greater than 8.0 g [3].

In non-advanced stages, administration of the selenium was proved to improve quality of life and reduce progression of the disease. It should be administered for at least 6 months [37].

Local, periocular injections of triamcinolone might be performed if there are any contraindications to treat patients with systemic glucocorticoids (glaucoma, uncontrolled diabetes) [38, 39]. Also, mycophenolate mofetil can be considered, because of positive efficacy and possibility to combine with intravenous glucocorticoids [40].

Radiotherapy is considered as an effective second-line therapeutic option, especially in active phase of TO. It can be combined with glucocorticoids and presents great effects, particularly in diplopia or reduced ocular muscles motility. The most common side effects are retinopathy and optic neuropathy [5, 41].

Cyclosporine and azathioprine can be applied as the second-line treatment to reduce clinical activity of the disease, but only if combined with glucocorticoids in the course of therapy [42, 43].

Another treatment path that can be implemented as a therapy is biological treatment including teprotumumab, rituximab, tocilizumab. Teprotumumab reduces diplopia significantly, improves quality of life and decreases proptosis [44]. Rituximab reduces clinical activity and improves proptosis [45]. Tocilizumab improves patients' state by decreasing clinical activity score and can only be applied in corticosteroid-resistant thyroid orbitopathy [46].

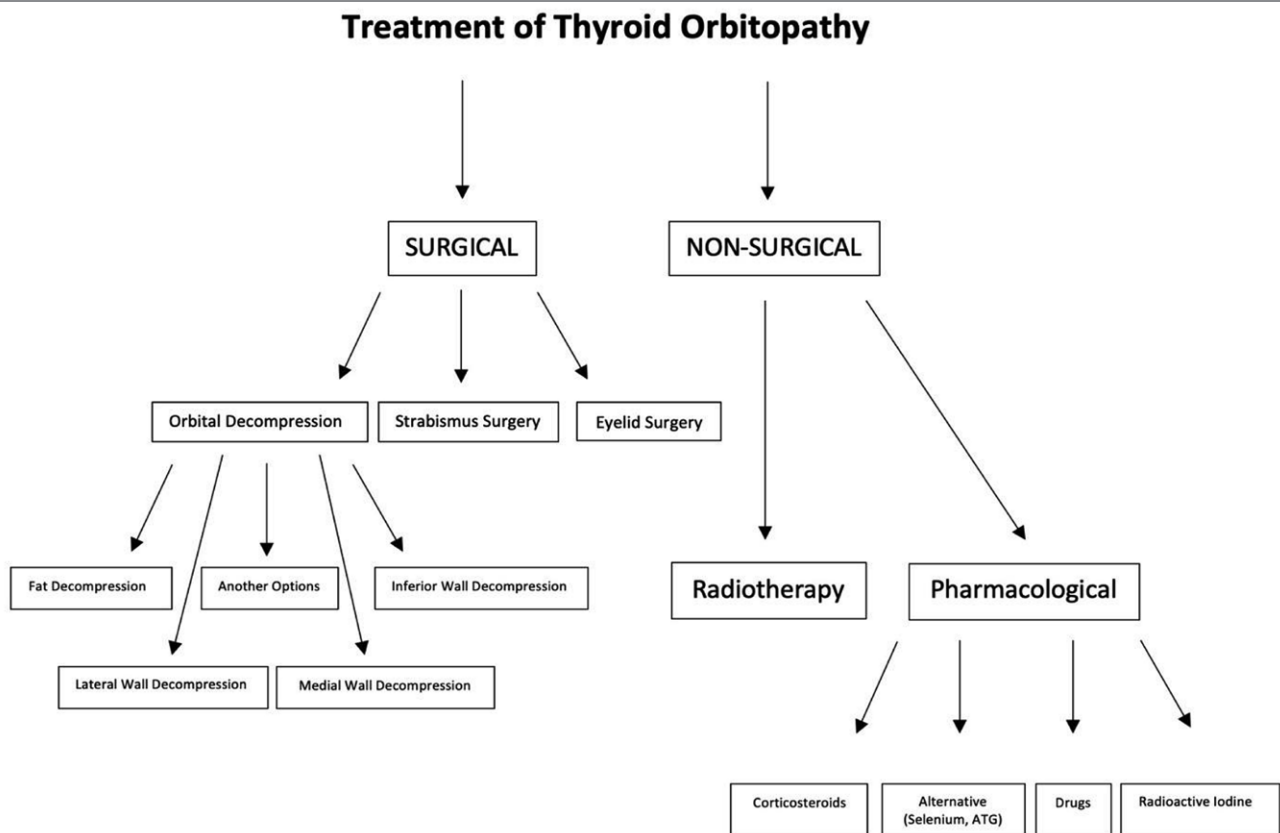
Orbital decompression

Orbital surgery is recommended in acute and advanced thyroid orbitopathy. Indications include: inappropriate response to pharmacological treatment and immunomodulatory treatment, optic neuropathy and keratitis. The general purpose is to reduce elevated pressure and improve patients' vision. Great amount of different approaches is available, the most commonly used are orbital wall decompression (the medial wall, the inferior wall, the inferomedial complex, the lateral wall, the roof and different combinations of them) and orbital lipectomy. It is worth mentioning that Goldberg in his paper from 1998 presented novel approach, that laid foundation to later surgeries with removing bone of the deep lateral wall with accompanying fat removal, what maximized proptosis reduction significantly through only small lateral incision approach [47]. The surgeon can choose between endoscopic or direct approach. The outcome of the three wall decompression is up to 7.5 mm in proptosis reduction, however during four wall decompression (posterolateral wall complex) reduction reaches up to 10 mm [1, 8, 29, 34, 48]. In optic neuropathy caused by TO, improvement in visual functions was reported in between 75% to 90% of cases [49].

There is also possibility of minimally invasive orbital decompressions done locally. It was performed on the group of patients with moderate or mild manifesting proptosis, through cortical bone removal of the zygomatic marrow space of the inferior orbital fissure and intraconal fat dissection following short transconjunctival incision. In 48 patients (80 eyes) reduction of the exophthalmos by a mean 2.4 mm (\pm 2.6 mm) was achieved [50].

FIGURE 1

Possible treatment opportunities for thyroid orbitopathy.



Fat decompression

The surgical decompression of orbital fat was performed by Olivari in 1984. The purpose of the procedure is to remove orbital fat (extraconal or intraconal) to enlarge free space for muscles and soft tissue, what helps to reduce pressure and proptosis. It is estimated that fat decompression results in 2 mm proptosis reduction and causes the same effect as one-wall decompression. The access to the orbital fat is achieved through the conjunctiva or through the skin of the upper lid directly. The volume of human's orbit fat is usually around 8 mL. However, not all of that amount can be removed and it is not distributed equally. Fat decompression is generally safer for the patient than bony decompression, but regression chances are higher. The most common complications are bleeding, infection and nerve damages [34, 51–54]. Improvement of diplopia was observed after decompression in over 80% of the patients [51]. Orbital fat decompression can be considered as a reasonable alternative to treat mild to moderate thyroid orbitopathy.

Lateral wall decompression

It should be performed at first, usually together with fat decompression, because of significantly lower chance of

complications like diplopia or cerebrospinal fluid leaks, than other approaches and lower risk of functional complications. The deep lateral wall decompression is the technique that gives better outcomes than the common lateral wall access. It can be performed through coronal incision, lateral canthal or eyelid incision. Some authors suggest that removal of lateral rim during decompression leads to higher reduction of the proptosis [34, 52, 53, 55]. Lateral wall access is also less complicated, because the lateral rectus muscle is rarely involved with the thyroid orbitopathy [56]. In Kitaguchi et al. study exophthalmos reduction was around 4.1 mm, what corresponded with other studies (2.9 mm to 4.5 mm) [57].

Possible complications include diplopia, anisocoria, post-operative numbness and mimetic disorders due to injuries of nerves and ganglions in the close area [58]. Moreover, a complication of temporal muscle collapsing into the resected wall was described. One of the treatment options is the use of Temporal Cage, but it reduces the volume gain. In Spalthoff et al. study it was suggested that moving lateral wall to the side and trimming the lateral rim, can solve that problem without Temporal Cage usage [59, 60]. Lateral orbital rim can be preserved or removed. Preserving it reduces the risk of tissue injury and cerebrospinal liquid

leak, but removing it reduces the operation time and leads to enhanced proptosis reduction [61].

Medial wall decompression

Medial wall is available to operate through the skin incision, orbital access or endonasal with endoscope. It is often combined with inferior wall decompression and called “inferomedial wall decompression”. Anterior ethmoidal neurovascular bundles are located on the medial wall, it is suggested to cauterize or clip it. Another approach is to leave the bundles untouched if it is possible. Average proptosis reduction that can be achieved is around 2–3 mm. The most possible complication is diplopia, infraorbital nerve damage and other undesirable events are hemorrhages, sinusitis and cerebrospinal fluid leak [31, 34, 52, 58, 62]. If it is necessary, the optic nerve decompression can be done during this approach [63].

It was found that medial wall bows from intraorbital tissues enlargement. In Clarós et al. study it was found that greater pneumatization of the ethmoid facilitates, after surgical intervention on medial wall, gives better outcomes of proptosis reduction [64].

Inferior wall decompression

It is usually performed together with medial wall decompression, when lateral wall decompression is not sufficient. Inferior wall can be operated transorbitally, through conjunctival incision or skin incision and trans-antral with endoscope approach from the oral cavity. Average proptosis reduction is 3.5–4 mm. The main possible complications are diplopia and infraorbital nerve damage, which can resolve in hypoesthesia of the lower lid and the cheek [34, 52, 53, 63, 65]. However, patients with intervention only on inferior wall had significantly less complications, than patients who underwent two-wall decompression [66]. According to the studies complication like diplopia occurred in about 15% of cases of inferior-medial wall decompression [67].

Another options

Other less popular techniques might be used to treat thyroid orbitopathy. Balanced decompression (includes medial and lateral wall decompression, while orbital floor remains intact) is performed in moderate cases of TO [53, 62]. Three-wall decompression (medial, lateral and inferior wall) is especially beneficial in restoring visual field of the patient in advanced stages [68]. Also, three-wall decompression provides better reduction of the proptosis than the two-wall version, while the new-onset diplopia is occurring more often [69].

Strabismus surgery

The strabismus is not only an esthetic problem, but it can also cause diplopia, what affects patients' everyday activ-

ities and work life. The first line treatment of strabismus should be correction that is achieved by prisms. If these methods did not improve patients sight strabismus surgery is necessary. It should be performed after the orbital decompression or at least at the same time and in the inactive phase. It is because orbital decompression can change the deviation of the strabismus. The patient must be euthyroid and strabismus must be stable for 3–6 months (depending on the author). The purpose of the intervention is to restore as much as possible of visual field, especially in the primary position and downgaze [8, 70–72].

Two types of strabismus are described – vertical and horizontal. In vertical type the most commonly involved muscle is inferior rectus. However, in horizontal type medial rectus muscle is mainly affected. Usually, the main aim of the intervention is to weaken restricted oculomotor muscles, achieved with recession [72, 73]. Another approach focus on enhancing the antagonist muscle, what can be achieved with the resection procedure [30]. After radical inferior rectus muscle recession, complication in the form of lower lip retraction may appear [49].

Eyelid surgery

The last step of thyroid orbitopathy surgery, after at least 6 months of euthyroidism is eyelid correction. Eyelid surgery can be linked with strabismus surgery, however it should be always done after orbital and strabismus treatment, because it's outcomes may alter eyelid plastics effects [72].

Important factor that have a crucial role when it comes to making decision of the urgency of the intervention is advancement of ocular surface damage. Lid retraction, which is one of the most characteristic signs and the most common sign of TO is caused by fibrosis, what is an outcome of inflammation and fibroblasts deposition. That can lead to increased tear evaporation and keratopathy. Main procedures include lowering the upper lid, raising the lower lid, reduction of palpebral aperture with graft lengthening. Lid retraction can be divided into upper lid and lower lid retraction. To treat the upper lid Müllerectomy (with levator disinsertion if needed), scleral interposition, hangback sutures or blepharotomy [74]. However, to treat lower lid the surgeon can perform recession or extirpation of the inferior retractors and capsulopalpebral fascia [75]. Elevation of the lower lid can be done with auto- or allografting techniques [49]. That includes utilization of dermis fat, mucosa, free tarsal graft, sclera from the donor and artificial materials [76]. Positive outcome of the intervention might be achieved in around 75% of the patients [74].

In general, two surgical approaches are possible – anterior (through the eyelid) and posterior (through conjunctiva and Müller's muscle). Eyelid surgery have an important role in esthetic rehabilitation. In the end blepharoplasty can be performed to remove excess skin and fat in the area of eye-

lids [8, 29, 53, 74, 77]. Also, that kind of rehabilitative surgery allows patient to regain satisfaction from its own appearance [78] correction of eyelid retraction, and aesthetic blepharoplasty, performed traditionally in separate stages.

PANDEMIC CIRCUMSTANCES

During COVID-19 pandemic it could be more beneficial for patients to postpone the surgical interventions in order not to risk the infection, but only if there is no risk of sight loss [79]. Mild manifestations of TO should be treated by resigning from smoking and pharmacologically with glucocorticoids and other immunomodulating drugs. Home therapy should be considered, but remaining under the strict monitoring of the patients' state [3, 80].

CORRESPONDENCE

Mateusz Zabochnicki, MS

Students' Scientific Society, Department of Ophthalmology,
Faculty of Medical Sciences in Katowice,
Medical University of Silesia
40-514 Katowice, ul. Ceglana 35
phone: +48 32 358 12 27
e-mail: zabochnicki@gmail.com

CONCLUSIONS

Thyroid orbitopathy is complex and difficult to treat disease. Often pharmacological methods (selenium, glucocorticoids, cyclosporine and antibodies) and radiotherapy are not sufficient to achieve the satisfactory effect of the therapy. In these patients, surgical intervention is demanded to provide effective treatment. Surgeon that decided to perform an intervention has a whole range of technics and approaches to choose from. Depending on acquired skills, experience and expected outcome of the surgery it can be decided to decompress different number of walls, but also recess or enhance oculomotor muscles or remove orbital fat. Well performed intervention is not only effective way of treating thyroid orbitopathy, but also introduces a great improvement in patients' quality of life.

ORCID

Mateusz Zabochnicki – ID – <http://orcid.org/0000-0002-6975-5693>
Wojciech Szaraniec – ID – <http://orcid.org/0000-0002-6433-198X>
Dorota Pojda-Wilczek – ID – <https://orcid.org/0000-0002-7579-2546>

References

1. Subekti I, Soewondo P, Soebardi S et al. Practical Guidelines Management of Graves Ophthalmopathy. *Acta Med Indones.* 2019; 51: 8.
2. Patel A, Yang H, Douglas RS. A New Era in the Treatment of Thyroid Eye Disease. *American Journal of Ophthalmology* 2019; 208: 281-8.
3. Bartalena L, Kahaly GJ, Baldeschi L et al. The 2021 European Group on Graves' orbitopathy (EUGOGO) clinical practice guidelines for the medical management of Graves' orbitopathy. *Eur J Endocrinol.* 2021; 185: G43-67.
4. Barrio-Barrio J, Sabater AL, Bonet-Farriol E et al. Graves' Ophthalmopathy: VISA versus EUGOGO Classification, Assessment, and Management. *J Ophthalmol.* 2015; 2015: 1-16.
5. Genere N, Stan MN. Current and Emerging Treatment Strategies for Graves' Orbitopathy. *Drugs.* 2019; 79: 109-24.
6. Wiersinga WM. Quality of life in Graves' ophthalmopathy. *Best Pract Res Clin Endocrinol Metab.* 2012; 26: 359-70.
7. Kahaly GJ, Petrak F, Hardt J et al. Psychosocial morbidity of Graves' orbitopathy. *Clin Endocrinol.* 2005; 63: 395-402.
8. Hall AJ, Topliss DJ. Medical and Surgical Treatment of Thyroid Eye Disease. *Intern Med J.* 2022; 52(1): 14-20.
9. Wiersinga WM. Advances in treatment of active, moderate-to-severe Graves' ophthalmopathy. *Lancet Diabetes Endocrinol.* 2017; 5: 134-42.
10. Weiler DL. Thyroid eye disease: a review. *Clin Exp Optom.* 2017; 100: 20-5.
11. Taylor PN, Zhang L, Lee RWJ et al. New insights into the pathogenesis and nonsurgical management of Graves orbitopathy. *Nat Rev Endocrinol.* 2020; 16: 104-16.
12. Antonelli A, Fallahi P, Elia G et al. Graves' disease: Clinical manifestations, immune pathogenesis (cytokines and chemokines) and therapy. *Best Pract Res Clin Endocrinol Metab.* 2020; 34: 101388.
13. Boddu N, Jumani M, Wadhwa V et al. Not All Orbitopathy Is Graves': Discussion of Cases and Review of Literature. *Front Endocrinol.* 2017; 8: 184.

14. Vehof J, Utheim TP, Bootsma H et al. Advances, limitations and future perspectives in the diagnosis and management of dry eye in Sjögren's syndrome. *Clin Exp Rheumatol.* 2020; 38: 301-9.
15. Marinò M, Ionni I, Lanzolla G et al. Orbital diseases mimicking graves' orbitopathy: a long-standing challenge in differential diagnosis. *J Endocrinol Invest.* 2020; 43: 401-11.
16. Mombaerts I, Ramberg I, Coupland SE et al. Diagnosis of orbital mass lesions: clinical, radiological, and pathological recommendations. *Surv Ophthalmol.* 2019; 64: 741-56.
17. Subekti I, Pramono LA. Current Diagnosis and Management of Graves' Disease. *Acta Med Indones.* 2018; 50: 6.
18. Phelps PO, Williams K. Thyroid eye disease for the primary care physician. *Dis Mon.* 2014; 60: 292-8.
19. Hoang TD, Stocker DJ, Chou EL et al. 2022 Update on Clinical Management of Graves Disease and Thyroid Eye Disease. *Endocrinol Metab Clin North Am.* 2022; 51: 287-304.
20. Dave TV, Natarajan R, Reddy RU et al. Choroidal Thickness in Thyroid Eye Disease: Comparison With Controls and Application in Diagnosing Non-Inflammatory Active Disease. *Cureus* 2021; 13(11): e19779.
21. Dave TV, Jonnadula GB, Lanka P et al. Choroidal vascularity index in thyroid eye disease: comparison with controls and application in diagnosing non-inflammatory active disease. *Orbit.* 2022; 41: 89-96.
22. Bartalena L, Piantanida E, Gallo D et al. Epidemiology, Natural History, Risk Factors, and Prevention of Graves' Orbitopathy. *Front Endocrinol.* 2020; 11: 615993.
23. Cao J, Su Y, Chen Z et al. The risk factors for Graves' ophthalmopathy. *Graefes Arch Clin Exp Ophthalmol.* 2022; 260: 1043-54.
24. Tabriz N, Gruben A, Uslar V et al. Risk factors for Graves' Orbitopathy in surgical patients – Results of a 10-year retrospective study with review of the literature. *Endocrinol Diab Metab.* 2021; 4(1): e00210.
25. Khong JJ, Finch S, De Silva C et al. Risk Factors for Graves' Orbitopathy; the Australian Thyroid-Associated Orbitopathy Research (ATOR) Study. *J Clin Endocrinol Metab.* 2016; 101: 2711-20.
26. Bartley GB. Rundle and His Curve. *Arch Ophthalmol.* 2011; 129: 356-8.
27. Menconi F, Profilo MA, Leo M et al. Spontaneous Improvement of Untreated Mild Graves' Ophthalmopathy: Rundle's Curve Revisited. *Thyroid.* 2014; 24: 60-6.
28. Bahn RS. Graves' Ophthalmopathy. *N Engl J Med.* 2010; 362: 726-38.
29. Drui D, Du Pasquier Fediaevski L, Vignal Clermont C et al. Graves' orbitopathy: Diagnosis and treatment. *Ann Endocrinol (Paris).* 2018; 79: 656-64. <http://doi.org/10.1016/j.ando.2018.08.005>.
30. Imburgia A, Elia G, Franco F et al. Treatment of exophthalmos and strabismus surgery in thyroid-associated orbitopathy. *Int J Oral Maxillofac Surg.* 2016; 45: 743-9.
31. Seibel I, Hofmann VM, Sönmez H et al. Medial and mediolateral orbital decompression in intractable Graves' Orbitopathy. *Auris Nasus Larynx.* 2017; 44: 428-34.
32. Li X, Bai X, Liu Z et al. The Effect of Inferior Rectus Muscle Thickening on Intraocular Pressure in Thyroid-Associated Ophthalmopathy. *J Ophthalmol.* 2021; 2021: 1-5.
33. Hsieh M-W, Hsu C-K, Kuo P-C et al. Factors Predicting the Success of Combined Orbital Decompression and Strabismus Surgery in Thyroid-Associated Orbitopathy. *JPM.* 2022; 12: 186.
34. Rootman DB. Orbital decompression for thyroid eye disease. *Surv Ophthalmol.* 2018; 63: 86-104.
35. Świerkot M, Kulawik G, Sarnat-Kucharczyk M et al. Long-term remission of steroid-resistant Graves' orbitopathy after administration of anti-thymocyte globulin. *Endokrynol Pol.* 2020; 71: 2.
36. Vandewalle J, Luybaert A, De Bosscher K et al. Therapeutic Mechanisms of Glucocorticoids. *Trends Endocrinol Metab.* 2018; 29: 42-54.
37. Marcocci C, Kahaly GJ, Krassas GE et al. Selenium and the Course of Mild Graves' Orbitopathy. *N Engl J Med.* 2011; 364: 1920-31.
38. Hamed-Azzam S, Mukari A, Feldman I et al. Fornix triamcinolone injection for thyroid orbitopathy. *Graefes Arch Clin Exp Ophthalmol.* 2015; 253: 811-6.
39. Lee SJ, Rim THT, Jang SY et al. Treatment of upper eyelid retraction related to thyroid-associated ophthalmopathy using subconjunctival triamcinolone injections. *Graefes Arch Clin Exp Ophthalmol.* 2013; 251: 261-70.
40. Khong JJ, McNab A. Medical treatment in thyroid eye disease in 2020. *Br J Ophthalmol.* 2021; 105: 299-305.
41. Ruchała M, Hernik A, Zybek A. Orbital radiotherapy in the management of Graves' orbitopathy – current state of knowledge. *Endokrynol Pol.* 2014; 65: 388-96.
42. Nowak M, Nowak W. Treatment of moderate to severe and active thyroid orbitopathy during SARS-CoV-2 pandemic. *Ophthalmol J.* 2022; 7: 94-102.
43. Zhou X, Zhou D, Wang J et al. Treatment strategies for Graves' ophthalmopathy: a network meta-analysis. *Br J Ophthalmol.* 2020; 104: 551-6.
44. Smith TJ, Kahaly GJ, Ezra DG et al. Teprotumumab for Thyroid-Associated Ophthalmopathy. *N Engl J Med.* 2017; 376: 1748-61.

45. Ostrowski RA, Bussey MR, Shayesteh Y et al. Rituximab in the Treatment of Thyroid Eye Disease: A Review. *Neuroophthalmology*. 2015; 39: 109-15.
46. Perez-Moreiras JV, Gomez-Reino JJ, Maneiro JR et al. Efficacy of Tocilizumab in Patients With Moderate-to-Severe Corticosteroid-Resistant Graves Orbitopathy: A Randomized Clinical Trial. *Am J Ophthalmol*. 2018; 195: 181-90.
47. Goldberg RA. The Evolving Paradigm of Orbital Decompression Surgery. *Arch Ophthalmol*. 1998; 116: 95-6.
48. Kotwal A, Stan M. Current and Future Treatments for Graves' Disease and Graves' Ophthalmopathy. *Horm Metab Res*. 2018; 50: 871-86.
49. Burch HB, Perros P, Bednarczuk T et al. Management of thyroid eye disease: a Consensus Statement by the American Thyroid Association and the European Thyroid Association. *Eur Thyroid J*. 2022; 11: e220189.
50. Ben Simon GJ, Schwarcz RM, Mansury AM et al. Minimally Invasive Orbital Decompression: Local Anesthesia and Hand-Carved Bone. *Arch Ophthalmol*. 2005; 123: 1671.
51. Willaert R, Maly T, Ninclaus V et al. Efficacy and complications of orbital fat decompression in Graves' orbitopathy: a systematic review and meta-analysis. *Int J Oral Maxillofac Surg*. 2020; 49: 496-504.
52. Naik M, Nair A, Gupta A et al. Minimally invasive surgery for thyroid eye disease. *Indian J Ophthalmol*. 2015; 63: 847.
53. Eckstein A, Schittkowski M, Esser J. Surgical treatment of Graves' ophthalmopathy. *Best Pract Res Clin Endocrinol Metab*. 2012; 26: 339-58.
54. Al-Sharif E, Alsuhaibani AH. Fat-removal orbital decompression for thyroid associated orbitopathy: The right procedure for the right patient. *Saudi J Ophthalmol*. 2017; 31: 156-61.
55. Jefferis JM, Jones RK, Currie ZI et al. Orbital decompression for thyroid eye disease: methods, outcomes, and complications. *Eye*. 2018; 32: 626-36.
56. Sellari-Franceschini S, Lenzi R, Santoro A et al. Lateral wall orbital decompression in Graves' orbitopathy. *Int J Oral Maxillofac Surg*. 2010; 39: 16-20.
57. Kitaguchi Y, Takahashi Y, Kakizaki H. Computed Tomography-Based Prediction of Exophthalmos Reduction After Deep Lateral Orbital Wall Decompression for Graves' Orbitopathy. *Graefes Arch Clin Exp Ophthalmol*. 2019; 257: 2759-67.
58. Parrilla C, Mele DA, Gelli S et al. Multidisciplinary approach to orbital decompression. A review. *Acta Otorhinolaryngol Ital*. 2021; 41: S90-101.
59. Spalthoff S, Jehn P, Zimmerer R et al. Modified lateral orbital wall decompression in Graves' orbitopathy using computer-assisted planning. *Int J Oral Maxillofac Surg*. 2018; 47: 167-74.
60. Tavassol F, Kokemüller H, Müller-Tavassol C et al. A Quantitative Approach to Orbital Decompression in Graves' Disease Using Computer-Assisted Surgery: A Compilation of Different Techniques and Introduction of the "Temporal Cage." *J Oral Maxillofac Surg*. 2012; 70: 1152-60.
61. Sagiv O, Satchi K, Kinori M et al. Comparison of lateral orbital decompression with and without rim repositioning in thyroid eye disease. *Graefes Arch Clin Exp Ophthalmol*. 2016; 254: 791-6.
62. Hernández-García E, San-Román JJ, González R et al. Balanced (endoscopic medial and transcutaneous lateral) orbital decompression in Graves' orbitopathy. *Acta Otolaryngol*. 2017; 137: 1183-7.
63. Ong AA, DeVictor S, Vincent AG et al. Bony Orbital Surgery for Graves' Ophthalmopathy. *Facial Plast Surg*. 2021; 37: 692-7.
64. Clarós P, Wałaj A, López-Fortuny M et al. Impact of the ethmoid volume on endoscopic medial wall decompression outcomes in Graves' orbitopathy. *Acta Otolaryngol*. 2020; 140: 948-53.
65. Thakar A, Tandon N, Lal P. Endoscopic orbital decompression for Graves' orbitopathy. *Indian J Endocr Metab*. 2013; 17: 265.
66. Fabian ID, Rosen N, Ben Simon GJ. Strabismus After Inferior-Medial Wall Orbital Decompression in Thyroid-Related Orbitopathy. *Curr Eye Res*. 2013; 38: 204-9.
67. Cubuk MO, Konuk O, Unal M. Orbital decompression surgery for the treatment of Graves' ophthalmopathy: comparison of different techniques and long-term results. *Int J Ophthalmol*. 2018; 11: 1363-70.
68. Korkmaz S, Konuk O. Surgical Treatment of Dysthyroid Optic Neuropathy: Long-Term Visual Outcomes with Comparison of 2-Wall versus 3-Wall Orbital Decompression. *Curr Eye Res*. 2016; 41: 159-64.
69. Cheng S-N, Yu Y-Q, You Y-Y et al. Comparison of 2-wall versus 3-wall orbital decompression against dysthyroid optic neuropathy in visual function: A retrospective study in a Chinese population. *Medicine*. 2021; 100: e24513.
70. Jellema HM, Saeed P, Mombaerts I et al. Objective and subjective outcomes of strabismus surgery in Graves' orbitopathy: a prospective multicentre study. *Acta Ophthalmol*. 2017; 95: 386-91.
71. Quaranta-Leoni FM, Di Marino M, Leonardi A et al. Single-stage Orbital Decompression, Strabismus and Eyelid Surgery in Moderate to Severe Thyroid Associated Orbitopathy. *Orbit*. 2021: 1-9.
72. Akbari MR, Mirmohammadsadeghi A, Mahmoudzadeh R et al. Management of thyroid eye disease-related strabismus. *J Curr Ophthalmol*. 2020; 32(1): 1-13.

73. Thomas SM, Cruz OA. Comparison of two different surgical techniques for the treatment of strabismus in dysthyroid ophthalmopathy. *J AAPOS*. 2007; 11: 258-61.
74. Pinas D, De Keizer ROB, Wubbels RJ et al. Results of surgical correction of upper eyelid retraction in Graves' Orbitopathy. *Acta Ophthalmol*. 2021; 99(4): e608-e613.
75. Ribeiro SFT, Shekhovtsova M, Duarte AF et al. Graves Lower Eyelid Retraction. *Ophthalmic Plast Reconstr Surg*. 2016; 32: 161-9. <http://doi.org/10.1097/IOP.0000000000000613>.
76. Norris JH, Ross JJ, O'Reilly P et al. A review of combined orbital decompression and lower eyelid recession surgery for lower eyelid retraction in thyroid orbitopathy. *Br J Ophthalmol*. 2011; 95: 1664-9.
77. Cruz AAV, Ribeiro SFT, Garcia DM et al. Graves Upper Eyelid Retraction. *Surv Ophthalmol*. 2013; 58: 63-76.
78. Bernardini FP, Skippen B, Zambelli A et al. Simultaneous Aesthetic Eyelid Surgery and Orbital Decompression for Rehabilitation of Thyroid Eye Disease: The One-Stage Approach. *Aesthet Surg J*. 2018; 38: 1052-61.
79. Bartalena L, Chiovato L, Marcocci C et al. Management of Graves' hyperthyroidism and orbitopathy in time of COVID-19 pandemic. *J Endocrinol Invest*. 2020; 43: 1149-51.
80. Boelaert K, Visser WE, Taylor PN et al. Endocrinology in the time of COVID-19: Management of hyperthyroidism and hypothyroidism. *Eur J Endocrinol*. 2020; 183: G33-9.

Authors' contributions:

All authors have equal contribution to the paper.

Conflict of interest:

None.

Financial support:

None.

Ethics:

The content presented in the article complies with the principles of the Helsinki Declaration, EU directives and harmonized requirements for biomedical journals.