

Postponed surgical management of suprachoroidal hemorrhage

Aleksandra Górka^{1,2}, Sebastian Sirek^{1,2}, Dawid Woszczek³,
Wojciech Rokicki^{1,2}

¹ Clinic of Ophthalmology, Department of Ophthalmology, Faculty of Medical Sciences,
Medical University of Silesia in Katowice
Head: prof. Dorota Wyględowska-Promieńska, MD, PhD

² Department of Adult Ophthalmology, Prof. K. Gibinski University Clinical Center, Medical University of Silesia in Katowice
Head: prof. Dorota Wyględowska-Promieńska, MD, PhD

³ Student Scientific Circle of the Ophthalmology Clinic of the Department of Ophthalmology, Faculty of Medical Sciences,
Medical University of Silesia in Katowice
Head: prof. Dorota Wyględowska-Promieńska, MD, PhD



HIGHLIGHTS

Suprachoroidal haemorrhage is a very severe condition with a poor prognosis and often requires multi-stage and long treatment.

ABSTRACT

Material and methods: A 68-year-old female patient was referred to clinic with a suprachoroidal hemorrhage of the left eye arising during phacoemulsification with rupture of the lens capsule and displacement of cortical masses into the vitreous chamber. She reported severe complaints of pain in the left eye. Her visual acuity was at a level of light perception with no localization and intraocular pressure (IOP) at 60 mmHg. B-projection ultrasonography showed significant elevation of the choroid with dense echoes of extravasated blood in the suprachoroidal space. After analysis of the local and clinical condition, a vitrectomy procedure was performed from the pars plana approach (PPV). Due to persistently high IOP, the patient was qualified for a PPV again, 23 days after the suprachoroidal hemorrhage has occurred.

Results: The follow-up, 10 days after the second PPV procedure, has shown an improvement of the local condition and normalization of intraocular pressure to a 17 mmHg. The patient reported no complaints of pain.

Key words: vitrectomy, suprachoroidal hemorrhage, phacoemulsification

INTRODUCTION

The first case report of suprachoroidal hemorrhage (SCH) during ophthalmic surgery was published in 1760 by baron de Wetzel, however the first successfully treated case was described in 1915 by Verhoeff. SCH is a condition, when blood accumulates between the choroid and the sclera. The source of the blood which accumulates in the suprachoroidal space is a tear in the long or short posterior ciliary artery. Hypotony appears to be the main factor which causes the rupture of the vessels. It has been linked with an increased outflow of aqueous humor from the anterior chamber into the spatium intervaginale. The other cause of hypotonia may also be an obstruction of venous outflow from the vortex veins [1]. The force and the size of the hemorrhage causes outward displacement of the content of the eyeball or elevation of the retinal surface. This is a very serious complication that occurs rarely during the intraocular surgeries, such as glaucoma surgery (0.15–6.1%), vitreoretinal surgery (0.17–1.9%), penetrating keratoplasty (0.087–1.08%) or phacoemulsification (0.03–0.81%) [2]. The pathogenesis of SCH is based on the pressure difference between the pressure prevailing in the ciliary vessels and their surroundings. Any surgical intervention leads to generation of the above-described pressure difference, which results in the weakening of the walls of the ciliary arteries and as a result their rupture [3]. The factors described in the available literature, that may predispose the eye to SCH include: glaucoma, myopia, atherosclerotic cardiovascular disease, hypertension, advanced age and intraoperative tachycardia [4].

CASE REPORT

A 68-year-old woman was referred to the Prof. K. Gibinski University Clinical Center of the Silesian Medical University in Katowice due to SCH with severe pain in the left eye. The hemorrhage, according to a telephone consultation, has occurred during phacoemulsification complicated by rupture of the lens capsule and displacement of the lens masses into the vitreous chamber 6 days earlier. The information sheet showed that when the hemorrhage has occurred the drainage wasn't performed and only the suture closure of the eyeball was done.

During examination of the patient, an iris embedded in the surgical wound of the cornea was found and the anterior chamber was entirely filled with a thick clotted blood. An ultrasound performed during admission to the ward showed significant elevation of the choroid with dense echoes of extravasated blood in the suprachoroidal space in all quadrants (fig. 1, 2).

An attempt to decompress the eyeball, due to the pain of an eye and intraocular pressure (IOP) reaching 60 mmHg, was made. Visual acuity of the left eye was at the level of light perception without localization. A sclerotomy with

FIGURE 1

Left eye after phacoemulsification surgery with an intraocular hemorrhage present, a thick blood clot in the anterior chamber, and an iris embedded into the wound.

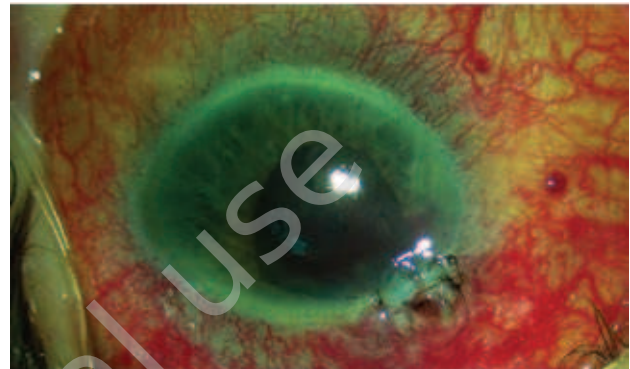
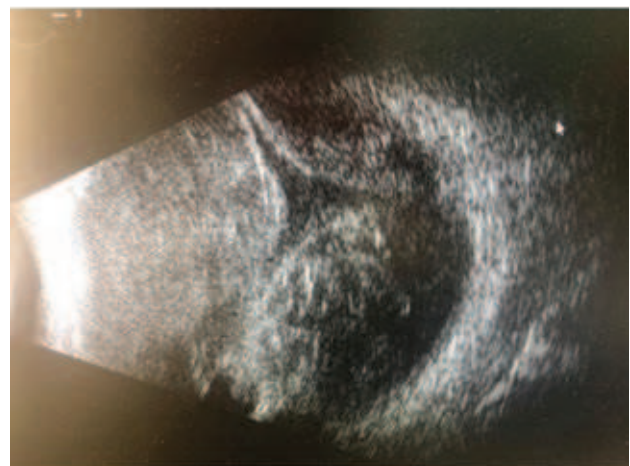
FIGURE 2

Ultrasound of the left eye before the partial vitrectomy procedure – “kissing” choroids.



a 1.5 mm knife head was performed at a point as far away from the corneal limbus as possible. The partial evacuation of the blood was followed by a partial vitrectomy (PPV) due to the prevailing conditions inside the eye. An endotamponade with silicone oil was performed on the eye, in which a full PPV was not performed.

The patient re-visited the clinic 23 days after the SCH, reporting severe pain in the left eye. Visual acuity was still at the level of light perception without localization. After a slight improvement of the local condition and partial reduction of the IOP after local and general treatment, the decision to perform re-surgery was made. Both PPV procedures were performed by the same surgeon (WR).

During the follow-up 10 days after the second PPV procedure, the patient reported a significant improvement in her comfort of life and resolution of pain (fig. 3, 4). Visual

acuity at the level of light perception with localization was achieved. Local treatment of the left eye with brimonidine 2x, dexamethasone 2x was prescribed.

FIGURE 3

Left eye 28 days after an exploratory PPV, 2 drainage sclerotomies (temple-down, nose-down) and endotamponade with silicone oil.

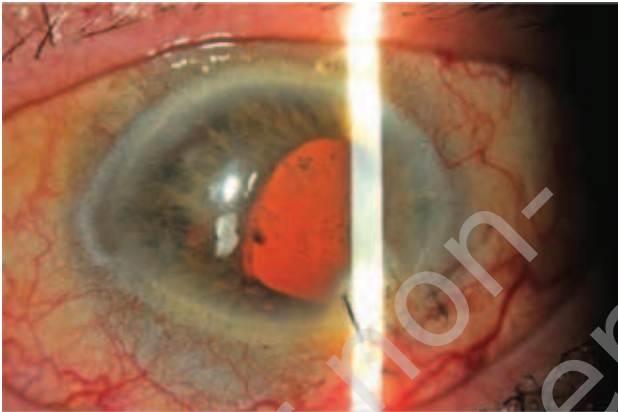


FIGURE 4

Ultrasound of the left eye 10 days after the second PPV procedure.



DISCUSSION

Intraoperative symptoms of SCH may include shallowing of the anterior chamber, loss of red reflex from the fundus, increased IOP, wrinkling and bulging of the posterior capsule, an iris prolapse and a vitreous prolapse.

Postoperative signs and symptoms of SCH may include severe eye pain, headache, nausea with or without vomiting, which usually worsens during Valsalva maneuvers. In addition, the visual acuity may be decreased, shallowing of the anterior chamber, loss of red reflex from the fundus, elevated IOP, prolapse of the vitreous into the anterior

chamber, and elevation of the choroid [1, 5]. Intraoperative management should include immediate closure of the eye by suturing all incisions to prevent further hemorrhage and subsequent pushing of intraocular content. The only attempt that can be made in the first minutes of hemorrhage before the blood has clotted is a decompressive sclerotomy. It is performed as far from the corneal limbus as possible, at least > 8 mm [6], the extravasated blood is released using either a 20G PPV blade or a 1.5 mm knife. This is not always effective, as blood clots very quickly. However, only this maneuver actually gives the opportunity to recreate anatomical conditions [1, 2]. Postoperative non-surgical management should include control of the IOP, reduction of inflammation by prescribing topical corticosteroids and reduction of eye pain by topical cycloplegic drugs. Non-steroidal anti-inflammatory drugs (NSAIDs) are contraindicated because their antiplatelet effects can cause ongoing hemorrhage. It is recommended to monitor the condition of the SCH with ultrasound and check the visual acuity [1, 2, 7, 8]. Consider reoperation if severe ocular pain persists, uncontrolled IOP occurs or the choroid elevation does not resolve [1, 2, 7, 8].

Waiting until the clot has lysed to full liquefaction is very helpful for successful drainage of SCH [1, 2, 7, 8]. The main goal of the surgery is to evacuate the blood from under the detached choroid and apply it to the eyeball wall. The most effective is extraocular procedure (decompression) combined with an intraocular (PPV) [8]. The standard procedure involves incising the sclera (sclerotomy) at the point of highest elevation of the choroidal membrane, as far from the corneal limbus as possible and gradually increasing the IOP with a closed PPV system [7]. In addition, we can help ourselves by application of perfluorocarbon (PFCL), which firmly presses the retina and choroid against the eyeball wall and helps push the extravasated blood out through the sclerotomies. According to our experience and according to the literature, the effectiveness of the procedure is best at 7–14 days after hemorrhage, although some authors report 36 h [9–13]. However, in our opinion, 36 h is far too short, as complete lysis of the clot does not occur. Also, from our own observations, after 7 days the blood is the most liquefied which allows to perform the most effective vascular drainage through sclerotomies [2, 7, 8, 13].

In our case, it was not possible to perform effective drainage of the SCH within the timeframe stated in the literature, only successfully carried out on the 23rd day after the onset of the SCH. It was not possible to successfully perform drainage through sclerotomies on day 7 after SCH, and this case shows that PPV after 23 days was more reasonable and more successful than the first PPV operation in early stage. We performed the procedures on an outstanding delete trial basis.

CONCLUSION

From the experience of our clinic and after studying the literature, we can say that in SCH, the combined procedure of PPV with decompression is quite an effective method but SCH is a very severe condition with a poor prognosis and often requires multi-stage and long treatment [6, 14]. In our case, it was only possible to almost fully decompress the hemorrhage and apply a choroid in a second PPV procedure

30 days after the onset of SCH. The chances for the return of baseline visual acuity are low now and estimated at 29.4% in a series conducted by Scott et al. [10, 15, 16]. However, such a patient should not be abandoned and further procedures should not be waived if there are indications and a chance of at least improving the comfort of a patient's life.

Figures: from the authors' own materials.

CORRESPONDENCE

Aleksandra Górka, MD

Clinic of Ophthalmology, Department of Ophthalmology,
Faculty of Medical Sciences,
Medical University of Silesia in Katowice
40-514 Katowice, ul. Ceglana 35
e-mail: aleksandra.m.gorska@gmail.com

ORCID

Aleksandra Górka – ID – <http://orcid.org/0000-0002-6851-5065>
Sebastian Sirek – ID – <http://orcid.org/0000-0002-3138-3011>
Wojciech Rokicki – ID – <http://orcid.org/0000-0001-9430-1506>

References

1. Chu TG, Green RL. Suprachoroidal Hemorrhage. *Surv Ophthalmol.* 1999; 43(6): 471-86.
2. Mantopoulos D, Hariprasad SM, Fine HF. Suprachoroidal Hemorrhage: Risk Factors and Diagnostic and Treatment Options. *Ophthalmic Surg Lasers Imaging Retina.* 2019; 50(11): 670-4.
3. Obuchowska I, Mariak Z, Stankiewicz A. Masywny krwotok nadnaczyniówkowy jako powikłanie operacji usunięcia zaćmy – opis przypadku. *Klin Oczna.* 2002; 104(5-6): 406-10.
4. Reynolds MG, Haimovici R, Flynn HW Jr et al. Suprachoroidal hemorrhage. Clinical features and results of secondary surgical management. *Ophthalmology.* 1993; 100(4): 460.
5. Foo R, Tsai A, Lim L. Management of suprachoroidal hemorrhage. *EyeNet Magazine.* 2018; May: 35-7.
6. Rezende FA, Kicking MC, Li G et al. Transconjunctival drainage of serous and hemorrhagic choroidal detachment. *Retina.* 2012; 32(2): 242-9.
7. Roa T, De La Rosa S, Netland P. Five pointers on choroidal effusion and suprachoroidal hemorrhage. *Glaucoma Today.* 2019: 37-39.
8. Learned D, Elliott D. Management of delayed suprachoroidal hemorrhage after glaucoma surgery. *Semin Ophthalmol.* 2018; 33(1): 59-63.
9. Welch JC, Spaeth GL, Benson WE. Massive suprachoroidal hemorrhage: Follow-up and outcome of 30 cases. *Ophthalmology.* 1988; 95:1202-6.
10. Lakhanpal V, Schocket SS, Elman MJ et al. A new modified vitreoretinal surgical approach in the management of massive suprachoroidal hemorrhage. *Ophthalmology.* 1989; 96: 793-800.
11. Lambrou FH Jr, Meredith TA, Kaplan HJ. Secondary surgical management of expulsive choroidal hemorrhage. *Arch Ophthalmol.* 1987; 105: 1195-8.
12. Gloor B, Kalman A. Chorioidaleffusion und expulsive blutang bei bulbuseröffnenden eingriffen: lehren von 26 patienten. *Klin Monatsbl Augenheilkd.* 1993; 202: 224-37.
13. Scott IU, Flynn HW Jr, Schiffman J et al. Visual acuity outcomes among patients with appositional suprachoroidal hemorrhage. *Ophthalmology.* 1997; 104: 2039-46.
14. Kurup SK, McClintic JI, Allen JC et al. Viscoelastic assisted drainage of suprachoroidal hemorrhage associated with seton device in glaucoma filtering surgery. *Retina.* 2017; 37(2): 396-9.
15. Wang L, Yang C, Yang C et al. Clinical characteristics and visual outcome of non-traumatic suprachoroidal haemorrhage in Taiwan. *Acta Ophthalmol.* 2008; 86(8): 908-12.
16. Ling R, Cole M, James C et al. Suprachoroidal haemorrhage complicating cataract surgery in the UK: Epidemiology, clinical features, management, and outcomes. *Br J Ophthalmol.* 2004; 88(4): 478-80.

For non-commercial use only

Authors' contributions:

Aleksandra Górka: wrote the manuscript with input from all authors; Sebastian Sirek: wrote the article, literature analysis; Dawid Woszczek: wrote the article; Wojciech Rokicki: performed the surgery, supervised the project.

Conflict of interest:

None.

Financial support:

None.

Ethics:

The content presented in the article complies with the principles of the Helsinki Declaration, EU directives and harmonized requirements for biomedical journals.