

Fungal keratitis – current diagnosis and therapeutic possibilities



**Dominika Prokop¹, Ada Pandey¹, Małgorzata Gawlak¹,
Bartosz Kuźlik¹, Kinga Czarnacka¹, Julia Kaczmarek¹,
Ismael Alsoubie¹, Alicja Chmura-Hołyś¹, Aneta Pyza¹,
Bartłomiej Żaczek¹, Anna Roszkowska^{1,2}, Ilona Pawlicka^{1,2},
Agnieszka Piskorz^{1,2}, Maciej Kozak^{1,2}**

¹ Faculty of Medicine and Health Sciences, Andrzej Frycz Modrzewski Academy in Krakow
Dean: Prof. KAAFM Janusz Ligeza, PhD

² Clinical Ophthalmology Department, Provincial Ophthalmology Hospital in Krakow
Head of the Department of Ophthalmology: Prof. Anna Roszkowska, PhD

HIGHLIGHTS

Fungal keratitis is one of the main causes of eye diseases. It is a clinical challenge because of the slow disease process, features comparable to those of other keratitis, and potential complications.

ABSTRACT

Keratitis and subsequent damage to the cornea resulting from infectious causes is one of the most serious problems facing ophthalmology today. One of the most common etiologies is fungal infection. Symptoms range from pain and visual deterioration, Wessely ring, inflammatory reaction in the anterior chamber or ropost. Diagnosis in addition to the classic medical and ophthalmologic examination consists of microscopic examination of scrapings, Gram examination combined with culture gives a 90% chance of detecting a fungal etiology. Good results are also observed with PCR testing, which helps speed up diagnosis. Treatment is time-consuming and has a high risk of complications. Two techniques are used to treat fungal infections of the cornea, surgical and pharmacological, such as the antifungal polyene antibiotics nystatin, natamycin, amphotericin B or thiazole derivatives like fluconazole and voriconazole. For filamentous fungi, natamycin 5% or voriconazole 1% are used at various intervals. Natamycin, despite the much poorer availability of the drug in countries such as Africa, has much better clinical results along with a lower risk of complications, as confirmed by the MUTT. A big problem also is subsequent bacterial superinfection, leading to the need for topical antibiotics. Surgical treatment is used in case of failure of pharmacotherapy, up to 4 weeks after the diagnosis of the disease, but it carries a high risk of complications. In the early stages of the disease, a new cross-linking technique can be considered, which is described as an alternative to direct antifungal or antibacterial treatment.

Key words: fungal keratitis, anti-fungal treatment, ophthalmic infection, cornea

INTRODUCTION

Keratitis can be caused by bacteria, viruses, fungi and protozoa. Through the entry of microorganisms into the corneal periphery, inflammatory infiltrates are formed, which reduce the transparency of the cornea [1]. Fungal pathogens enter the corneal dermis through damaged epithelium leading to necrosis and inflammatory reaction [2]. Fungal keratitis is one of the most common causes of eye diseases worldwide, especially in tropical and subtropical countries. Studies presented by the World Health Organization show that corneal blindness is the second leading cause of blindness. Ocular injuries and corneal ulcers are among the most common causes of corneal blindness [3].

CLINICAL PICTURE

The symptoms that a patient presents with fungal keratitis are similar to those of bacterial ulceration. The patient reports pain, a foreign body sensation, discomfort, blurred vision, excessive tearing, redness of the eye, tearing and the presence of discharge. On physical examination, we see, among other things, ciliary congestion, infiltration in the corneal parenchyma with a gray color, often a Wessely ring, not infrequently an inflammatory reaction in the anterior chamber, roposts as well as deposits on the endothelium that form endothelial plaque [4]. Figures 1 and 2 show examples of the clinical picture of fungal keratitis after several weeks of conservative treatment. Figure 2 additionally shows corneal perforation, which is a complication of a fungal infection.

FIGURE 1

Deep fungal keratitis after several weeks of conservative treatment (1st case).

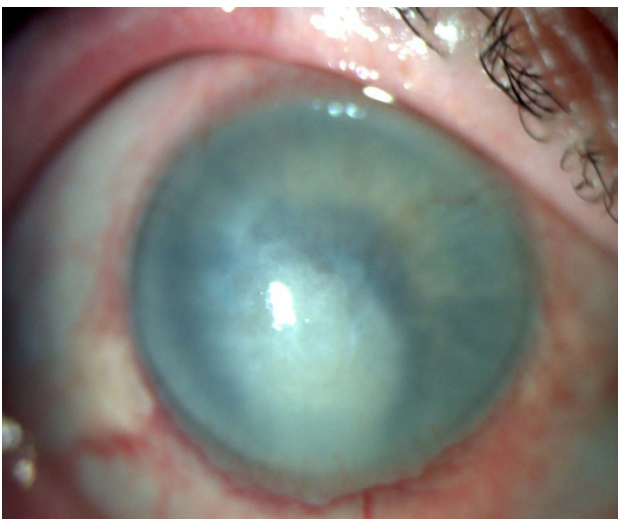
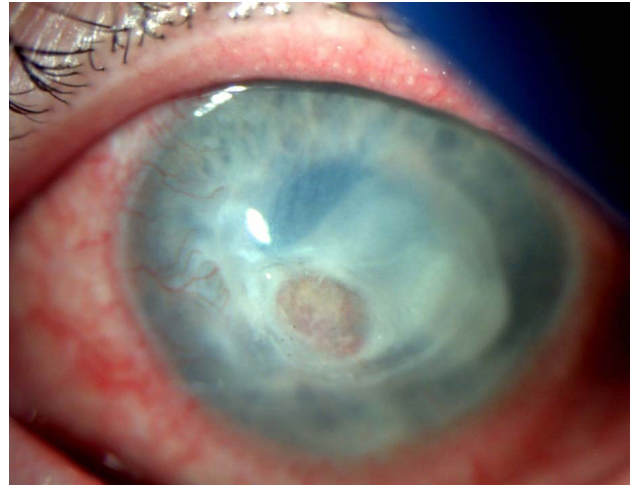


FIGURE 2

Fungal keratitis after weeks of conservative treatment, corneal perforation (2nd case).



DIAGNOSTICS

The diagnostic process should be based on a thorough history, the ophthalmologist, during a conversation with the patient, should try to identify all risk factors that may have influenced the onset of a particular condition, such as ocular trauma. In addition to basic tests such as slit-lamp examination of the eye, we have other methods available to confirm the diagnosis being made. One method is microscopic examination of a preparation taken from the cornea or corneal scrapings. The slide should be prepared in 10% potassium hydroxide and evaluated under the microscope, look for the presence of mycelial filaments or yeast cells. This is a simple, easily accessible and inexpensive diagnostic method [5].

Another tests are to use a direct preparation using the Gram staining technique and culture. The obtained samples should be inoculated on an appropriate medium, in the case of fungi it is Sabouraud medium, it allows the detection of the pathogen in up to 90% of cases, which makes it possible to confirm the fungal etiology of the infection [6].

Genetic tests detecting the fungal genome are used in diagnostics and have high sensitivity. They are less time-consuming to perform than cultures and are ideal for testing samples taken from the surface of the eye, which are not large in volume. The agarose gel electrophoresis PCR method used is gaining popularity and is now available in many diagnostic laboratories. The nested PCR method increases the sensitivity of the test performed, while PCR with real-time readout is a molecular technique highly effective in diagnosing fungal keratitis. This technique additionally allows to analyze high-resolution melting curves,

which allows not only to detect fungi in a given preparation, but also to distinguish yeast from mold fungi and at the same time to differentiate them between different species of yeast [5].

However, an additional very useful test performed in the diagnostic process is optical coherence tomography of the anterior segment of the eyeball, which makes it possible to assess the depth of inflammatory infiltration within the cornea, anterior chamber and iris of the eye. This examination is non-invasive and its replication allows monitoring the progress of therapy [7].

TREATMENT

Fungal keratitis poses a therapeutic challenge for clinicians [8]. A significant proportion of these infections do not respond to pharmacological treatment [2]. Currently available antifungal agents often act fungistatic but not fungicidal, making treatment require prolonged time until the patient's immune defenses are able to completely eradicate the infection [9]. Additionally, there are significant barriers for patients to access treatment, resulting in delays and potentially worse outcomes [10]. Close observation in the hospital setting during treatment is necessary to ensure that the patient's clinical condition does not worsen. The final outcome depends on many factors, such as the patient's general health, immune system status and comorbidities [9]. It should be remembered that the risk of complications such as perforation or scarring is high in every patient.

Pharmacological treatment

Yeast infections are treated by choice with amphotericin 0.15% drops. On the first day of treatment, they should be used every 30 minutes, and then, depending on the clinical condition of the patient, we reduce the frequency of administration of the drug. The above treatment can also be supplemented with fluconazole 0.2% drops applied initially every hour. An alternative treatment choice is 1% voriconazole [4].

In infections caused by filamentous fungi, natamycin at 5% concentration is used every four hours during the day and voriconazole at 1% concentration every hour at day and every two hours at night. Although natamycin has been recognized as an essential drug by the World Health Organization, it is not available in most countries in sub-Saharan Africa, as well as some countries in Asia and Europe [11]. An alternative choice is 1% voriconazole. However, the results of the double-blind, randomized *Mycotic Ulcer Treatment Trials* (MUTT) clinical trial showed significantly better visual acuity after 3 months in patients with threadworm keratitis randomly assigned to topical natamycin 5%, compared to topical voriconazole 1%, with fewer adverse events such as perforation [8]. The superiority

of natamycin over voriconazole has also been confirmed by other studies [12, 13].

In a situation where we have a patient with a deep fungal infection and a ropost, either in a yeast or filamentous infection, general treatment is required. For this purpose, fluconazole 100–400 mg/24 h or voriconazole 100–200 mg twice a day for up to 12 weeks is used [14].

Oral voriconazole is a good drug with good penetration into the aqueous fluid, but the recent *Mycotic Ulcer Treatment Trials II* (MUTT II) showed that this drug did not reduce the rate of perforation or the need for therapeutic keratoplasty [8].

In severe infections, subconjunctival (fluconazole), intrathecal or interstitial (voriconazole) injections can be tried, especially when the infection is accompanied by scleritis [15]. Topical corticosteroids have also been proven to have a positive effect in acute anterior uveitis, but the earliest they can be used is 2 weeks after antifungal treatment [16]. Unfortunately, with fungal keratitis, bacterial superinfections are quite common, which additionally require the administration of topical antibiotics.

As for the penetration into the cornea of the various drugs used in fungal corneal infection, the worst is amphotericin B, which is also characterized by high toxicity. The best bioavailability is with fluconazole and voriconazole, where the latter is characterized by the best penetration into the tissue and sensitivity of the fungi causing inflammation, when using it, unfortunately, there is a greater chance for corneal perforation than when using nystatin [17].

Surgical treatment

Surgical intervention, such as a hollow corneal graft (fig. 3, 4), is an essential part of therapy when the response to pharmacological treatment is poor. This procedure should be performed within 4 weeks of the onset of the disease. However, therapeutic keratoplasty is fraught with the risk of complications, which include recurrent infection (fig. 5), intraocular inflammation and graft rejection [17].

It is worth mentioning the procedure of cross-linking corneal collagen fibers, known as cross-linking (CXL), which, with the help of deactivating proteolytic enzymes and strengthening collagen fibers, inhibits further development of the fungal infection. Phase III studies conducted in 2022 showed positive effects on early stages of fungal as well as bacterial corneal infection. It has been described as an alternative to direct antifungal or bacterial treatment, but it makes sense in the early, superficial stages of corneal infection, while this method is not used for full-thickness inflammation, as it is then ineffective [18]. When corneal perforation occurs, tectonic or therapeutic keratoplasty is usually required to save the eye. Enucleation is the last resort when an uncontrolled inflammatory process causes loss of vision with accompanying pain

FIGURE 3

Fungal keratitis – after hollow corneal transplantation (1st case).

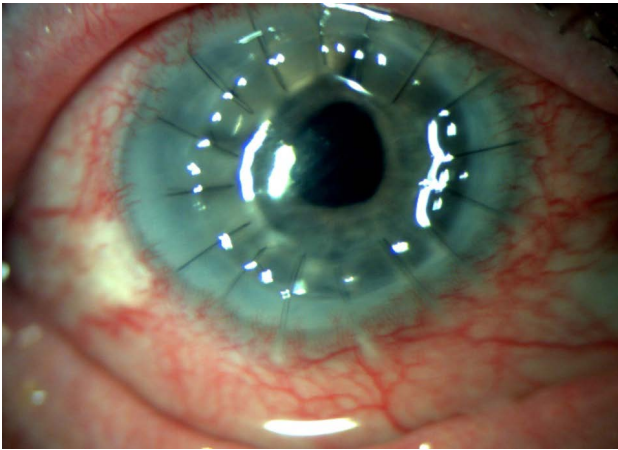


FIGURE 4

Fungal keratitis – after hollow corneal transplantation (2nd case).

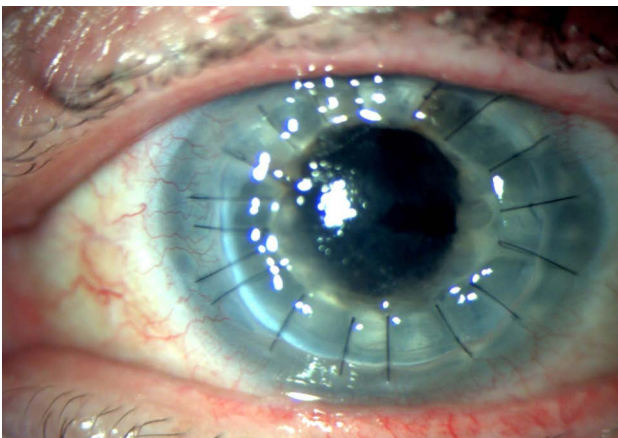
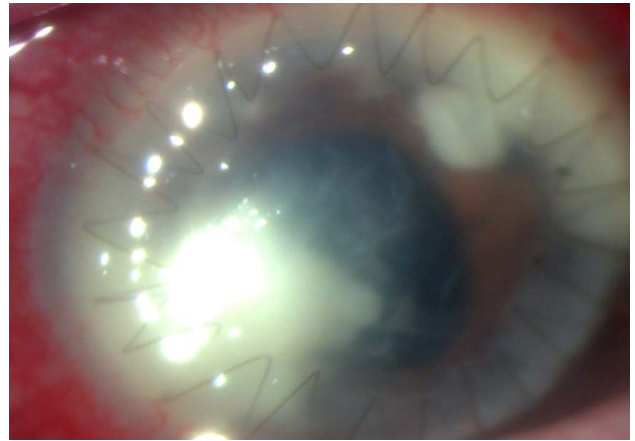


FIGURE 5

Fungal keratitis – intensive recurrence of infection after corneal transplantation (3rd case).



CONCLUSIONS

Fungal keratitis, caused by a variety of fungal species, is among the most common eye disorders worldwide and is one of the leading causes of blindness. For this reason, it is so important to use proper diagnosis and effective treatment.

The diagnostic process should be based on a meticulously collected history, basic examinations such as slit-lamp examination of the eye, and, to confirm the diagnosis, on more accurate diagnostic methods such as microscopic examination of a corneal specimen taken by various techniques, performing cultures and genetic tests, including PCR. Treatment includes pharmacological methods based on antifungal drugs, steroids and sometimes antibiotics, as well as surgical methods such as therapeutic keratoplasty, corneal collagen fiber cross-linking or, as a last resort, enucleation.

Figures: from the authors' own materials.

that cannot be controlled with pharmacotherapy or other treatments.

CORRESPONDENCE

med student **Dominika Prokop**

Andrzej Frycz Modrzewski Academy in Krakow
30-705 Kraków, ul. Gustawa Herlinga-Grudzińskiego 1
e-mail: dominikapropkop98@gmail.com

ORCID

Dominika Prokop – ID – <http://orcid.org/0000-0001-7318-7716>
Alicja Chmura-Hołyś – ID – <http://orcid.org/0000-0003-0733-1542>
Ada Pandey – ID – <http://orcid.org/0000-0001-9467-1005>
Bartłomiej Żaczek – ID – <http://orcid.org/0000-0002-9184-3649>
Ismael Alsoubie – ID – <http://orcid.org/0000-0002-0974-3025>
Bartosz Kuźlik – ID – <http://orcid.org/0000-0001-8028-5525>
Aneta Pyza – ID – <http://orcid.org/0009-0000-5318-1368>
Kinga Czarnacka – ID – <http://orcid.org/0000-0002-6889-6507>
Julia Kaczmarek – ID – <http://orcid.org/0009-0001-2268-6547>
Małgorzata Gawlak – ID – <http://orcid.org/0000-0003-4573-1379>
Maciej Kozak – ID – <http://orcid.org/0000-0001-7993-2588>
Ilona Pawlicka – ID – <http://orcid.org/0000-0003-1556-7678>
Katarzyna Sajak-Hydzyk – ID – <http://orcid.org/0000-0002-1973-2717>
Agnieszka Piskorz – ID – <http://orcid.org/0000-0003-4553-0497>
Anna Roszkowska – ID – <http://orcid.org/0000-0002-8083-3437>

References

1. Wylęgała E. Zapalenie rogówki. *Medycyna Praktyczna*. <https://www.mp.pl/pacjent/okulistyka/chorobyoczu/chorobyrogowkiitwar-dowki/94600,zapalenie-rogowki> (access: 17.03.2023).
2. Rymgayłło-Jankowska B. Grzybicze zapalenie rogówki. *Ophthatherapy*. 2015; 2(6): 123-7.
3. Sharma N, Bagga B, Singhal D et al. Fungal keratitis: A review of clinical presentations, treatment strategies and outcomes. *Ocul Surf*. 2022; 24: 22-30.
4. Hill-Bator A, Bator K. Grzybicze schorzenia powierzchni oka. *Ophthatherapy*. 2018; suppl 1.
5. Nowik KE, Nowik K, Sulik-Tyszka B et al. Diagnostyka grzybiczego zapalenia rogówki. *Aspekty kliniczne. Forum Zakażeń*. 2020; 11(3): 131-4.
6. Austin A, Lietman T, Rose-Nussbaumer J. Update on the Management of Infectious Keratitis. *Ophthalmology*. 2017; 124(11): 1678-89.
7. Wasyluk J. Tomografia optyczna przedniego odcinka oka – nowe perspektywy. *Ophthatherapy*. 2019; 24(4): 287-93.
8. Prajna NV, Krishnan T, Rajaraman R et al.; Mycotic Ulcer Treatment Trial II Group. Effect of Oral Voriconazole on Fungal Keratitis in the Mycotic Ulcer Treatment Trial II (MUTT II): A Randomized Clinical Trial. *JAMA Ophthalmol*. 2016; 134(12): 1365-72. <http://doi.org/10.1001/jamaophthalmol.2016.4096>.
9. Castano G, Elnahry AG, Mada PK. Fungal Keratitis. [Updated 2022 Aug 8]. In: StatPearls [Internet]. Treasure Island (FL): StatPearls Publishing; 2022.
10. Arunga S, Kintoki GM, Gichuhi S et al. Delay along the care seeking journey of patients with microbial keratitis in Uganda. *Ophthalmic Epidemiol*. 2019; 26: 311-20.
11. Prajna NV, Mascarenhas J, Krishnan T et al. Comparison of natamycin and voriconazole for the treatment of fungal keratitis. *Arch Ophthalmol*. 2010; 128(6): 672-8. <http://doi.org/10.1001/archophthalmol.2010.102>.
12. FlorCruz NV, Evans JR. Medical interventions for fungal keratitis. *Cochrane Database Syst Rev*. 2015: CD004241.
13. Sharma S, Das S, Virdi A et al. Re-appraisal of topical 1% voriconazole and 5% natamycin in the treatment of fungal keratitis in a randomized trial. *Br J Ophthalmol*. 2015; 99: 1190-5.
14. Prost M, Jachowicz R, Nowak J. *Kliniczna farmakologia okulistyczna*. 1st ed. Elsevier Urban & Partner, Wrocław 2013: 149-55, 427-9.
15. Yilmaz S, Maden A. Severe fungal keratitis treated with subconjunctival fluconazole. *Am J Ophthalmol*. 2005; 140(3): 454-8.
16. Wylęgała E, Tarnawska D, Dobrowolski D (ed). *Choroby rogówki*. Górnicki Wydawnictwo Medyczne, Wrocław 2015: 87-8.
17. Anshu A, Parthasarathy A, Mehta JS et al. Outcomes of therapeutic deep lamellar keratoplasty and penetrating keratoplasty for advanced infectious keratitis: a comparative study. *Ophthalmology*. 2009; 116(4): 615-23. <http://doi.org/10.1016/j.ophtha.2008.12.043>.
18. Hafezi F, Hosny M, Shetty R et al.; PACK-CXL Working Group. PACK-CXL vs. antimicrobial therapy for bacterial, fungal, and mixed infectious keratitis: a prospective randomized phase 3 trial. *Eye Vis (Lond)*. 2022; 9(1): 2. <http://doi.org/10.1186/s40662-021-00272-0>.

Authors' contributions:

All authors have equal contribution to the paper.

Conflict of interest:

None.

Financial support:

None.

Ethics:

The content presented in the article complies with the principles of the Helsinki Declaration, EU directives and harmonized requirements for biomedical journals.