

Technical aspects and intraoperative factors influencing the efficiency of non-penetrating deep sclerectomy and implantation of PreserFlo™ MicroShunt



Patrycja Soja¹, Piotr Jurowski²

¹ Department of Ophthalmology and Vision Rehabilitation, Medical University of Lodz, Poland
Head: prof. Piotr Jurowski, MD, PhD

² Department of Ophthalmology and Vision Rehabilitation, Medical University of Lodz, Poland
Head: prof. Piotr Jurowski, MD, PhD

HIGHLIGHTS

In Central Europe glaucoma is the third most common cause of total blindness. Finding new options of glaucoma treatment or improvement of existing ones seems to be an important goal in ophthalmic surgery.

ABSTRACT

Glaucoma is a neurodegenerative disorder marked by the death of retinal ganglion cells which causes characteristic vision field loss. At the moment the only well-known risk factor for progression of the glaucoma is intraocular pressure. In this regard the lowering of intraocular pressure became the main focus of treatment.

Different types of glaucoma surgeries have developed over the last decades. Most of them facilitate outflow of aqueous humor; few decrease the production. This article takes into account two of them: non-penetrating deep sclerectomy and implantation of PreserFlo™ MicroShunt.

Deep sclerectomy is a well established non-penetrating type of glaucoma surgery. With use of adjuvant methods such as use of space-maintaining implants, use of viscoelastic agent and use of antimetabolites during procedure it allowed to achieve success rate of standard penetrating surgery with lower rate of complications.

PreserFlo™ MicroShunt implantation is a promising new filtration procedure for glaucoma treatment. First published studies show promising efficacy and safety outcomes, although further research is needed.

Key words: glaucoma, PreserFlo™ MicroShunt, non-penetrating deep sclerectomy, glaucoma surgery, collagen implant

INTRODUCTION

Glaucoma is a neurodegenerative disorder marked by the death of retinal ganglion cells which causes characteristic vision field loss. It is the second leading cause of blindness worldwide after cataract. The most common type is open-angle glaucoma in which the outflow of aqueous humor remains open. At the moment the only well-known risk factor for progression of the glaucoma is intraocular pressure (IOP). In this regard intraocular pressure became the main focus while devising methods of treatment.

Different types of glaucoma surgeries have developed over the last decades. Most of them facilitate outflow of aqueous humor, few decrease the production. In this article we will focus on two of them: non-penetrating deep sclerectomy and implantation of PreserFlo™ Microshunt, pointing out the technical aspects of surgery important for maintaining their efficiency.

NON-PENETRATING DEEP SCLERECTOMY

Non-penetrating deep sclerectomy (NPDS) was first described in 1989 by Kozlov and Fyodorov, but first reports of non-penetrating filtering glaucoma surgery were published as far back as 1964. Krasnov described a procedure called sinusotomy, in which a band of sclera is removed parallel to the limbus exposing the Schlemm's canal, however the inner wall of Schlemm's canal and trabecular meshwork were left intact [1]. Unfortunately sinusotomy was not as efficient as expected and difficult to perform without the assistance of operating microscope, which were not easily accessible at the time. Over the next several decades non-penetrating procedures were further developed and in 1989 Kozlov and Fyodorov described the deep sclerectomy.

The efficiency of NPDS is based on creating a trabeculo-De-escemet's window, eventually on removal of endothelium and juxtacanalicular tissue of the trabecular meshwork.

The conjunctiva and Tenon's capsule are dissected at the limbus with following deep incision posteriorly under Tenon's capsule (fig. 1). If necessary a gentle diathermy of bleeding vessels is performed (fig. 2). A superficial scleral flap of the one third scleral thickness is created with the base at the limbus. The shape of the flap can be triangular, trapezoidal or rectangular and what is important, is extended upward into a clear cornea (fig. 3, 4). Underneath, a deep scleral flap is dissected and excised at its base, uncovering the roof of the Schlemm's canal (fig. 5). It is helpful to perform paracentesis at this point to allow the outflow of aqueous humor and as a result to decrease bulging of the trabeculum. Following, the internal wall of the Schlemm's canal is gently peeled with forceps, which augments the aqueous outflow from the anterior chamber (fig. 6). The cohesive viscoelastic agent can be injected into the ostia of the opened Schlemm's canal and under the scleral flap (fig. 7). The superficial scleral flap is

FIGURE 1

Dissection of the conjunctiva and Tenon's capsule.

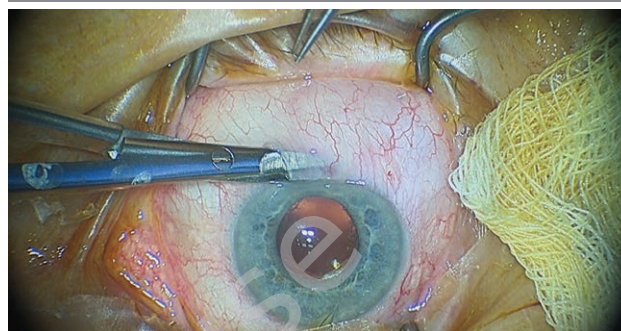


FIGURE 2

Gentle diathermy of bleeding vessels.

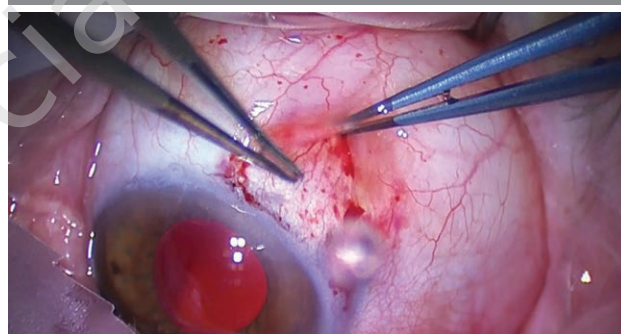


FIGURE 3

Shaping of the superficial scleral flap.

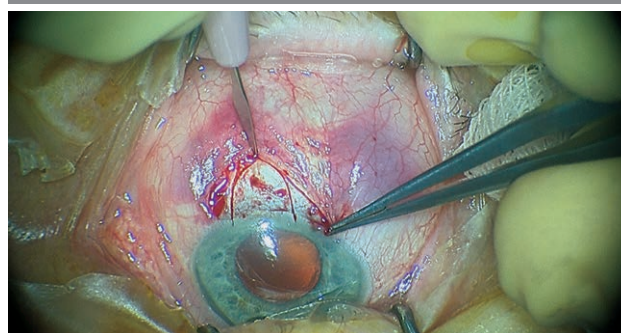


FIGURE 4

Dissection of the superficial scleral flap.

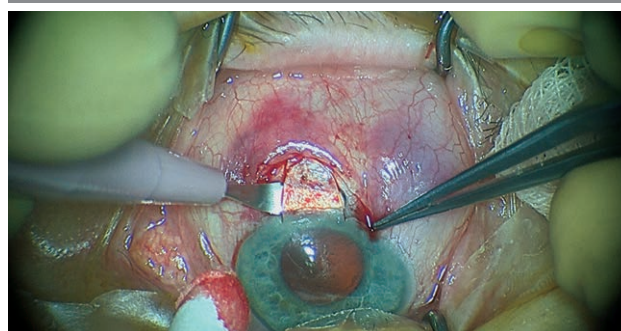


FIGURE 5

Dissection of the deep scleral flap to reach the roof of the Schlemm's canal.

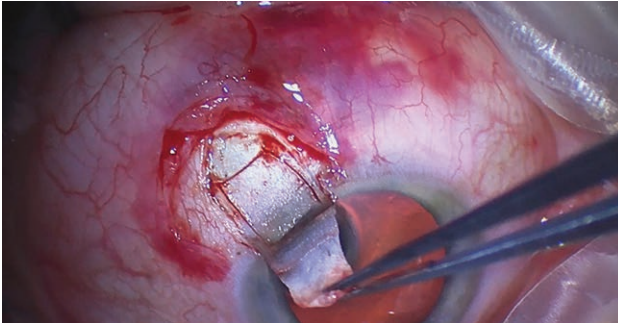


FIGURE 6

Peeling of the internal wall of the Schlemm's canal.

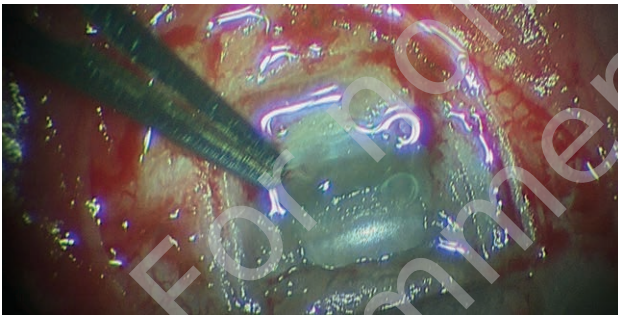
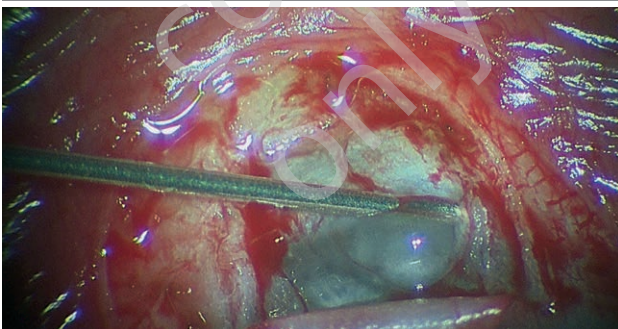


FIGURE 7

Injection of a cohesive viscoelastic agent into the ostia of the Schlemm's canal.



repositioned and can be sutured to create a smooth surface. As the final step the conjunctiva is sutured (fig. 8). Additional steps to improve the efficiency of NPDS:

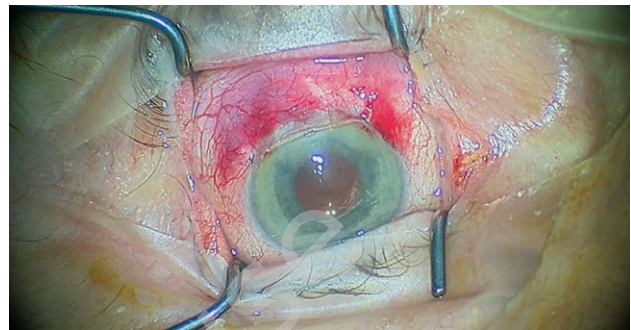
Application of antimetabolites intraoperatively

To reduce the risk of postoperative fibrosis antimetabolite can be applied after acquiring the hemostasis. The most commonly used antimetabolites are mitomycin C and 5-fluorouracil.

Kozobolis et al. compared NPDS and NPDS with the use of mitomycin C. The qualified success rate (which was de-

FIGURE 8

Suturing of the conjunctiva.



scribed as $IOP \leq 21$ mmHg with or without medications) at the end of the 36th month was 95% in the group with mitomycin C and 72,5% in the group without mitomycin C. The difference was statistically significant starting from 18th month to the end of the follow-up period [2].

Use of space-maintaining implants

One of the ways to maintain the scleral space open during the initial healing period is use of a space maintaining implants.

Sanchez et al. in their study examined the results of NPDS compared with NPDS with collagen implant in a group of 168 patients. 86 patients underwent operation with the use of the implant, and 82 – without. The results demonstrated comparable early postoperative success rate and significantly higher long-term postoperative success rate in the group that underwent operation with the use of the collagen implant [3]. Shaarawy and Mermound shared similar conclusions. In their study they performed NPDS in one eye and NPDS with collagen implant in the contralateral eye of the same patient. Complete success rate, defined as an intraocular pressure (IOP) below 21 mmHg without medication was 38% for eyes treated with NPDS and 69% for eyes operated with the use of collagen implant [4].

Commonly two types of implants can be distinguished: absorbable and non-absorbable. Various materials have been used in production of different implants with similar success rate [5].

Another approach is use of viscoelastics. Injection of high molecular weight viscoelastic substance into both sides of the ostia of Schlemm's canal stretches lumen, disrupts its inner and outer walls and disorganizes the juxtacanalicular zone. It also stops the recurrent flow of blood into the canal from episcleral veins and decreases influx of proinflammatory and healing factors.

CO₂ laser-assisted sclerectomy surgery (CLASS)

During this procedure the carbon dioxide (CO₂) laser energy is used to create the deep scleral flap and remove the roof

of the Schlemm's canal. The rest steps of the procedure do not differ from the common NPDS performed with a surgical knife. What is important in this surgical technique, the infrared electromagnetic transmission of CO₂ laser is absorbed and blocked by aqueous humor which prevents deeper penetration into the eye tissue. This is especially significant at the level of the Schlemm's canal. It is suggested that CLASS is much less technically demanding for deep dissection compared with the manual technique.

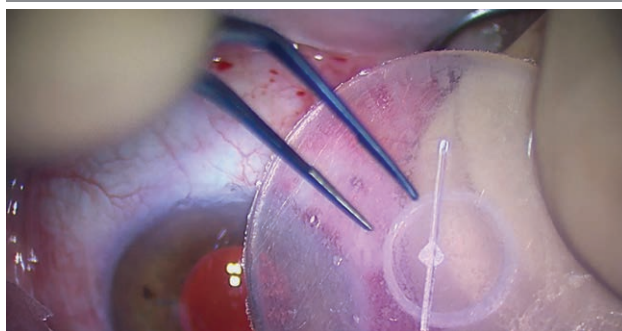
PRESERFLO™ MICROSHUNT

The PreserFlo™ MicroShunt (formerly known as InnFocus device) received Conformité Européenne marking in Europe in 2012. The device is composed of SIBS poly(styrene-block-isobutylene-block-styrene), which material was previously used in cardiac surgery. The medical observations showed that the implantation of the SIBS coated cardiac stent keep high safety profile and low postoperative inflammation [6]. The PreserFlo™ MicroShunt is 8,5 mm long shunt with 70 µm lumen. The device is divided by a 1 mm fin into two segments: distal (3 mm) and longer one, proximal (4,5 mm) (fig. 9). The Hagen-Poiseuille equation for laminar flow was used during construction of the shunt. Therefore, providing that aqueous production is > 2 uL/min and taking into account the outflow rate of aqueous through the shunt, postoperative IOP should be maintained above 5 mmHg, protecting the eye from consequences of hipotony. There are some important points to be considered when it comes to efficiency of implantation of the PreserFlo™ MicroShunt.

The beginning of the operation seems to be similar to the non-penetrating deep sclerectomy procedure. A fornix-based conjunctival and Tenon's flap is dissected in the nasal or superior quadrants. It is helpful to inject an anesthetic agent or a balanced salt solution (BSS) under conjunctiva prior to its dissection (fig. 10). The gentle diathermy of bleeding vessels should be performed. As far as is known two main factors influencing healing and fibrosis of a bleb

FIGURE 9

Presentation of the PreserFlo™ MicroShunt.



postoperatively are growth factors in aqueous humor and that within the blood. Sponges soaked with mitomycin C are placed under the conjunctiva for 2 to 3 minutes (fig. 11).

FIGURE 10

Injection of balanced salt solution under conjunctiva prior to its dissection.

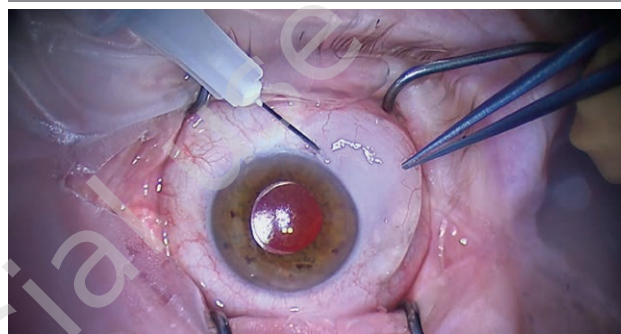
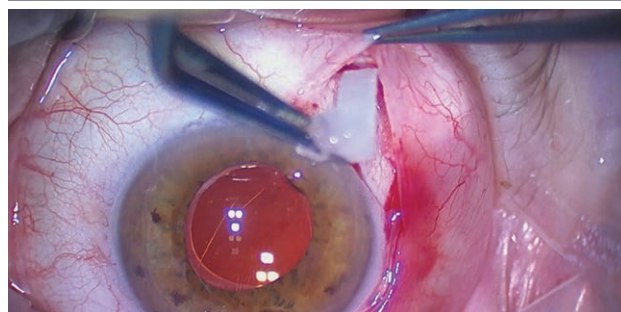


FIGURE 11

Use of mitomycin C during operation.



Time of exposure depends on dosage of mitomycin C used. It is important to keep sponges far away from the limbus. The area is then irrigated with BSS. The sclera is marked 3 mm from the middle area of the surgical limbus. A scleral pocket is fashioned with an angled triangular knife starting from a distally marked position moving upward. An angled 25-gauge needle is used to create an opening into the anterior chamber. The angle of needle movement is an extension of the previously made pocket. The PreserFlo™ MicroShunt is inserted through the ostia of the created tunnel into the anterior chamber. The place and direction of the intrascleral tunnel is crucial for proper placement of the tube, as much parallel to the iris plane as it is possible (fig. 12). The fin of the device should be introduced and fit tightly into the scleral pocket. After implantation the shunt's tube should be checked for drop formation at its distal end. There are a few ways to achieve that: pressing on the eyeball, filling the anterior chamber with BSS or injecting fluid backward through the tube into the anterior chamber (fig. 13). The last but very important step is the reapproximation of Tenon's

FIGURE 12

Implantation and proper placement of the PreserFlo™ MicroShunt within the anterior chamber.

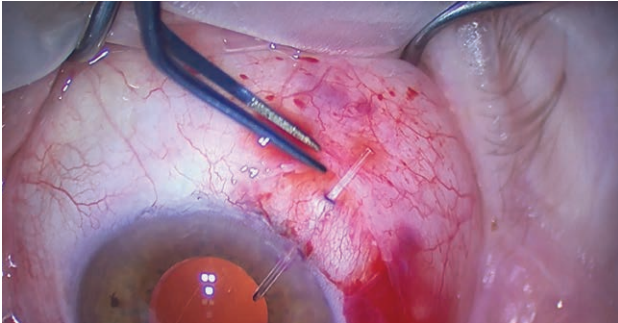
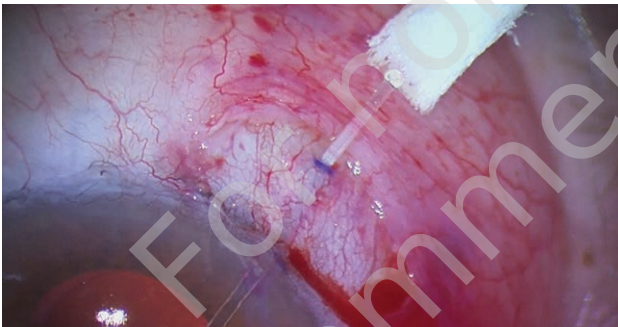


FIGURE 13

Drop formation at the PreserFlo™ MicroShunt's distal end.



capsule and conjunctiva in the primary place. To create a filtration bleb Tenon's capsule and conjunctiva are carefully sutured together (fig. 14).

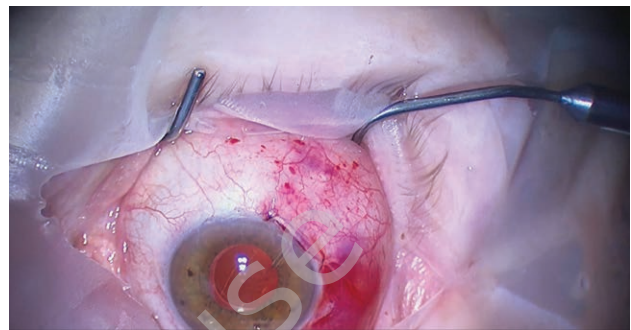
PreserFlo™ MicroShunt can be implanted as a stand-alone treatment or in conjunction with cataract surgery.

Application of antimetabolites during the surgery is crucial to augment aqueous outflow postoperatively.

Use of mitomycin C is a standard procedure during PreserFlo implantation. Most common concentration is 0,2 mg/ml

FIGURE 14

Creation of the filtration bleb.



up to 0,4 mg/ml. At the moment there is no compelling evidence which dose is more effective.

Use of anti-vascular endothelial growth factor (anti-VEGF) can be an option.

Subconjunctival injection of anti-VEGF postoperatively seems to be a logical method for prevention of the bleb scarring. However currently there are no available studies connected to the subject.

CONCLUSION

Finding new surgical options or improvement of existing ones is one of the most important goals of the glaucoma treatment.

Deep sclerectomy is a well established non-penetrating but filtrating type of glaucoma surgery. With additional use of adjuvant methods, this technique is able to achieve a success rate comparable to penetrating surgery with lower occurrence of complications.

On the other hand, PreserFlo™ MicroShunt implantation is a relatively new procedure for glaucoma treatment. First published studies show promising efficacy and safety outcomes, although further research is needed.

Figures: from the author's own materials.

CORRESPONDENCE

Patrycja Soja, MD

Department of Ophthalmology and Vision Rehabilitation,
Medical University of Lodz
90-549 Łódź, ul. Żeromskiego 113
e-mail: patrycjasoja@poczta.onet.pl

ORCID

Patrycja Soja – ID – <http://orcid.org/0000-0002-7057-1373>

Piotr Jurowski – ID – <http://orcid.org/0000-0003-1471-8577>

References

1. Varga Z, Shaarawy T. Deep sclerectomy: safety and efficacy. *Middle East Afr J Ophthalmol*. 2009; 16(3): 123-6. <http://doi.org/10.4103/0974-9233.56223>.
2. Kozobolis VP, Christodoulakis EV, Tzanakis N et al. Primary deep sclerectomy versus primary deep sclerectomy with the use of mitomycin C in primary open-angle glaucoma. *J Glaucoma*. 2002; 11(4): 287-93. <http://doi.org/10.1097/00061198-200208000-00003>.
3. Sanchez E, Schnyder CC, Sickenberg M et al. Deep sclerectomy: results with and without collagen implant. *Int Ophthalmol*. 1996; 20(1-3): 157-62. <http://doi.org/10.1007/BF00212963>.
4. Shaarawy T, Mermoud A. Deep sclerectomy in one eye vs deep sclerectomy with collagen implant in the contralateral eye of the same patient: long-term follow-up. *Eye (Lond)*. 2005; 19(3): 298-302. <http://doi.org/10.1038/sj.eye.6701469>.
5. Oana S, Vila A, Suriano M et al. A New Implant for Deep Sclerectomy: Esnoper®. *J Curr Glaucoma Pract*. 2011; 5(3): 40-3. <http://doi.org/10.5005/jp-journals-10008-109>.
6. Strickler F, Richard R, McFadden S et al. In vivo and in vitro characterization of poly(styrene-b-isobutylene-b-styrene) copolymer stent coatings for biostability, vascular compatibility and mechanical integrity. *J Biomed Mater Res A*. 2010; 92(2): 773-82. <http://doi.org/10.1002/jbm.a.32418>.

Authors' contributions:

Patrycja Soja: literature review and selection, writing of the manuscript, editorial corrections; Piotr Jurowski: content supervision.

Conflict of interest:

None.

Financial support:

None.

Ethics:

The content presented in the article complies with the principles of the Helsinki Declaration, EU directives and harmonized requirements for biomedical journals.