

Levator palpebrae superioris lengthening in the treatment of keratopathy caused by lagophthalmos after orbital inflammation



Rafał Woś¹, Dorota Pojda-Wilczek^{1,2}

¹ Department of Ophthalmology, Professor Kornel Gibinski University Clinical Center of the Medical University of Silesia, Katowice

Head: prof. Dorota Wyględowska-Promieńska, MD, PhD

² Department of Ophthalmology, Faculty of Medical Sciences in Katowice, Medical University of Silesia, Katowice

Head: prof. Dorota Wyględowska-Promieńska, MD, PhD

HIGHLIGHTS

Lagophthalmos presents a significant challenge that requires not only topical treatment but also an appropriate surgical approach.

ABSTRACT

This study aims to evaluate the efficacy of various management strategies for lagophthalmos in a 56-year-old female patient, with a focus on both non-surgical and surgical interventions.

The patient underwent an array of non-surgical treatments, including artificial tears, ointments, and therapeutic contact lenses, aimed at maintaining ocular surface integrity. For surgical intervention, the study compared the outcomes of gold weight implantation (GWI), platinum weight implants, modified tarsorrhaphy (MT), and the elongation of the aponeurosis levator superioris muscle. Non-surgical management provided symptomatic relief and temporary protection of the corneal surface. Botulinum toxin A injection may result in improved eyelid closure without significant adverse effects. Surgically, GWI and platinum implants effectively reduced corneal exposure, though the latter presented fewer complications. MT proved advantageous in terms of accessibility and cost. The elongation technique showed improved aesthetic and functional outcomes, as evidenced by patient satisfaction scores.

Key words: eyelid, upper eyelid, lagophthalmos

INTRODUCTION

Keratopathy, a pathological alteration of the cornea, is a significant ophthalmological concern. Its origins span infections, trauma, degenerative changes, and systemic diseases. Among these, lagophthalmos, characterized by an inability to achieve complete eyelid closure, emerges as a unique cause, exposing the cornea to potential harm. This exposure can lead to dry eye syndrome (DED), a condition where the eye does not produce tears properly or when the tears are not of the correct consistency and evaporate too quickly [1]. DED is not just a minor complaint but a disease that shares many features with autoimmune diseases [2, 3]. It has been identified as an inflammatory disease with a significant impact on the patient's quality of life [4, 5]. DED can be associated with inflammation and damage to the eye's surface, further exacerbating keratopathy [6].

Lagophthalmos, a condition characterized by the inability to close the eyelids completely, poses a significant threat to the integrity of the cornea. In the absence of these protective mechanisms, as seen in lagophthalmos, the cornea becomes vulnerable to a series of destructive changes.

One of the most severe complications arising from lagophthalmos is exposure keratopathy (EK) is a degenerative disease of the cornea, primarily resulting from prolonged exposure of the ocular surface to external environmental factors [7].

The primary cause of EK is the inability of the eyelids to close completely, leading to prolonged exposure of the cornea to the external environment. Lagophthalmos is a condition where there's an inability to close the eyelids completely. It can result from other underlying conditions or traumas [8, 9]. Facial nerve palsy causes the paralysis of facial muscles that prevent the proper closure of the eyelids [10] and lead to lagophthalmos and subsequent EK. Chronic orbital inflammation, as detailed in this case study, can also lead to fibrosis of the aponeurosis levator palpebrae superioris, which consequently results in lagophthalmos.

When the cornea is continuously exposed, it becomes susceptible to drying. The natural tear film that coats the eye and provides lubrication gets disrupted. Without this protective layer, the eye becomes vulnerable to infections, injuries, and other external irritants. Over time, this can lead to the development of corneal ulcers, scars, and vision loss [9]. Patients may also complain about foreign body sensation, burning, increased tearing, and intermittent blurry vision [11]. This condition may also increase the risk of infections, as the protective barrier of the eye is compromised, making it more vulnerable for bacteria and other pathogens to cause infection [12]. The clinical manifestations of EK are graded based on their severity (tab. 1) [13].

TABLE 1

The grades of clinical manifestations of EK.

Grade	Manifestation
I	Punctate epithelial erosions (PEEs) involving inferior third of cornea
II	PEEs involving more than the inferior third of corneal surface
III	Macro epithelial defect (MED)
IV	Stromal whitening in the presence of epithelial defect (SWED)
V	Stromal scar
VI	Microbial keratitis

In patients with lagophthalmos surgical interventions, including keratoplasty, autoconjunctivoplasty, and permanent partial tarsorrhaphy, have been proposed as an effective treatments to preserve the visual function in such eyes [14]. They also require constant moisturizing eye drops preferably with trehalose for its bioprotective characteristics [15]. Orbital tissue inflammation, a multifaceted and intricate condition, arises from a numerous of etiologies. These range from localized infections such as sinusitis to systemic conditions that lead to the blood-borne spread of infections to the orbital region [16]. Notably, pathogens like *Staphylococcus aureus* and *Streptococcus* species have been identified as frequent pathogens, resulting in severe complications include ptosis, diplopia, raised retrobulbar resistance, globe dystopia and can also compromise vision [17–19].

This case report delves into a unique presentation where a patient, after suffering from orbital tissue inflammation due to a Methicillin-sensitive *Staphylococcus aureus* (MSSA) infection, developed keratopathy as a consequence of lagophthalmos. The subsequent surgical intervention, involving the graft of the aponeurosis levator palpebrae superioris muscle, not only rectified the eyelid malposition but also brought about significant symptomatic relief to the patient.

CASE PRESENTATION WITH ILLUSTRATIONS AND FIGURES

A 56-year-old female patient presented with complaints of limited eye mobility accompanied by double vision, poor abduction, and chronic inflammation of the left orbital tissues resulting from a MSSA infection. Diagnostic evaluation comprised a computed tomography scan of the paranasal sinuses without contrast which unveiled an almost complete absence of the nasal septum and absence of nasal conchae. A pronounced nasal cavity was observed which communicated with both the maxillary sinus and sphenoid sinus regions. The partially preserved sphenoid sinus was filled with a thickened mucosal lining, and slight parietal thickening of the mucosa was discerned within the nasal cavity's lateral walls, specifically where the maxillary sinuses are anatom-

ically located. A fragmentary section of the nasal septum was visible posteriorly. Notably, a polypoid thickening of the mucosa, about 16 mm in size and of high density suggestive of a protein-rich retention cyst, was observed within the nasal cavity's lateral wall. The frontal sinuses were found to be hypoplastic, with the right frontal sinus completely filled with a thickened mucosal lining, while the left remained well-aerated.

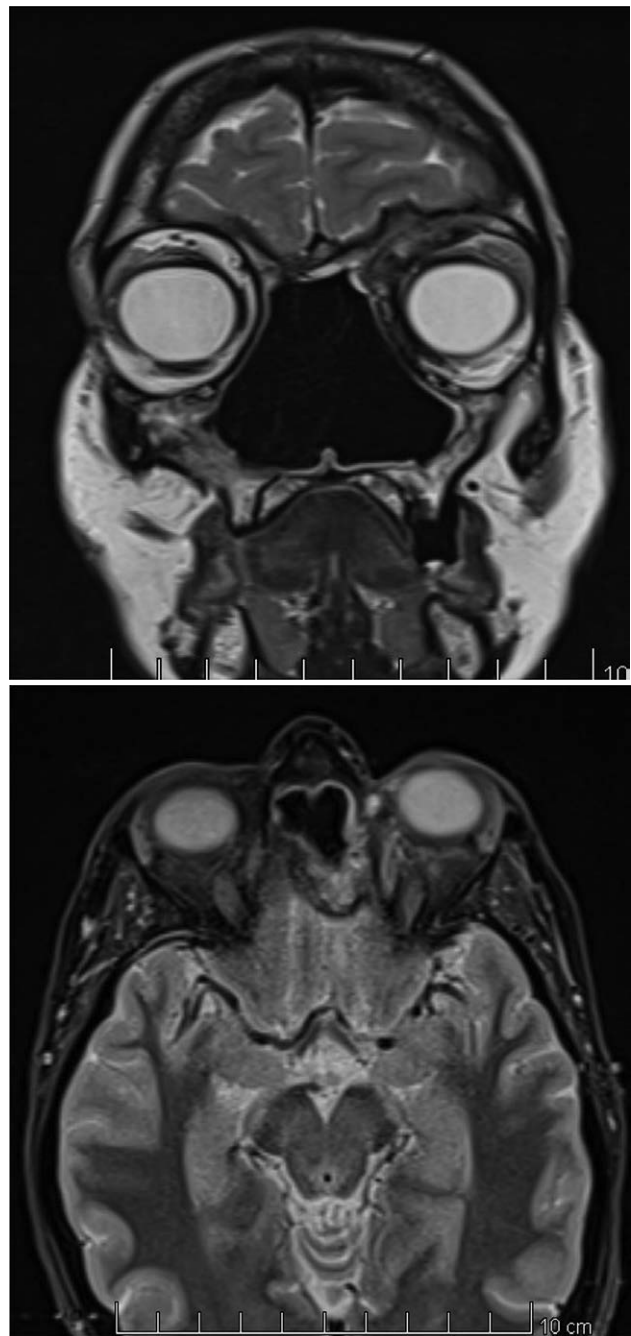
Clinically, the patient's orbital tissues showed inflammation, evident by painful and reddened periorbital swelling. This was accompanied by rapidly escalating symptoms, which included reduced visual acuity, double vision, color vision disturbances, heightened intraocular pressure, and painful impairment of ocular motility. A nasal swab culture ascertained the presence of the pathogen MSSA. Following consultation at the Department of Immunology and Allergology aimed at diagnosing immune deficiencies stemming from recurrent sinusitis, no findings related to allergology or immunology were noted.

An magnetic resonance imaging (MRI) disclosed stranded infiltration of the adipose tissue, which involved the medial rectus and superior oblique muscles and extended to both the superior and inferior rectus muscles. This infiltration had an upward protrusion towards the anterior cranial fossa in the region encompassing the base of the frontal lobes and the olfactory brain. Irregular enhancement was detected post contrast medium administration, with additional enhancement observed along the base of both the right and left frontal lobes and the meninges at a similar level. The T2 MRI sequence of the right and left frontal lobes displayed elevated signal bands indicative of edematous changes. Furthermore, inflammatory changes were prominent in the right frontal sinus. The left eyeball, barring slight downward displacement and lack of pathological signals, was encircled by this pathological infiltration. Moreover, the left lacrimal gland appeared enlarged in contrast to the right, suggesting inflammatory alterations (fig. 1).

An ophthalmological examination provided the following findings: the right eye's anterior segment and fundus were within normal limits. The left eye showed limited mobility, scarred upper eyelid drooping, and a medial eyelid-orbital adhesion causing incomplete eyelid closure (fig. 2). The left eye's fundus was deemed normal. Vision was recorded as 20/20 for both eyes. Intraocular pressure measurements were 17 mmHg for the right eye and 16 mmHg for the left. Ocular motility degrees for the right eye were 41 superior, 59 inferior, 52 lateral, and 42 medial. For the left eye, these were 29 superior, 40 inferior, 23 lateral, and 18 medial. Ocular protrusion measurements for both eyes were consistently 16 mm, with a base of 116 on exophthalmometer. Further examination revealed a narrow filtration angle, thus qualifying the patient for prophylactic iridotomy (IRT) in both eyes. Pattern visual evoked potentials (VEP) for the right eye dis-

FIGURE 1

MRI Scans (description in the text).



played no significant pathology, while for the left eye showed marginally reduced amplitudes and extended latencies post a 15-minute stimulation, suggesting minor optic nerve atrophy devoid of pronounced compressive neuropathy (fig. 3). For treatment, the patient was prescribed azithromycin 0.5 g orally, gentamycin nasal drops administered five times daily, an intravenous dose of methylprednisolone 4 g followed by an oral regimen starting from 84 mg, and a combination of amoxicillin and clavulanic acid 1.2 g. Topical treatment for the left eye consisted of hyaluronic acid eye drops used

FIGURE 2

Lagophthalmos and conjunctival irritation of the left eye – before the surgery.

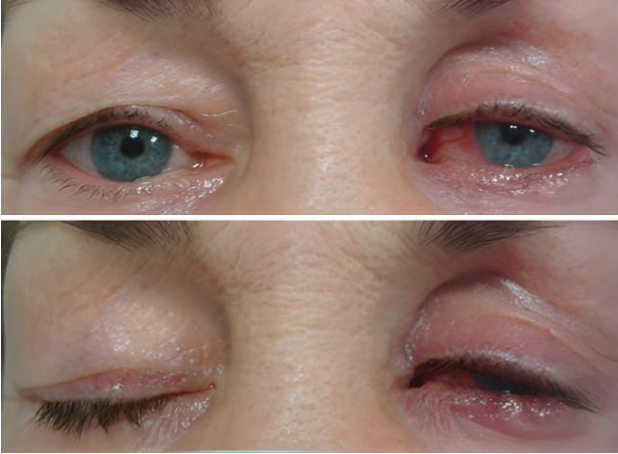

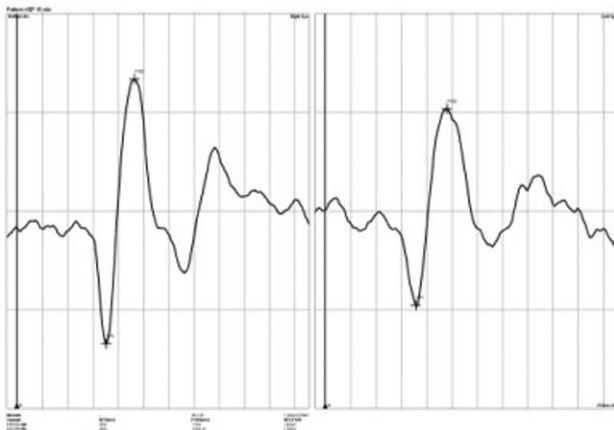
FIGURE 4

Visible significant reduction of lagophthalmos – 12-day post-operatively.

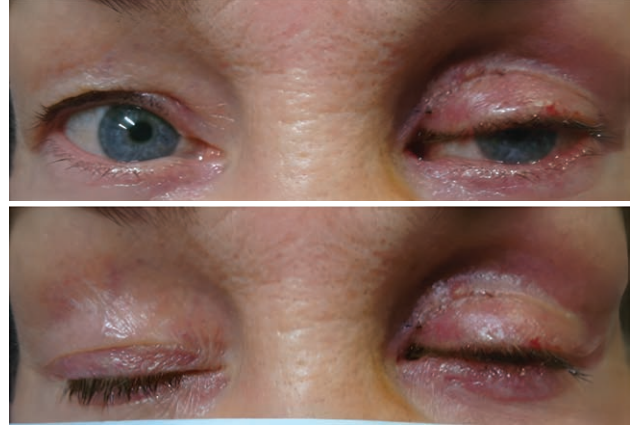

FIGURE 3

VEP pattern result (description in the text).



five times daily, dexpanthenol eye gel applied 3–5 times daily, and a nightly application of a vitamin A ointment. Subsequent to treatment, marked improvement in the local condition was observed, along with pain alleviation and enhanced mobility. However, due to the chronic inflammation observed on the eye surface and the initial signs of corneal ulceration, a procedure to release adhesions in the left orbit was recommended, combined with an autologous graft of the aponeurosis of the levator palpebrae superioris muscle, aimed at elongating the upper eyelid. Following the eyelid reconstruction, the patient's 12-day post-operative evaluation depicted a promising outcome: the eye presented without any injection, and the cornea was devoid of any infiltration. The patient reported a significant subjective improvement, particularly marked by the alleviation of pain and photophobia (fig. 4).

However, one year after the procedure, the recurrence of lagophthalmos occurred. This was accompanied by keratopathy, attributed to the advancing inflammation within the orbit. Concomitantly, an inflammatory infiltrate was observed on the eyeball, which was of a granulomatous nature. Further radiological assessment through MRI highlighted a pathological infiltrate in the left orbit encircling the eyeball. This infiltrate extended up to the apex of the nasal cavity and protruded into the anterior cranial fossa. The enhancement following the administration of contrast was indicative of inflammatory changes.

DISCUSSION

Lagophthalmos, the inability to close the eyelids completely, is a condition that can arise from various etiologies, including advanced peripheral facial paralysis, post-surgical complications, malignant tumors, post-inflammatory deformation, and idiopathic causes like Bell's palsy [20]. The primary manifestation of this condition is the irritation caused by tear film destabilization, DED manifestation to complications such as keratitis, corneal abrasion, potential vision loss, and even blindness [21].

In the presented case, the patient, a 56-year-old female, exhibited symptoms of lagophthalmos following an orbital inflammation caused by *Staphylococcus aureus* infection. The recurrent and chronic inflammation led to a significant reduction in eye mobility, pain, and keratopathy due to the inability to close the eyelids completely. The patient's condition was further complicated by the presence of a nearly complete absence of the nasal septum and nasal conchae, suggesting a long-standing infection and inflammation. The management of lagophthalmos both surgical and non-surgical methods. Temporary solutions like eye-patching and lubricant drops can be beneficial when spontaneous

recovery is expected in the short term. However, in cases of lagophthalmos or when quick recovery isn't anticipated, surgical interventions become necessary [20].

In milder cases or as adjuncts to surgical treatments, non-surgical methods like artificial tears, ointments, and therapeutic contact lenses are vital. These play a crucial role in managing complications of lagophthalmos, such as DED, keratopathy, or keratitis.

The ocular surface's physiological equilibrium is contingent upon the integrity of the tear film, a tri-layered, biochemically intricate fluid essential for corneal homeostasis. By facilitating nutrient transport, proffering antimicrobial defense, and ensuring a polished refractive interface, the tear film is fundamental to ocular health.

In conditions such as lagophthalmos, this tear film's homeostasis is perturbed, with destabilization arising from increased tear evaporation and diminished blink dynamics. Ophthalmic lubricants become instrumental in these scenarios, aiding in tear film reconstitution. By doing so, they fortify the cornea against desiccation and potential pathogenic threats.

Given the cornea's avascular nature, its metabolic demands are predominantly met through the tear film. A desiccated cornea becomes predisposed to microtraumas, manifesting as corneal abrasions [22]. These injuries, besides eliciting pain, can serve as entry points for microbial infiltration. Within this context, ophthalmic lubricants provide a safeguarding layer, significantly reducing the potential for corneal damage.

The inherent antimicrobial properties of the tear film play a crucial role in defending against ocular pathogens. A compromised tear film, therefore, augments the eye's susceptibility to infectious etiologies. Specific ophthalmic formulations, particularly those infused with antimicrobial agents, provide prophylaxis against potential pathogenic intrusion, thus alleviating the likelihood of conditions such as bacterial conjunctivitis or keratitis. In this context, the disaccharide trehalose, inherent to certain bacterial phenotypes, has gained interest. With its bioprotective attributes, trehalose delineates a potential adjunct in ocular surface protection and defense [23].

Patients with ocular surface dysfunction often report a constellation of symptoms, ranging from ocular grittiness to a persistent foreign body sensation. The judicious use of lubricating eye drops offers symptomatic palliation, enhancing the patient's ophthalmic and overall well-being [24]. Clinical data underscore the potential of trehalose-infused formulations. For instance, a combined trehalose and hyaluronic acid formulation demonstrated enhanced therapeutic outcomes in moderate-to-severe DED, with both symptomatic relief and improved functional outcomes [24].

In surgical scenarios, particularly post-procedural phases following interventions for lagophthalmos, such as gold weight

implantation, there exists a heightened propensity for ocular surface desiccation. This, a byproduct of surgical manipulation and transient blink reflex suppression, can be reduced with liberal ophthalmic lubricant application, expediting epithelial healing and minimizing post-operative discomfort. Furthermore, therapy involving botulinum toxin A (BTX-A), a potent neurotoxin, has emerged as a valuable alternative for the treatment of lagophthalmos. BTX-A is injected into the upper eyelid levator muscle to perform temporary chemodeneration of the levator palpebrae superioris [25]. By this method improved eyelid closure and reduced EK can be achieved. Furthermore, BTX-A can be used to manage DED, by reducing corneal exposure and improving tear film stability. The study [25] found that out of 21 patients, only one developed incomplete ptosis due to inadvertent subcutaneous BTX injection. The remaining 20 patients had complete ptosis within 48 h, and none showed superior rectus muscle underaction. This suggests that the transconjunctival BTX-A injection is not only effective but above all safe technique. In another study BTX-A injection into the levator palpebrae superioris muscle created protective ptosis in 21 cases of indolent ulceration, and, prophylactically, in 4 cases of neuroparalytic keratitis. Of the indolent ulcers, 90% healed completely. Recovery of levator function was complete in 8.5 weeks on average [26].

When conservative non-operative modalities prove ineffective, multiple surgical strategies can be employed for patient management. They consist of both implanting metals, tarsorrhaphy or more refined techniques like lengthening of levator muscle.

Gold weight implantation (GWI) in the upper eyelid has emerged as a frequently adopted treatment for paralytic lagophthalmos. This treatment is primarily aimed at preventing corneal exposure and restore ocular surface area moisture. The standard weights are made of 99.99% gold and are specially rounded, which allows an exact match to the curvature of the upper eyelid. Gold weights have many advantages: they are well tolerated as gold is a bio-inert material that does not affect MRI and properly placed implants remain invisible to the environment. If necessary, they can be removed from the tissue of the upper eyelid without visible scarring [10].

Extrusion of the gold weight is one of the most common complications of lid loads. It can happen through the skin or through the conjunctiva.

Berghaus et al. used a flexible platinum chain of their own design in 30 patients and compared the outcomes with 33 patients operated with the same technique but using a gold implant [27]. As the former showed fewer complications with better results, they decided to discontinue the use of gold plates [28].

A more recent technique involves the use of platinum weight implants placed between the levator aponeurosis and inner

septum. This method aims to reduce complications associated with GWI, such as implant visibility and extrusion. Platinum, due to its smaller size and greater thinness, is considered superior to gold [28].

Modified tarsorrhaphy (MT) technique, simpler in execution, can be performed even in rural settings, making it more accessible and cost-effective, especially for patients from lower socioeconomic backgrounds. This technique is divided into 3 steps. First involves lid crease incision and orbicularis dissection until tarsal plate, conjunctival eversion and ballooning, levator recess. Second step is lateral tarsorrhaphy with canthotomy, lateral cantholysis, and excision of upper and lower lid margins as long as 10 mm from the lateral canthus to the central area, followed by permanent lateral tarsorrhaphy. Third step is canthopexy or lateral tarsal strip and canthoplasty according to the horizontal eyelid laxity [29].

The study compared this method to GWI in treatment of paralytic lagophthalmos in leprosy patients and indicated no significant differences between the MT and GWI groups [29].

The elongation of the levator palpebrae superioris muscle is a recognized surgical procedure in ophthalmology. This method focuses on using the patient's own tissues to extend the natural aponeurosis, enhancing both the function and appearance of the eyelid.

Paul Tessier's technique has been studied extensively, and the results have been positive, especially when compared to the outcomes of gold implant procedures [30]. In Tessier's approach, a graft is taken from the temporal aponeurosis. This graft is then carefully placed between the tarsal plate and the lower edge of the levator muscle. The procedure not only lengthens the muscle but also weakens the levator to a controlled extent. In contrast, the gold plate in traditional methods tends to strengthen the levator muscle.

To evaluate the success of this technique, specific criteria were set in the study [30], and patient feedback was collected. Using a standard questionnaire, patients who underwent this surgery reported satisfactory results. On average, they rated their visual comfort at 7 out of 10 and their aesthetic satisfaction at 7.4 out of 10. A follow-up after one year showed that most patients achieved complete eyelid closure, whether they were standing or lying down.

Additionally, Paul Tessier's technique can be combined with external blepharorrhaphy [31] in order to correct palpebrae fissure and to place the lower eyelid under tension.

CONCLUSION

Lagophthalmos, a condition characterized by the inability to fully close the eyelids, presents a significant challenge in clinical management due to its diverse etiologies and associated complications. In the presented case of a 56-year-old female, the condition was a result of an orbital inflammation caused by a *Staphylococcus aureus* infection, further complicated by significant nasal and orbital anatomical changes. Management strategies for lagophthalmos can be broadly categorized into non-surgical and surgical interventions. Non-surgical approaches, such as the use of artificial tears, ointments, and therapeutic contact lenses, primarily aim to maintain ocular surface integrity, prevent corneal abrasions, reduce infection risk, provide symptomatic relief, and support surgical interventions. The use of BTX-A has also emerged as a promising non-surgical alternative, with studies highlighting its efficacy in improving eyelid closure and reducing complications associated with lagophthalmos.

On the other hand, surgical interventions are considered when non-operative modalities prove ineffective. GWI is a commonly adopted surgical procedure, with the primary goal of preventing corneal exposure. However, complications such as extrusion have led to the exploration of alternatives like platinum weight implants. The MT technique offers a simpler and more cost-effective solution, especially beneficial for patients from lower socioeconomic backgrounds. Another surgical approach involves the lengthening of the aponeurosis levator superioris muscle, with Paul Tessier's technique showing positive outcomes in terms of both function and appearance of the eyelid.

The management of lagophthalmos requires a comprehensive and individualized approach, taking into consideration the patient's specific etiology, severity, and associated complications. Both non-surgical and surgical interventions have their merits, and the choice of treatment should be based on the patient's needs, expected outcomes, and potential risks.

Figures: from the authors' own materials.

CORRESPONDENCE

Rafał Woś, MD

Kornel Gibiński University Clinical Centre of Medical
University of Silesia in Katowice
40-514 Katowice, ul. Ceglana 35
e-mail: rafalwos.md@gmail.com

ORCID

Rafał Woś – ID – <https://orcid.org/0009-0001-8628-1688>

Dorota Pojda-Wilczek – ID – <https://orcid.org/0000-0002-7579-2546>

References

1. The definition and classification of dry eye disease: report of the Definition and Classification Subcommittee of the International Dry Eye WorkShop. *Ocul Surf.* 2007; 5: 75-92.
2. Stern ME, Schaumburg CS, Pflugfelder SC. Dry eye as a mucosal autoimmune disease. *Int Rev Immunol.* 2013; 32: 19-41.
3. Stevenson W, Chauhan SK, Dana R. Dry eye disease: an immune-mediated ocular surface disorder. *Arch Ophthalmol.* 2012; 130: 90-100.
4. Li M, Gong L, Chapin WJ, Zhu M. Assessment of vision-related quality of life in dry eye patients. *Invest Ophthalmol Vis Sci.* 2012; 53: 5722-7.
5. Schiffman RM, Walt JG, Jacobsen G et al. Utility assessment among patients with dry eye disease. *Ophthalmology.* 2003; 110(7): 1412-9.
6. Sall K, Stevenson OD, Mundorf TK et al. Two multicenter, randomized studies of the efficacy and safety of cyclosporine ophthalmic emulsion in moderate to severe dry eye disease. CsA Phase 3 Study Group. *Ophthalmology.* 2000; 107: 631-9.
7. Lawrence S, Morris C. Lagophthalmos Evaluation and Treatment. *EyeNet.* 2008.
8. Swiston CJ, Hu KS, Simpson A et al. Prevention of Exposure Keratopathy in the Intensive Care Unit: Evaluation of an EMR-Based Lubrication Order Protocol for Ventilated Patients. *J Acad Ophthalmol (2017).* 2022; 14(2): e141-e146. <http://doi.org/10.1055/s-0042-1750020>.
9. Lai CC, Lin CC. Case Report: Botulinum Toxin-A for Complication of Exposure Keratopathy Following Frontalis-Orbicularis Oculi Muscle Flap Shortening. *Front Med.* 2022; 9: 877162. <http://doi.org/10.3389/fmed.2022.877162>.
10. Nowak-Gospodarowicz I, Różycki R, Rękas M. Quality of Life in Patients with Unresolved Facial Nerve Palsy and Exposure Keratopathy Treated by Upper Eyelid Gold Weight Loading. *Clin Ophthalmol.* 2020; 14: 2211-22. <http://doi.org/10.2147/OPHTH.S254533>.
11. Gerstenblith AT, Rabinowitz MP. The Wills eye manual :office and emergency room diagnosis and treatment of eye disease. 6th ed. Wolters Kluwer/Lippincott Williams & Wilkins, 2012.
12. Shaheen BS, Bakir M, Jain S. Corneal nerves in health and disease. *Surv Ophthalmol.* 2014; 59: 263-85. <http://doi.org/10.1016/j.survophthal.2013.09.002>.
13. Ezra DG, Lewis G, Healy M et al. Preventing exposure keratopathy in the critically ill: A prospective study comparing eye care regimes. *Br J Ophthalmol* 2005; 89: 1068-9.
14. Kasparova EA, Sobkova OI, Kasparova EA et al. Lechebnaia keratoplastika pri gnoïnykh iazvakh rogovitsy, razvivshikhsia na fone neirotroficheskogo keratita i paraliticheskogo lagoftal'ma [Surgical treatment of purulent corneal ulcers in eyes with neurotrophic keratitis and paralytic lagophthalmos]. *Vestn Oftalmol.* 2017; 133(5): 32-37. <http://doi.org/10.17116/oftalma2017133532-37>.
15. Laihia J, Kaarniranta K. Trehalose for Ocular Surface Health. *Biomolecules.* 2020; 10(5): 809. <http://doi.org/10.3390/biom10050809>.
16. Chandler JR, Langenbrunner DJ, Stevens ER. The pathogenesis of orbital complications in acute sinusitis. *Laryngoscope.* 1970; 80: 1414-28.
17. Chaudhry IA, Al-Rashed W, Arat YO. The hot orbit: Orbital cellulitis. *Middle East Afr J Ophthalmol.* 2012; 19: 34-42.
18. Pandian DG, Babu RK, Chaitra A et al. Nine years' review on preseptal and orbital cellulitis and emergence of community-acquired methicillin-resistant *Staphylococcus aureus* in a tertiary hospital in India. *Indian J Ophthalmol.* 2011; 59: 431-5.
19. Israele V, Nelson JD. Periorbital and orbital cellulitis. *Pediatr Infect Dis J.* 1987; 6: 404-10.
20. Şahin MM, Uzunoğlu E, Karamert R et al. The role of gold weight implants in the management of paralytic lagophthalmos. *Turk J Med Sci.* 2021; 51(5): 2584-91. <http://doi.org/10.3906/sag-2104-50>.
21. Sharon JD, Kraus CL, Ehrenburg M et al. Risk Assessment and Prevention of Corneal Complications After Lateral Skull Base Surgery. *Otol Neurotol.* 2016; 37(8): 1148-54. <http://doi.org/10.1097/MAO.0000000000001123>.
22. Matsuo T, Tsuchida Y, Morimoto N. Trehalose eye drops in the treatment of dry eye syndrome. *Ophthalmology.* 2002; 109(11): 2024-9. [http://doi.org/10.1016/s0161-6420\(02\)01219-8](http://doi.org/10.1016/s0161-6420(02)01219-8).
23. Vanaporn M, Titball RW. Trehalose and bacterial virulence. *Virulence.* 2020; 11(1): 1192-202. <http://doi.org/10.1080/21505594.2020.1809326>.
24. Pinto-Bonilla JC, Del Olmo-Jimeno A, Llovet-Osuna F et al. A randomized crossover study comparing trehalose/hyaluronate eye drops and standard treatment: patient satisfaction in the treatment of dry eye syndrome. *Ther Clin Risk Manag.* 2015; 11: 595-603. <http://doi.org/10.2147/TCRM.S77091>.
25. Tint NL, Saxby EPI, Young SL et al. A modified transconjunctival technique for botulinum toxin chemodenervation of levator palpebrae superioris for corneal protection. *Eye (Lond).* 2022; 36(6): 1217-21. <http://doi.org/10.1038/s41433-021-01587-x>.
26. Kirkness CM, Adams GG, Dilly PN et al. Botulinum toxin A-induced protective ptosis in corneal disease. *Ophthalmology.* 1988; 95(4): 473-80. [http://doi.org/10.1016/s0161-6420\(88\)33163-5](http://doi.org/10.1016/s0161-6420(88)33163-5).
27. Berghaus A, Neumann K, Schrom T. The platinum chain: a new upper-lid implant for facial palsy. *Arch Facial Plast Surg.* 2003; 5(2): 166-70. <http://doi.org/10.1001/archfaci.5.2.166>.
28. Vásquez LM, Medel R. Lagophthalmos after facial palsy: current therapeutic options. *Ophthalmic Res.* 2014; 52(4): 165-9. <http://doi.org/10.1159/000365519>.

29. Irawati Y, Natalia MER, Gondhowiardjo TD et al. Modified tarsorrhaphy versus gold weight implant technique for paralytic lagophthalmos treatment in patients with leprosy: One-year observation of a randomized controlled trial study. *Front Med (Lausanne)*. 2023; 9: 941082. <http://doi.org/10.3389/fmed.2022.941082>.
30. Guillou-Jamard MR, Labbé D, Bardot J et al. Paul Tessier's technique in the treatment of paralytic lagophthalmos by lengthening of the levator muscle: evaluation of 29 cases. *Ann Plast Surg*. 2011; 67(6): S31-5. <http://doi.org/10.1097/SAP.0b013e318218360b>.
31. Krastinova-Lolov D. Chirurgie Palliative Des Sequelles De Paralysie Faciale Peripherique. Communication SOC FCPRE, Paris 1989.

Authors' contributions:

All authors have equal contribution to the paper.

Conflict of interest:

None.

Financial support:

None.

Ethics:

The content presented in the article complies with the principles of the Helsinki Declaration, EU directives and harmonized requirements for biomedical journals.