

Is there a relationship between the microbiome of the paranasal sinuses and nasal cavity and the primary acquired nasolacrimal duct obstruction? Literature review

Olga Karłowska-Bijak¹, Magdalena Kokoszka², Maciej Misiółek¹,
Grażyna Stryjewska-Makuch³, Dominik Pawlicki¹

¹ Department of Otorhinolaryngology and Laryngological Oncology in Zabrze, Medical University of Silesia, Katowice
Head: prof. Maciej Misiółek, MD, PhD

² Department of Paediatric Otolaryngology, Head and Neck Surgery, Department of Paediatric Surgery, Upper Silesian Child Health Centre, School of Medicine in Katowice, Medical University of Silesia in Katowice, Katowice
Head: Ireneusz Bielecki, MD, PhD

³ Department of Laryngology and Laryngological Oncology, Leszek Giec Upper-Silesian Medical Centre of the Silesian Medical University, Katowice
Head: Bogdan Kolebacz, MD, PhD



HIGHLIGHTS

The aim of the study was to find the answer whether there is relationship between the microbiome of the lacrimal sac and the paranasal sinuses and their mutual impact on the developing inflammation.

ABSTRACT

Hormonal factors, atopy, viral infections, gastroesophageal reflux, ischemic heart disease and swimming in a pool are believed to affect the development of primary acquired nasolacrimal duct obstruction (PANDO). It is suggested that patients with PANDO have more advanced inflammatory lesions revealed by the tomographic examination of the paranasal sinuses. The authors' aim was to answer the question whether there is a connection between the chronic inflammation and disruption of the microbiome of the nasal cavity and sinuses and the development of inflammation in the lacrimal ducts.

Pubmed.gov was the information source. Years reviewed included 2018 to 2023. Inclusion criteria included presence of an abstract, pathology of the nasolacrimal ducts, acute and chronic inflammation of the nasolacrimal ducts, papers written in English, studies on humans, publications regarding pathology of the lacrimal sac and paranasal sinuses, case report. The exclusion criteria included: lack of abstract, pathologies of other sections of the drainage system, pathology of the nasolacrimal ducts, other than chronic or acute inflammation, papers written in a language other than English, lack of case report. No gender criterion was used.

Based on the data available in the literature, only 7 studies described the co-occurrence of pathologies of the lacrimal ducts and paranasal sinuses. Only 4 publications contained information on the microbiome and identified *Streptococcus intermedius* and *Staphylococcus aureus*, and in 2 cases no increase in pathological flora was revealed.

The question about the relationship between the microbiome of the lacrimal sac and the paranasal sinuses and their mutual impact on the developing inflammation has not been answered, which, according to the authors, requires further research.

Key words: nasolacrimal duct obstruction, lacrimal sac, sinusitis, microbiome

INTRODUCTION

With the development of endoscopic techniques within the nasal cavity and paranasal sinuses, laryngologists are increasingly dealing with the nasolacrimal duct obstruction and lacrimal sac pathology. Primary acquired nasolacrimal duct obstruction (PANDO) is much more common (51.56%) [1] than secondary nasolacrimal duct obstruction (SANDO). The most common causes of secondary obstruction are lacrimal sac tumours, inflammatory diseases, including specific ones, mechanical obstruction, and injuries [2]. Unfortunately, despite many years of observations and research, the causes of primary obstruction have not been unequivocally determined yet [3]. Hormonal factors, atopy, viral infections, disorders of autonomic innervation in the vessels, tear composition disorders, increased concentrations of interleukin (IL) 2, IL-6, fibroblast growth factor 2 and vascular endothelial growth factor are among the suggested causes of PANDO. Others include gastroesophageal reflux, ischemic heart disease, swimming in a pool, using antiglaucoma medications, smoking, eye makeup, as well as changes in the structure and function of the nasal cavity and paranasal sinuses [4].

Based on the nature of the observed histopathological lesions in the nasolacrimal ducts, the course of the disease can be divided into:

1. **Active inflammation:** usually visible in the initial stage of the disease. Periductal tissue is oedematous with subepithelial cell infiltrates of plasma cells and lymphocytes. Hypertrophy of mucous cells is visible.
2. **Intermediate stage:** it is characterized by diffuse inflammation with less lymphocytic infiltration. Segmental areas of fibrosis are visible.
3. **Fibrosis stage:** the lumen of the nasolacrimal duct is obliterated by mature fibrous tissue. There are no epithelial or glandular tissues or inflammatory infiltrates [5].

Chronic fibrosis is probably related to type 2 macrophage activation (M2) in response to IL-4 and IL-13 via the alternative pathway, which leads to the secretion of growth factors by M2 macrophages, which act on fibroblasts, increasing collagen synthesis and consequently leading to tissue fibrosis.

The type of inflammation associated with the above cytokine profile is a common endotype of chronic sinusitis. This may suggest a relationship between the inflammation of the lacrimal duct epithelium and the inflammation in the nasal mucosa. Studies on the relationship between the extent of inflammation in the sinuses and the incidence of primary acquired nasolacrimal duct obstruction showed that patients with PANDO had more advanced lesions in sinus tomography assessed according to the Lund–Mackay scoring system [6].

The authors of the paper wanted to verify whether there is a relationship between the chronic inflammation and disruption of the microbiome of the nasal cavity and sinuses and the development of inflammation in the lacrimal ducts. For this purpose, a literature review was carried out in terms of the causes of the so-called nasolacrimal duct obstruction (obstruction of the lacrimal sac and nasolacrimal duct), with particular emphasis on inflammatory lesions within the lacrimal sac in relation to the lesions in the nasal cavity and paranasal sinuses.

METHODOLOGY

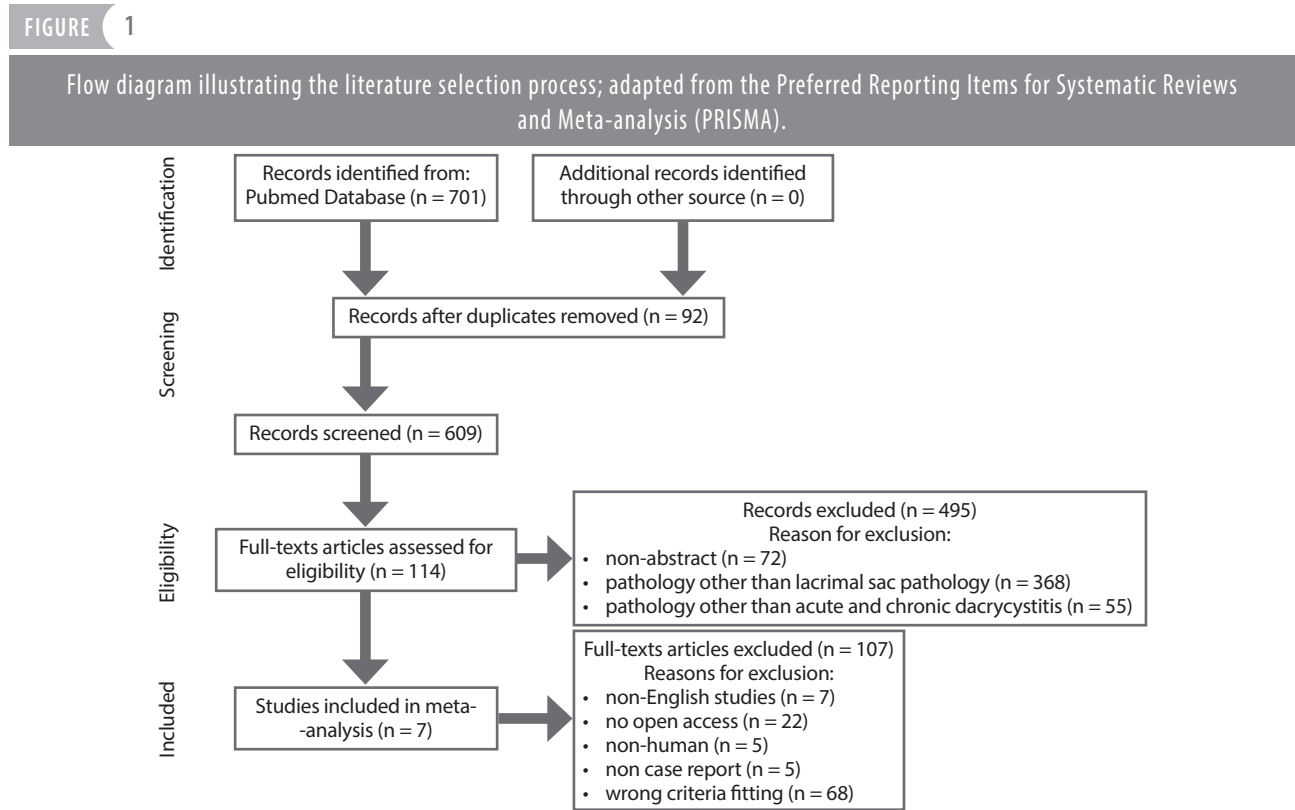
The review was conducted in accordance with the PRISMA 2020 checklist. Two authors (O.K.B and M.K) independently conducted a comprehensive literature review using the electronic database PubMed. The database was searched between June 2023 and September 2023; 3 keywords were used to search for available articles: “lacrimal drainage system pathology”, “lacrimal sac pathology”, “dacryocystitis”. A time criterion was applied in the search, i.e. papers published in the last 5 years. Neither informed consent nor ethics approval was required as this study was a systemic review of published papers. When conducting the literature review, the following inclusion criteria were used: (1) presence of an abstract, (2) pathology of the nasolacrimal ducts, (3) acute and chronic inflammation of the nasolacrimal ducts, (4) papers written in English, (5) studies on humans, (6) publications regarding pathology of the lacrimal sac and paranasal sinuses, (7) case report. The exclusion criteria included: (1) lack of abstract, (2) pathologies of other sections of the drainage system, (3) pathology of the nasolacrimal ducts, other than chronic or acute inflammation, (4) papers written in a language other than English, (5) lack of case report. No gender criterion was used. The results obtained from the 3 keywords mentioned above were exported to EndNote 20. Duplicate articles were automatically removed using the “find duplicates” tool. Two reviewers (M.K., O.K.B.) independently checked all the titles and abstracts. In the case of disagreement, the relevant articles were discussed between the authors until reaching consensus. Full texts were then evaluated. All tests that did not meet the inclusion criteria were excluded. In the event of disagreement as to qualifying the study, the supervising author (G.S-M) made the final decision.

RESULTS

The literature review yielded 701 articles, 92 articles were removed as part of the basic verification process, which consisted in identifying and excluding duplicates from the search. The other 609 articles were subjected to another verification and evaluation process. After reviewing the

titles and abstracts, 495 publications were rejected due to the following reasons: 72 publications did not have an abstract, 368 publications did not concern the lacrimal sac pathology, 55 publications concerned the lacrimal sac pathology other than chronic or acute inflammation. During a full-text review of 114 articles, the relationship between the microbiome of the lacrimal sac and its pathology as well as the relationship between the lacrimal sac pathology and the lesions of the paranasal sinuses were searched for. 22 publications were excluded due to the lack of access, 7 publications were written in a language other than English, 5 publications concerned animals, 68 publications did not concern the subject of the article, 5 did not have a case report. Only 7 publications were related to the authors' topic of interest (fig. 1).

All patients had distal lacrimal duct obstruction, in 4 cases co-occurring with nasal polyps, but in 1 of them the nasal polyps occurred on the side opposite to the lacrimal duct obstruction [7, 10, 11]. In the case of the 37-year-old patient with distal obstruction, in addition to nasal polyps, a pathological mass on the lateral wall of the nose was described, histopathologically identified as an inverted papilloma [7]. In the case of the 66-year-old woman with symptoms of tearing caused by lacrimal apparatus obstruction, which co-occurred with non-specific swelling of the side wall of the nose, an inverted papilloma with squamous cell carcinoma was diagnosed [7]. In 1 case, distal lacrimal duct obstruction coexisted with damage to the lateral nasal wall, histopathologically diagnosed as angular granuloma [7]. Lacrimal sac inflammation



All 7 articles were written in English and published between 2018 and 2022. They described 10 patients, most of whom were males (8 males/2 females). The mean age of the patients was 41.2 years, the oldest was a 66-year-old woman and the youngest was a 15-month-old boy. All patients had comorbid pathology of the lacrimal ducts and paranasal sinuses. 2 subjects had previously undergone paranasal sinus surgery (a 37-year-old man had right external dacryocystorhinostomy, a 36-year-old woman had bilateral maxillary antrostomy) [7, 12]. In the case of 5 articles, there was no data on previous head injuries or surgery within the paranasal sinuses or lacrimal ducts.

was described in 4 cases: a 28-year-old man with nasolacrimal duct obstruction and inflammation of the lacrimal sac with bulging of the side wall of the nose, a 48-year-old patient in whom lacrimal sac inflammation coexisted with inflammation of the paranasal sinuses with polyps, a 36-year-old woman with hypersensitivity to non-steroidal anti-inflammatory drugs, with lesions in all the paranasal sinuses, lacrimal duct obstruction and inflammation of the lacrimal sac [9, 11, 12], a 15-month-old child with an orbital infection with purulent sac inflammation coexisting with inflammation of the paranasal sinuses [13]. Congenital pathology of the lacrimal ducts in the form of dacryocystocele

was diagnosed in a patient with bulging of the side wall of the nose in the area of the nasolacrimal duct and the lacrimal sac, in whom a myxoma from the ethmoid mucosa was identified histopathologically [8].

Only 4 publications contained information on the microbiome. *Streptococcus intermedius* (obtained from intraoperative pus culture) and *Staphylococcus aureus* (obtained from the nasal cavity) were identified. In 2 cases, no growth of pathological flora was observed [10–13]. All patients were

treated surgically, mostly by endoscopic method, and in 5 cases additional conservative treatment in the form of antibiotic therapy was applied [7, 9, 11–13]. When an inverted papilloma with squamous cell carcinoma was diagnosed, radiotherapy was used [7]. In people who were under continuous medical monitoring after treatment, complete or partial regression of symptoms caused by the pathology of the lacrimal ducts and paranasal sinuses was found. The characteristics of the 7 included articles are summarized in table 1.

TABLE 1

Characteristics of included articles.

Papers	Lead author (year)	Number of cases	Sex	Age	History of head trauma	Previous surgery of the nose, paranasal sinuses or lacrimal drainage system	Paranasal sinuses pathology	Lacrimal drainage pathology	Microbiology	Histopathology	Treatment	Follow-up
Epiphora and unrecognized paranasal sinuses pathology	Confalonieri et al. (2020)	4	M	43	No data	No data	Oedema of the lateral nasal wall with nasal polyps	Post-saccular obstruction	No data	No data	FESS – inferior turbinate and the right maxillary sinus	Complete resolution of symptoms
			M	61	No data	No data	Lesion right lateral nasal wall	Post-saccular obstruction	-	Pyogenic granuloma, a benign vascular lesion characterized by inflammatory cells and lobular capillary proliferation	FESS – inferior turbinate removal, create stoma between the lacrimal sac and the nasal cavity	Complete resolution of symptoms
			M	37	-	Right external DCR	Bilateral nasal polyps, purulent rhinorrhea, right lateral nasal wall mass	Post-saccular obstruction	-	Inverted papilloma	Conservative treatment, endoscopic maxillectomy. Resection of the nasolacrimal duct, endonasal DCR	No data
			F	66	No data	No data	Nonspecific oedema of the right lateral nasal wall	Post-saccular obstruction	-	Sinonasal inverted papilloma with synchronous squamous cell carcinoma	Lateral rhinotomy with orbitotomy, adjuvant radiotherapy	No data

Endoscopic resection of a huge orbital ethmoidal mucocele masquerading as dacryocystocele	Wong et al. (2018)	1	M	57	-	-	Bulge of the lateral nasal wall within the middle meatus over the area of the lacrimal sac and nasolacrimal duct	Dacryocystocele	-	Mucocele arising from ethmoidal mucosa	Endoscopic marsupialisation of the lacrimal sac	Complete resolution of symptoms
Agger nasi mucocele cause nasolacrimal duct obstruction and chronic dacryocystitis: clinical profile, management and outcome	Saratziotis et al. (2021)	1	M	28	-	-	Bulging of the lateral nasal wall at the left-sided agger nasi area	NLDO, dacryocystitis	No data	No data	En-DCR, left anterior ethmoidectomy and sphenoidectomy; Temporary silicone stenting conservative treatment	Improvement of symptoms
Dacryocystitis and rhinosinusitis secondary to sarcoidosis	Ishikawa et al. (2018)	1	M	35	No data	No data	Thickened nasal mucosa on both sides, polyps on the right side	Complete nasolacrimal duct obstruction on the left side	Lacrimal sac wall – noncasing epithelioid granulomas in the subepithelial layer. The nasal polyps similar pathological	No positive staining acid-fast bacteria or fungi	En-DCR on the left side; ESS on the right side	Complete resolution of symptoms
Orbital abscess developed apart from paranasal sinusitis and dacryocystitis in fibrous dysplasia	Kakizaki et al. (2022)	1	M	48	-	-	Maxillary and ethmoidal sinusitis. Polyps in the middle nasal meatus	Dacryocystitis; partial defect of the lacrimal sac fossa	-	<i>Streptococcus intermedius</i>	DCR, ESS, conservative treatment	Complete resolution of symptoms
Dacryocystitis in a patient with Samter's triad	Abdel-Aty et al. (2022)	1	F	36	-	Bilateral maxillary antrotomy	Pan-sinus disease	Periorbital edema, erythema with tenderness over the lacrimal sac	-	Pus demonstrated no growth	Surgical drainage of the lacrimal sac abscess. Bilateral maxillary antrotomy, nasal polypectomy, right DCR with the Crawford stents. Conservative treatment	Improvement of symptoms

Bilateral puffy orbits in a toddler: therapeutic challenges	Rajaram-Jeswari et al. (2021)	1	M	15 month	No data	No data	Left sided mucoid nasal discharge and congestion, left ethmoiditis	Oedema of left upper and lower eyelids. Lacrimal sac bulging with purulent discharge	No data	No data	Left endoscopic ethmoidectomy, En-DCR. Conservative treatment	No data
---	-------------------------------	---	---	----------	---------	---------	--	--	---------	---------	---	---------

DCR – dacryocystorhinostomies; En-DCR – endonasal dacryocystorhinostomies; ESS – endoscopic sinus surgery; FESS functional endoscopic sinus surgery; NLDO – nasolacrimal duct obstruction.

DISCUSSION

The immediate vicinity of the lacrimal ducts and paranasal sinuses raises the question whether there is a relationship between the pathology of these systems. The nasolacrimal duct, which drains the secretion from the lacrimal sac, opens into the inferior nasal meatus, connecting the nasal cavity with the eye socket. Chronic inflammatory lesions resulting from the mucous membrane microbiome disturbances or anatomical deformations in the nasal cavity and paranasal sinuses are a potential cause of disturbances to the patency of the nasolacrimal ducts.

The authors of the study reviewed the literature with the aim of finding descriptions of patients in whom obstruction of the nasolacrimal ducts was associated with pathological lesions in the paranasal sinuses, with particular emphasis on microbiome disturbances. Based on the data from the literature, it was found that the most common pathogens causing acute inflammation of the lacrimal sac were *Staphylococcus aureus* (*S. aureus*), *S. epidermidis* and *S. pneumoniae* [14, 15], whereas in the case of chronic inflammation, it was *S. epidermidis*, *Pseudomonas spp.*, *S. aureus* or *Candida albicans* [16]. Chronic sinusitis is most often caused by *Staphylococcus aureus*, *Haemophilus influenzae* and *Streptococcus pneumoniae* [17]. According to Soriano, chronic inflammation of the paranasal sinuses and nose may result in more frequent episodes of chronic lacrimal sac inflammation, especially of a purulent nature [18].

However, in the reviewed literature there was no information indicating whether the lacrimal sac microbiome was similar to the microbiome of the paranasal sinuses.

Some researchers paid particular attention to the influence of anatomical disorders in the nasal cavity on the nasolacrimal duct pathology. Anand drew attention to the nasal septal deviation as a pathology that statistically significantly co-occurred with the lacrimal sac inflammation, without analysing the relationship with the inflammation of the paranasal sinuses [19]. Samarei, on the other hand, pointed out the nasal septal deviation is a factor that may be important in the case of PANDO, at the same time indicating agger nasi cell and maxillary sinusitis as pathologies co-occurring with PANDO compared to the control group [20]. However, it was not proven that these lesions occurred more often on the same side as the lacrimal duct pathology.

CONCLUSION

Based on the data available in the literature, it was not possible to unequivocally answer the question whether there is a relationship between chronic inflammation and microbiome disturbance in the nasal cavity and sinuses and the development of inflammation in the nasolacrimal ducts. This issue requires further research. However, it is worth keeping in mind the possibility of pathology of these 2 systems occurring simultaneously during the treatment and diagnosis of patients in everyday medical practice.

CORRESPONDENCE

Olga Karłowska-Bijak, MD

Department of Otorhinolaryngology and Laryngological Oncology in Zabrze
41-800 Zabrze, ul. Marii Skłodowskiej-Curie 10
e-mail: olgakarlowska@gmail.com

ORCID

Olga Karłowska-Bijak – ID – <https://orcid.org/0000-0002-6899-764X>
Magdalena Kokoszka – ID – <https://orcid.org/0000-0001-8091-2840>
Maciej Misiólek – ID – <https://orcid.org/0000-0002-8476-9153>
Grażyna Stryjewska-Makuch – ID – <https://orcid.org/0000-0001-7967-6887>
Dominik Pawlicki – ID – <https://orcid.org/0009-0007-3869-6225>

References

1. Das AV, Rath S, Naik MN et al. The Incidence of Lacrimal Drainage Disorders Across a Tertiary Eye Care Network: Customization of an Indigenously Developed Electronic Medical Record System-eyeSmart. *Ophthalmic Plast Reconstr Surg.* 2019; 35(4): 354-6.

2. Bartley GB. Acquired lacrimal drainage obstruction: an etiologic classification system, case reports, and a review of the literature. Part 1. *Ophthal Plast Reconstr Surg.* 1992; 8: 237-42.
3. Paulsen FP, Thale AB, Maune S et al. New insights into the pathophysiology of primary acquired dacryostenosis. *Ophthalmology.* 2001; 108(12): 2329-36.
4. Ali MJ, Paulsen F. Etiopathogenesis of Primary Acquired Nasolacrimal Duct Obstruction: What We Know and What We Need to Know. *Ophthalmic Plast Reconstr Surg.* 2019; 35: 42633.
5. Linberg JV, McCormick SA. Primary acquired nasolacrimal duct obstruction. A clinicopathologic report and biopsy technique. *Ophthalmology.* 1986; 93: 1055-63.
6. Yartsev VD, Atkova EL, Rozmanov EO et al. Rhinological Status of Patients with Nasolacrimal Duct Obstruction. *Int Arch Otorhinolaryngol.* 2021; 26(3): e434-9.
7. Confalonieri F, Balia L, Piscopo R et al. Epiphora and unrecognized paranasal sinuses pathology. *Am J Ophthalmol Case Rep.* 2020; 19: 100798.
8. Wong E, Leith N, Wilcsek G et al. Endoscopic resection of a huge orbital ethmoidal mucocele masquerading as dacryocystocele. *BMJ Case Rep.* 2018; 2018: bcr2018226232.
9. Saratziotis A, Zanotti C, Hajjioannou J et al. Agger nasi mucocele cause nasolacrimal duct obstruction and chronic dacryocystitis: clinical profile, management and outcome. *BMJ Case Rep.* 2021; 14(5): e242140.
10. Ishikawa E, Takahashi Y, Nishimura K et al. Dacryocystitis and Rhinosinusitis Secondary to Sarcoidosis. *J Craniofac Surg.* 2019; 30(1): e52-4.
11. Takahashi Y, Kono S, Yokoyama T et al. Orbital Abscess Developed Apart From Paranasal Sinusitis and Dacryocystitis in Fibrous Dysplasia. *Cureus.* 2022; 14(6): e26061.
12. Abdel-Aty A, Jin A, Manes RP et al. Dacryocystitis in a patient with Samter's triad. *Oman J Ophthalmol.* 2022; 15(2): 225-7.
13. Rajarajeswari N, Kurien M, Kumar S et al. Bilateral Puffy Orbits in a toddler: Therapeutic Challenges. *Indian J Otolaryngol Head Neck Surg.* 2022; 74(Suppl 3): 4549-51.
14. Kally PM, Omari A, Schlachter DM et al. Microbial profile of lacrimal system Dacryoliths in American Midwest patient population. *Taiwan J Ophthalmol.* 2022; 12(3): 330-3.
15. Singh S, James C, Curragh DS et al. Lacrimal gland choristoma in lacrimal sac as a probable cause of nasolacrimal duct obstruction. *Clin Exp Ophthalmol.* 2019; 47(5): 675-7.
16. Eslami F, Ghasemi Basir HR, Moradi A et al. Microbiological study of dacryocystitis in northwest of Iran. *Clin Ophthalmol.* 2018; 12: 1859-64.
17. Kim HJ, Lee K, Yoo JB et al. Bacteriological findings and antimicrobial susceptibility in chronic sinusitis with nasal polyp. *Acta Otolaryngol.* 2006; 126(5): 489-97.
18. Soriano LM, Damasceno NA, Herzog Neto G et al. Comparative study of the clinical profile of chronic dacryocystitis and chronic rhinosinusitis after external dacryocystorhinostomy. *Clin Ophthalmol.* 2019; 13: 1267-71.
19. Anand Chavadaki J, Raghu K, Patel VI. A Retrospective Study of Establishment of Association Between Deviated Nasal Septum, Sinusitis and Chronic Dacryocystitis. *Indian J Otolaryngol Head Neck Surg.* 2020; 72(1): 70-3.
20. Samarei R, Samarei V, Aidenloo NS et al. Sinonasal Anatomical Variations and Primary Acquired Nasolacrimal Duct Obstruction: A Single Centre, Case-Control Investigation. *Eurasian J Med.* 2020; 52(1): 21-4.

Authors' contributions:

Olga Karłowska-Bijak: the idea for the article, performed the literature search and data analysis.

Magdalena Kokoszka: performed the literature search and data analysis.

Maciej Misiółek: drafted and critically revised the work.

Grażyna Stryjewska-Makuch: drafted and critically revised the work.

Dominik Pawlicki: performed the literature search and data analysis.

All authors contributed to the paper and have read and agreed to the published version of manuscript.

Conflict of interest:

None.

Financial support:

None.

Ethics:

The content presented in the article complies with the principles of the Helsinki Declaration, EU directives and harmonized requirements for biomedical journals.