

Malignant glaucoma: disease course and treatment



**Natalie Papachristoforou¹, Ismael Alsoubie¹, Anthony Ueno¹,
Aneta Pyza¹, Julia Kaczmarek¹, Natalia Wolińska¹, Jakub Piórek¹,
Katarzyna Sajak-Hydzik^{1,2}, Ilona Pawlicka^{1,2}, Agnieszka Piskorz^{1,2},
Maciej Kozak^{1,2}, Anna Maria Roszkowska^{1,3}**

¹ Faculty of Medicine and Health Sciences, Collegium Medicum, Andrzej Frycz Modrzewski Academy in Krakow.
Dean: Prof. KAAFM Janusz Ligęza, PhD

² Clinical Ophthalmology Department, Section „A”, Provincial Ophthalmological Hospital in Krakow
Head: Maciej Kozak, MD, PhD

³ Department of Biomedical and Dental Sciences and Morphofunctional Imaging, University of Messina, Italy
Head: prof. Sergio Baldari

HIGHLIGHTS

The defining characteristics of malignant glaucoma is the occurrence of an increased and uncontrolled intraocular pressure, as a consequence of prior intraocular surgeries.

If left untreated or treated inadequately, it can lead to vision loss.

ABSTRACT

Diagnosis of malignant glaucoma presents a challenge due to subtle symptoms in early stages of the disease, making increased intraocular pressure a pivotal indicator, often accompanied by inflammation and corneal edema. Diagnostic modalities, including ultrasound biomicroscopy and anterior segment optical coherence tomography, play crucial roles in visualizing anatomical changes in the ciliary body and anterior chamber. The classic slit lamp examination, complemented by tonometry, remains a fundamental diagnostic tool. A stepwise therapeutic approach is essential, beginning with pharmacological interventions aimed at intraocular pressure reduction and subsequent restoration of the anterior chamber configuration. The first stage of treatment is pharmacotherapy. Laser therapies, such as iridotomy and Nd:YAG laser treatment, address angle closure. In resistant cases, a surgical approach, such as irido-zonulo-hyaloidotomy may be considered.

Key words: glaucoma, malignant glaucoma, intraocular pressure, aqueous misdirection syndrome, irido-zonulo-hyaloidotomy, irido-zonulo-hyaloido-vitrectomy

INTRODUCTION

In the 19th century, Albrecht von Gräfe, a German ophthalmology specialist, attempted to define the disease known as malignant glaucoma [1]. Despite years of observation this rare disease, still evokes curiosity in the field of ophthalmology. In this disorder, an elevated intraocular pressure (IOP), and shallow anterior eye chamber can be observed. Patients who underwent intraocular surgeries are at particular risk of the aforementioned disease. Malignant glaucoma leads to vision loss. An unequivocal etiopathogenesis is very difficult to establish, thus it is considered a multifactorial disease [2].

GLAUCOMA

Glaucoma is a term used to describe a group of diseases, characterized by progressive neuropathy of the optic nerve. Ganglion cells undergo fibrosis, leading to changes within the optic nerve head [3].

The main risk factor of the disease occurrence is an excessively elevated IOP, which damages the ganglionic cells. The accepted norm for IOP is between 10 mmHg and 21 mmHg. There are various risk factors for the disease, such as: older age, Afro-American ethnicity, positive family history, diabetes, myopia, hormonal contraception, cardiovascular diseases [4].

Many types of glaucoma are distinguished, defined by the causes and the progression of glaucoma neuropathy [5]. Furthermore, there is an additional subdivision, which takes into account the angle of filtration, as well as the absence or presence of factors predisposing to increased IOP and the time of disease onset [6].

MALIGNANT GLAUCOMA

Malignant glaucoma, also known as the aqueous misdirection syndrome, is a relatively rare disease, that most commonly develops a few days after surgery and as a complication of intraocular procedures [7]. It is a disease that most commonly affects patients already suffering from closed or narrow-angle glaucoma. It is noteworthy, that a significant majority of patients with post-operative malignant glaucoma are white people with primary closed angle-glaucoma [8].

The most characteristic feature is the elevation of IOP and shallowing of the anterior chamber, caused by an accumulation of aqueous humor behind the ciliary body, the posterior lens capsule, and anterior boundary of the vitreous humor. This pathomechanism leads to the blockage of spontaneous aqueous humor flow into the anterior chamber, resulting in the relocation of the lens-iris or iris-vitreous diaphragm forward, as well as the closure of the filtration angle [9, 10].

Hypotheses have been formulated that attempt to explain the unequivocal causes of malignant glaucoma. Factors such as aqueous misdirection syndrome or direct angle closure have been considered [11]. Procedures associated with high risk of developing malignant glaucoma include trabeculotomy and other invasive anti-glaucoma treatments. Surgeries viewed as routine, such as cataract surgery, or more sophisticated like vitrectomy, corneal transplant contribute to the occurrence of the discussed disease. All procedures involving the shallowing of the anterior chamber pose high risk [2].

Malignant glaucoma is a disease that may pose a challenge for the physician, since its symptoms are not straightforward, especially in the initial phases of the disease. In the absence of an increased IOP, the diagnosis may be difficult to establish. Initially there may be an improvement in near vision, resulting from a shift in refraction due to the forward displacement of the lens and iris. As a consequence of high IOP, exceeding 21 mmHg, patients experience eye pain, while physical examination reveals inflammation and a developing corneal edema [8].

The most common symptoms include redness of the eye and significant deterioration of vision, which become noticeable after some time from the onset of the disease (following initial myopization with an improvement of near vision). Depending on the IOP values, patients may experience nausea and vomiting [9].

DIAGNOSTICS

The most efficient examination used to diagnose malignant glaucoma is a biomicroscopic ultrasound (UBM) (fig. 1). This method allows imaging of the anterior rotation taking place in the ciliary body along with the shift of the lens-iris diaphragm, which is responsible for the lens relocation and closure of the drainage angle [12].

A new method used in the diagnosis of malignant glaucoma is the anterior segment optical coherence tomography (AS-OCT). With the OCT apparatus, it is possible to assess the anterior eye chamber. It is a similar diagnostic tool to UBM, yet it does not provide high resolution and visibility of individual pathological changes occurring behind the iris [[13] (fig. 2)].

The most commonly used diagnostic method in the initial diagnosis of malignant glaucoma is the slit lamp examination. In this examination, a noticeable shallowing of the central and peripheral anterior chamber of the eye is observed. The examination should be complemented by tonometry [14].

TREATMENT

Treatment objectives should primarily focus on the initial reduction of IOP, followed by the restoration of the anterior

FIGURE 1

Slit-lamp examination and ultrasound biomicroscopy (UBM) before (A–B) and after (C–D) anterior vitrectomy in a patient with malignant glauoma [15].

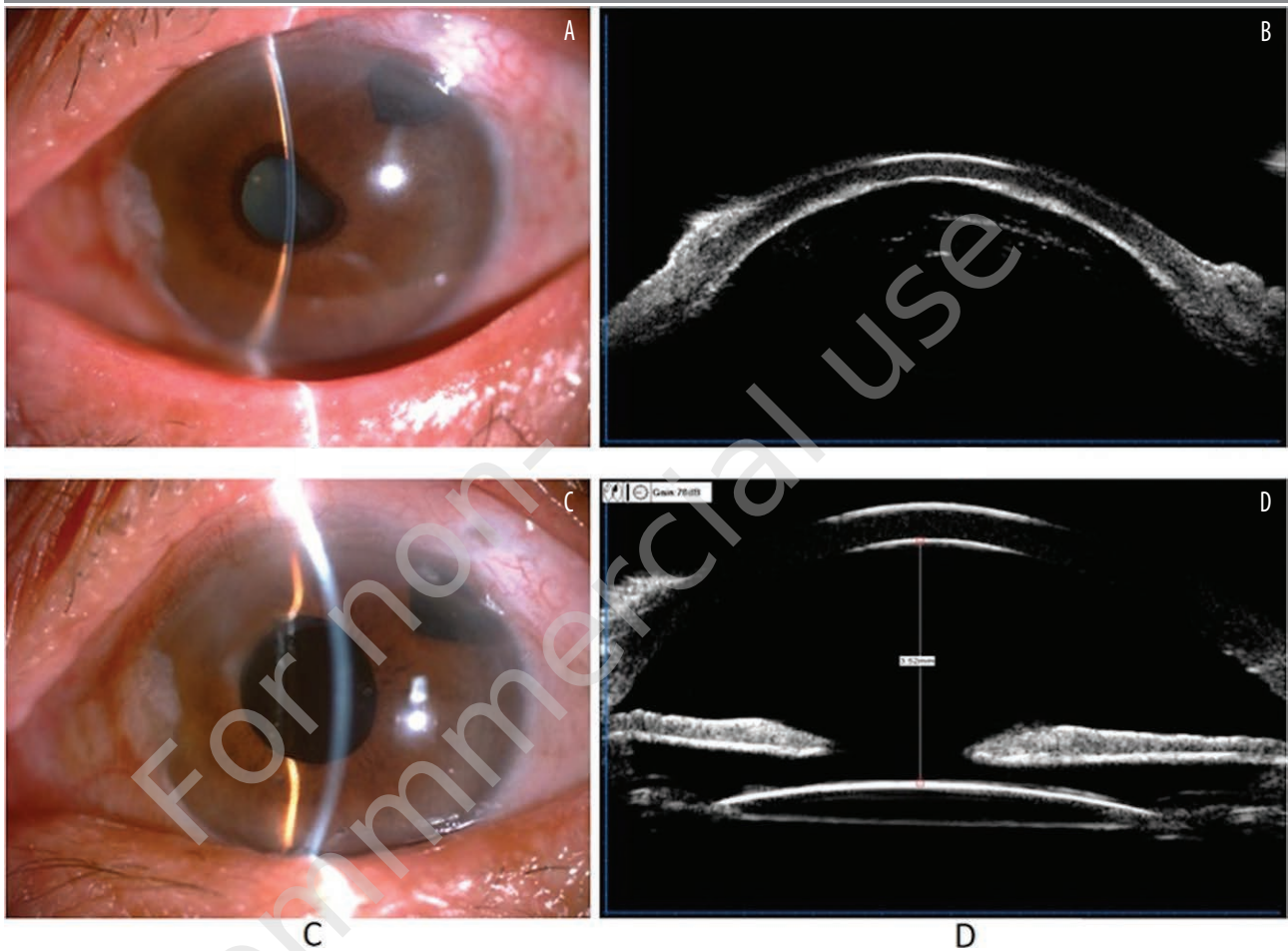
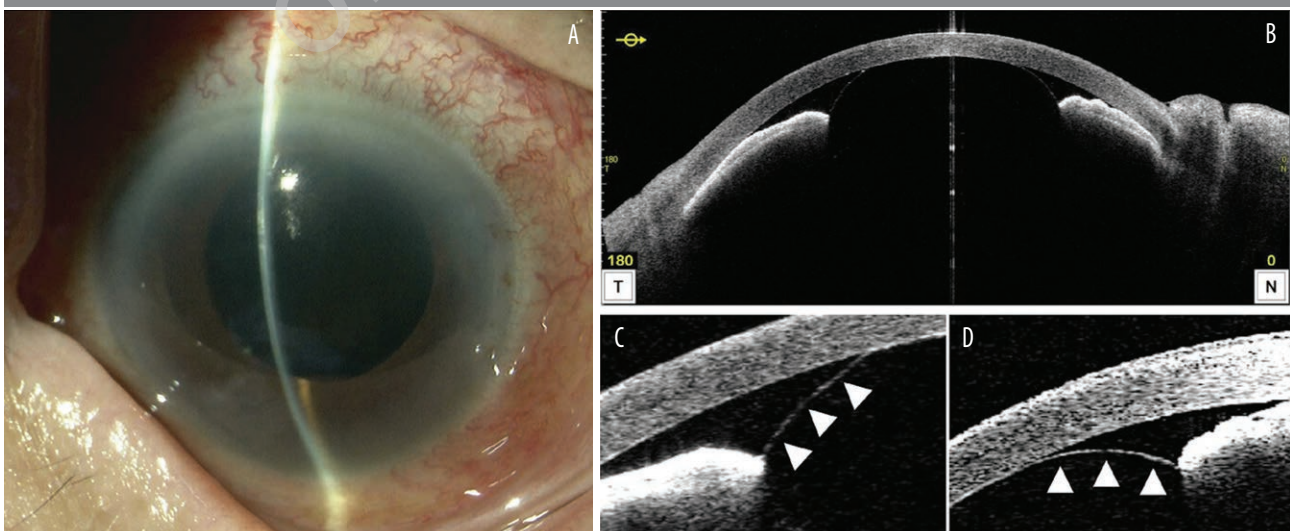


FIGURE 2

Slit-lamp (A) and AS-OCT (B–D) examination of the right eye (OD) 10 days after total cataract extraction. A shallow anterior chamber and closed angle are seen despite the absence of the lens and lens capsule (A, B) [16].



eye chamber's configuration. This aims to reestablish the flow of aqueous humor from the posterior to the anterior chamber of the eye [2].

The therapeutic approach begins with pharmacological interventions and, if unsuccessful, progresses to a step-wise inclusion of laser and surgical treatments [2, 8, 10]. Pharmacological treatment is designed to achieve rapid pressure control to prevent optic nerve damage. Typically this intervention is administered 3–5 days prior to surgical interventions [3, 9, 14]. Pharmacological intervention demonstrates efficacy within the initial 5 days of treatment initiation, yielding positive outcomes in 50% of cases [13]. This finding aligns with the early work of Simmons who reported that 50% of patients respond sufficiently to pharmacological treatment alone [17].

Pharmacological intervention involves topical or systemic administration of β -blockers, carbonic anhydrase inhibitors (e.g., acetazolamide), and α -agonists to reduce the production of aqueous humor. Cycloplegic drugs such as atropine or phenylephrine deepen the anterior chamber and shift the lenticular-iris diaphragm posteriorly, thereby facilitating the passage of aqueous humor [2, 8, 10, 13]. Steroids can be employed to reduce inflammation, while osmotic agents (e.g., mannitol, glycerol) remove fluid from vitreous body [2, 8].

If further intervention becomes imperative, the subsequent therapeutic measure involves laser therapy. Iridotomy or argon laser peripheral iridoplasty, both serve to open the anterior chamber angle [3, 18].

The use of an Nd:YAG laser facilitates capsulotomy with hyaloidotomy and iridotomy in aphakic or pseudophakic eyes. In cases where iridotomy has previously been performed, the procedure may proceed without it. This laser treatment established flow from the posterior eye chamber to the anterior by destruction of the anterior surface of the vitreous body. However, this technique is not advised in phakic eyes due to the high risk of lens damage [2]. Nd:YAG laser treatment proves efficiency in maintaining the patency of aqueous humor flow subsequent to surgical interventions to prevent or treat recurrences of malignant glaucoma [7, 13].

One of the initial intraoperative procedures performed when malignant glaucoma features become apparent is aqueous humor aspiration (Chandler's procedure). However, this procedure alone fails to establish adequate communication between the posterior and anterior segments of the eye, consequently leaving the issue of fluid accumulation in the vitreous body unresolved [2]. Additional measures are required to establish a patent communication between the posterior and anterior chamber of the eye.

Vitrectomy in the absence of other techniques does not yield high success rates for both phakic and aphakic/pseudophakic eyes. However, the combination of pars plana vit-

rectomy (PPV) with iridectomy, capsulectomy and zonullectomy significantly enhances success rates. For phakic eyes, simultaneous lensectomy is recommended to achieve higher success rates [2]. An optimized treatment approach involves combining PPV with phacoemulsification, coupled with zonulo-hyaloidectomy-iridectomy, to achieve optimal results [14]. Partial PPV with peripheral lens capsule excision has been reported as an efficient treatment strategy, although it often requires local antiglaucoma treatment for successful long-term pressure control [3].

Patients who have previously manifested malignant glaucoma subsequent to cataract surgery are at increased risk to develop this condition in the contralateral eye. Consequently, some authors recommend iridotomy/iridectomy or preventive anterior vitrectomy concurrent with planned phacoemulsification for individuals scheduled for cataract surgery [2, 3, 8, 9].

Pharmacological treatment can be tapered gradually upon normalization of IOP post-surgery, but some patients may require indefinite pharmacological treatment or depending on the previously performed measures additional surgical intervention [13].

Irido-zonulo-hyaloidotomy

Irido-zonulo-hyaloido-vitrectomy represents an alternative therapeutic approach for refractory malignant glaucoma cases, characterized by uncontrolled IOP despite conventional interventions such as pharmacotherapy, laser treatment, and the Chandler procedure – a technique involving vitreous aspiration by a needle [19, 20]. In instances of recurrent elevated IOP, the establishment of communication between the posterior and anterior segments of the eye has proven unsuccessful, necessitating the restoration of continuous communication [21].

To reform the anterior chamber of the eye, a procedure of paracentesis is conducted, and subsequently a viscoelastic agent is applied. Subsequently, side ports are inserted, and a core vitrectomy is performed. Iridectomies using a vitreous cutter are carried out through the anterior approach. Subsequently, hyaloidotomy, zonullectomy, and posterior capsulotomy are performed using a vitreous cutter through the pars plana approach, all under direct visualization through the patent iridectomies. A comprehensive vitrectomy of the vitreous base concludes the surgery, deepening the anterior chamber [20].

While relapse rates for medical therapy, laser therapies, or vitrectomy alone range between 66% and 100%, the combination of iridectomy, capsulectomy, and zonullectomy with pars plana vitrectomy has demonstrated a significantly improved success rate [22]. There are detailed descriptions regarding the application of irido-zonulo-hyaloido-vitrectomy in pseudophakic eyes [20, 21], while others recommend its combination with phacoemulsification [22].

Currently, there is limited published literature on this subject, and further studies are imperative to establish comprehensive guidelines for the management of refractory malignant glaucoma. Nevertheless, irido-zonulo-hyaloido-vitrectomy has proven to be a highly effective treatment method in a subset of cases, demonstrating considerable potential for future applications of this technique.

CONCLUSION

Malignant glaucoma constitutes an ophthalmological emergency, presenting a high risk for irreversible loss of vision if not promptly and adequately treated. This disease is influ-

enced by various risk factors but most commonly manifests in individuals already afflicted by glaucoma and emerges after procedures such as penetrating antiglaucoma interventions and other intraocular procedures. The primary therapeutic objective is pharmacological reduction of IOP to prevent ocular nerve damage through the administration of topical and systemic medications. Subsequently, laser and eventually surgical interventions target resolving the cause for the aqueous humor blockage. Some authors advocate for preventive treatment in patients at high risk to develop malignant glaucoma. In persistently relapsing cases irido-zonulo-hyaloido-vitrectomy gives good results to restore the patency of communication between the posterior and anterior eye chamber.

CORRESPONDENCE

med student Natalie Papachristoforou

Faculty of Medicine and Health Sciences,
Collegium Medicum, Andrzej Frycz Modrzewski Academy
in Krakow
30-705 Kraków, ul. Gustawa Herlinga-Grudzińskiego 1
e-mail: natalienicole120@gmail.com

ORCID

Natalie Papachristoforou – ID – <http://orcid.org/0009-0006-8417-3794>
Ismael Alsoubie – ID – <http://orcid.org/0000-0002-0974-3025>
Aneta Pyza – ID – <http://orcid.org/0009-0000-5318-1368>
Julia Kaczmarek – ID – <http://orcid.org/0009-0001-2268-6547>
Jakub Piórek – ID – <http://orcid.org/0009-0001-4744-1933>
Natalia Wolińska – ID – <http://orcid.org/0000-0003-0975-9163>
Anthony Ueno – ID – <http://orcid.org/0009-0008-6946-4096>
Maciej Kozak – ID – <http://orcid.org/0000-0001-7993-2588>
Ilona Pawlicka – ID – <http://orcid.org/0000-0003-1556-7678>
Katarzyna Sajak-Hydzik – ID – <http://orcid.org/0000-0002-1973-2717>
Agnieszka Piskorz – ID – <http://orcid.org/0000-0003-4553-0497>
Anna Maria Roszkowska – ID – <http://orcid.org/0000-0002-8083-3437>

References

1. von Graefe A. Beiträge zur Pathologie und Therapie des Glaucoms. *Archiv für Ophthalmologie*. 1869; 15: 108-252.
2. Pożarowska D. Malignant Glaucoma: new views on its etiopathogenesis and management, *OpthaTherapy*. 2019; 6(3): 160-7.
3. Weinreb RN, Aung T, Medeiros FA. The pathophysiology and treatment of glaucoma: a review. *JAMA*. 2014; 311(18): 1901-11. <http://doi.org/10.1001/jama.2014.3192>.
4. Niżankowska H. *Okulistyka. Podstawy kliniczne*. PZWL, Warszawa 2007.
5. Szczeklik A. *Interna Szczeklika*. Medycyna Praktyczna, 2023.
6. Gupta D, Chen PP. Glaucoma. *Am Fam Physician*. 2016; 93(8): 668-74.
7. Rękas M, Krix-Jachym K, Żarnowski T. Evaluation of the Effectiveness of Surgical Treatment of Malignant Glaucoma in Pseudophakic Eyes through Partial PPV with Establishment of Communication between the Anterior Chamber and the Vitreous Cavity. *J Ophthalmol*. 2015; 2015: 873124. <http://doi.org/10.1155/2015/873124>.
8. Shahid H, Salmon JF. Malignant glaucoma: a review of the modern literature. *J Ophthalmol*. 2012; 2012: 852659. <http://doi.org/10.1155/2012/852659>.
9. Foreman-Larkin J, Netland PA, Salim S. Clinical Management of Malignant Glaucoma. *J Ophthalmol*. 2015; 2015: 283707. <http://doi.org/10.1155/2015/283707>.
10. Kahook Y, Noecker RJ. How do you diagnose and treat malignant glaucoma, *Glaucoma Today*. 2006; November/December: 40-42.
11. Krix-Jachym K, Żarnowski T, Rękas M. Risk Factors of Malignant Glaucoma Occurrence after Glaucoma Surgery. *J Ophthalmol*. 2017; 2017: 9616738. <http://doi.org/10.1155/2017/9616738>.

12. Park M, Unigame K, Kiryu J et al. Management of a patient with pseudophakic malignant glaucoma; role of ultrasound biomicroscopy. *Br J Ophthalmol*. 1996; 80(7): 676-7. <http://doi.org/10.1136/bjo.80.7.676>.
13. Dorairaj S, Chan I, Teng CC. Diagnosis and Management of Malignant Glaucoma. *EyeNet Magazine*. 2010; April.
14. Fekih O, Zgolli HM, Mabrouk S et al. Malignant glaucoma management: literature review. *Tunis Med*. 2019; 97(8-9): 945-9.
15. Liu X, Hu Y, Yang T et al. Impact of improved minimally invasive anterior vitrectomy on the prognosis of patients with malignant glaucoma. *BMC Ophthalmology*. 2024; 24(1). <https://doi.org/10.1186/s12886-024-03310-2>.
16. Kono M, Ishida A, Ichioka, S et al. APHAKIC pupillary block by an intact anterior vitreous membrane after total lens extraction by phacoemulsification. *Case Reports in Ophthalmology*. 2021; 12(3): 882-8. <https://doi.org/10.1159/000520176>.
17. Simmons RJ. Malignant glaucoma. *Br J Ophthalmol*. 1972; 56(3): 263-72. <http://doi.org/10.1136/bjo.56.3.263>.
18. Wright C, Tawfik MA, Waisbourd M et al. Primary angle-closure glaucoma: an update. *Acta Ophthalmol*. 2016; 94(3): 217-25. <http://doi.org/10.1111/aos.12784>.
19. Ruben ST, Tsai J, Hitchings RA. Malignant glaucoma and its management. *Brit J Ophthalmol*. 1997; 81: 163-7.
20. Chew RP, Irwan Chong A, Zamli AH et al. Successful Management of Malignant Glaucoma With Irido-Zonulo-Hyaloidotomy and Complete Pars Plana Vitrectomy. *Cureus*. 2022; 14(1): e21679. <http://doi.org/10.7759/cureus.21679>.
21. Tosi R, Kilian R, Rizzo C et al. A case of bilateral pseudophakic malignant glaucoma treated with a new variant of irido-zonulo-hyaloid-vitrectomy. *Am J Ophthalmol Case Rep*. 2022; 28: 101719. <http://doi.org/10.1016/j.ajoc.2022.101719>.
22. Debrouwere V, Stalmans P, Van Calster J et al. Outcomes of different management options for malignant glaucoma: a retrospective study. *Graefes Arch Clin Exp Ophthalmol*. 2012; 250(1): 131-41. <http://doi.org/10.1007/s00417-011-1763-0>.

Authors' contributions:

All authors have equal contribution to the paper.

Conflict of interest:

None.

Financial support:

None.

Ethics:

The content presented in the article complies with the principles of the Helsinki Declaration, EU directives and harmonized requirements for biomedical journals.