

Management strategies in benign eyelid lesions



**Anna Jagielak-Grab, Dominika Białas, Paulina Szabelska,
Radosław Różycki**

Department of Ophthalmology, Military Institute of Aviation Medicine, Warsaw
Head: Radosław Różycki, MD, PhD

HIGHLIGHTS

Sometimes it is difficult to differentiate benign tumors from malignant and pre-malignant lesions. In those cases, a biopsy has to be taken into consideration before treatment. Nowadays, there are various treatment modalities available for management of benign skin lesions.

ABSTRACT

Eyelid tumors are a common discovery during an ophthalmological or dermatological examination. According to available knowledge, they constitute about 5–10% of skin tumors. The majority of them are benign and can be classified as inflammatory, infectious, traumatic or neoplastic lesions. Depending on the lesion type, there are different approaches to management that include: observation, topical application of steroids or antibiotics, injection of steroids, application of warm compresses, biopsy, excision, curettage, various types of laser therapy or plasma-based therapies, cryosurgery and electrocautery. Malignant eyelid tumors are not rare, therefore, an accurate diagnosis is crucial to provide best suited type of treatment. In many cases, an experienced physician is able to distinguish a benign lesion basing on clinical examination, however, it is often difficult to differentiate benign tumors from malignant and premalignant lesions. In case of any uncertainty, a biopsy followed by histopathological examination should always be taken into consideration.

Key words: eyelid tumor, skin lesions, cryosurgery, squamous papilloma, laser therapy

INTRODUCTION

The eyelids consist of skin with adnexa, muscles, fibrous tissue and mucous membrane – palpebral conjunctiva [1]. Their adequate position and movement play a major role in the proper eye function due to the responsibility for producing and distributing the tear film over the eye surface in order to moisturize it. Moreover, they protect the eyeball from external factors and regulate the quantity of the light that enters the eye [1, 2].

Though eyelid lesions can originate from each of their tissues, most commonly, they derive from epidermis, dermis and adnexa of the skin, such as Meibomian, Zeiss or Moll glands [3]. High incidence of skin lesions in the palpebral area can be connected to excessive exposure to sunlight and UV radiation. In the available literature, from 80% to 90% of eyelid lesions turn out to be benign and they predominantly occur in females [2, 4–6]. The most frequent diagnosis are: squamous papilloma (13–26%), xanthelasma (11.2–20%) (fig. 1A), seborrheic keratosis (12.6–21%) (fig. 1B), epidermal cysts (11.3–11.5%) (fig. 2) and intradermal nevus (7.2–33.8%) [2, 5–7].

Although the topic of malignant lesions expands beyond the boundaries of this article, it is important for a physician to acknowledge the most common of them, which are: basal cell carcinoma (BCC) (86%), squamous cell carcinoma (SCC) (7%) and sebaceous carcinoma (3%) [5]. What is more, benign tumors have to be differentiated from premalignant lesions, that include actinic keratosis and keratoacanthoma.

MANAGEMENT OF BENIGN SKIN LESIONS

Most of benign eyelid lesions do not require removal, however they can certainly pose significant cosmetic concerns. For that reason, many patients decide to have them treated. Some of the lesions, such as chalazion or pyogenic granuloma, can be usually managed with conservative therapy. The majority of them require a surgical treatment to be removed.

In the past decades, unconventional surgical therapies of benign eyelid lesions have emerged and developed. Apart from conventional surgical excision, various types of laser

FIGURE 1

Multiple xanthelasma of the upper and lower lid (A). Massive seborrheic keratosis of the upper eyelid (B).

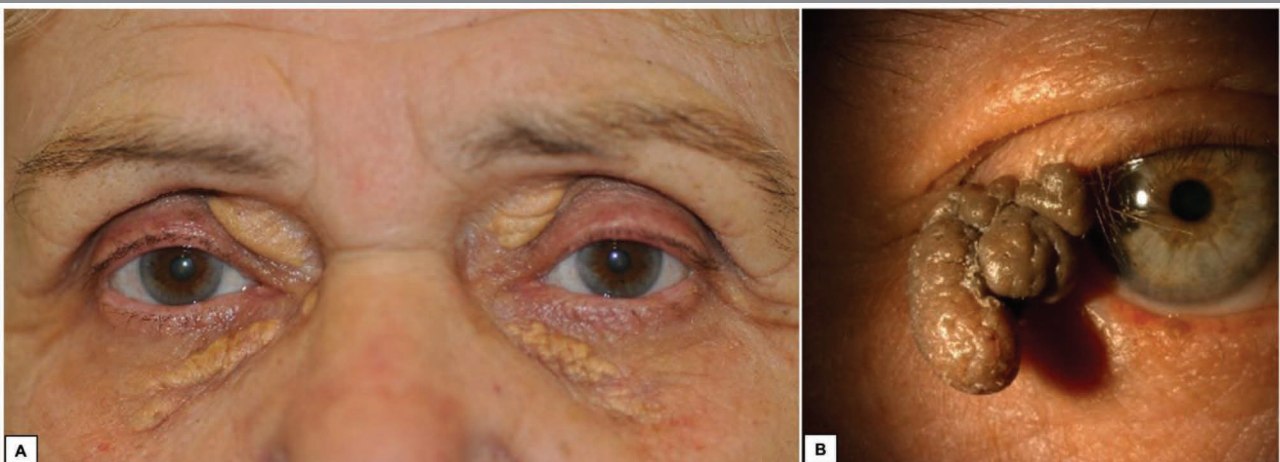
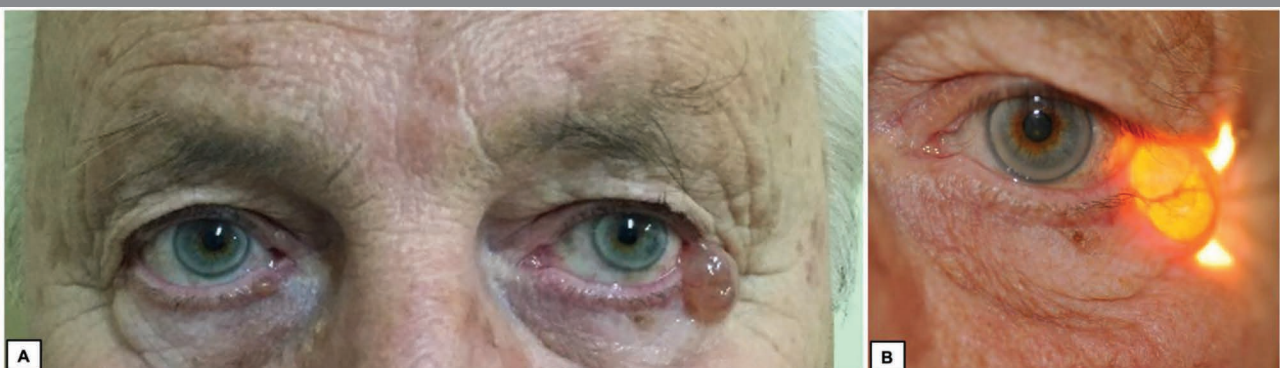

FIGURE 2

Epidermal cysts of the left lower lid (A, B).



and plasma-based therapies, cryosurgery and electrocautery can be performed.

Evaluation

Firstly, in diagnostic process, the visual evaluation with a microscope or a dermoscope has to be done. Before choosing a type of the treatment, following tests, that can improve the accuracy of a primary diagnosis, should be taken into account:

- photography of a lesion, in order to observe it and its potential growth in time (first visit after 6 months, then one per year)
- computed tomography (CT) or magnetic resonance imaging (MRI) scan to assess the extent of a lesion and its relation to surrounding tissues [8]
- high-resolution ultrasound to visualize lesion depth [9]

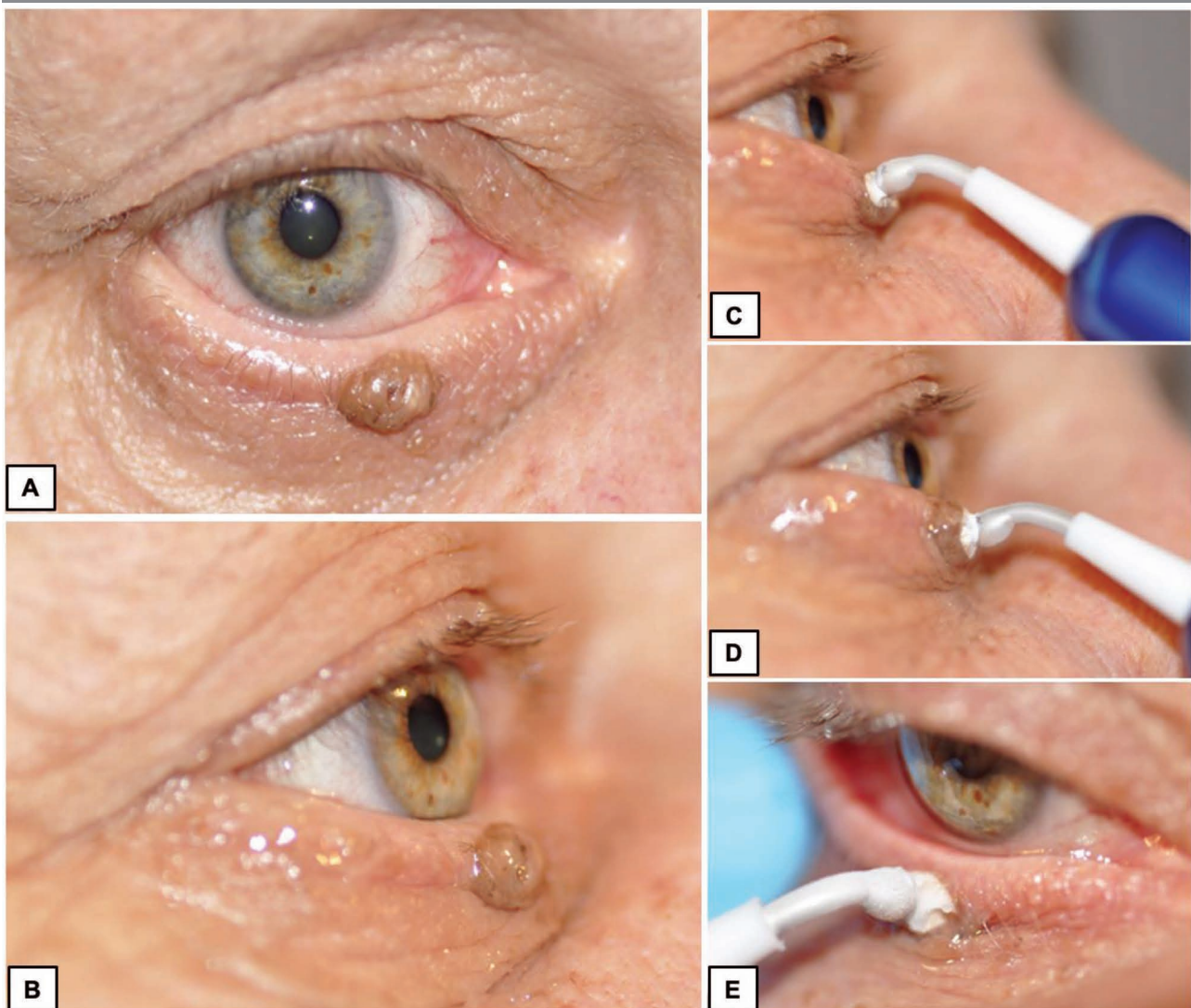
- reflectance confocal microscopy (RCM) to evaluate skin lesions at real time with cellular resolution; RCM can be used for selection of a biopsy area and evaluation of margins' clearance during surgical excision [10]
- biopsy followed by histopathological examination should be performed in case of any uncertainty to exclude any ongoing malignant processes.

Cryosurgery

Cryosurgery is a technique of application freezing temperatures to achieve the destruction of tissue. Cryotherapy, using liquid nitrogen as a cryogen, was incorporated into commercial use in the 1940s and, due to its safety, effectiveness, low cost, ease of use, lack of need for anesthesia and satisfying cosmetic results, has been continuously gaining popularity [11].

FIGURE 3

Squamous papilloma located in the lower eyelid (A, B). Squamous papilloma of the eyelid during application of cryosurgical probe (C, D, E).



The mechanism of tissue damage caused by freezing it includes extracellular ice formation (which leads to loss of water from the extracellular compartment), vascular stasis and occlusion and inflammation [12].

The variety of cryosurgery methods includes: open spray technique, application of a dipstick or cooled probe [11–13]. The choice of the method depends on the qualities of the lesion and the surgeon's preferences. The probe is applied directly to a lesion (fig. 3 C, D, E). Firm pressure and the use of lubricating jelly to facilitate contact with the lesion may shorten the freezing time. To prevent an excessive tissue damage, as soon as the ice forms, the probe and the lesion should be gently retracted [12]. It is important not to accelerate the thawing process, as it is a prime tissue-destructive factor [14].

Benign eyelid lesions that can be managed with cryosurgery include: molluscum contagiosum, seborrheic keratosis, conjunctival papilloma (fig. 4), squamous papilloma (fig. 3 A, B, fig. 5), dermatofibroma, vascular lesions (i.e. angiofibroma, capillary hemangioma), pyogenic granuloma, solar lentigo, verruca vulgaris and syringoma [3, 11–13].

Although cryosurgery is not a first-line therapy for malignant lesions, it can be considered in treatment for some malignant tumors such as BCC and SCC that present low-risk features (tab. 1) [11, 13]. Cryosurgery may be used in management of premalignant lesions, such as actinic keratosis, with excellent overall eradication rates [11].

Despite the advantages of such therapy, cryosurgery should not be performed on a skin lesion in which the diagnosis is uncertain, as well as in cases where a histopathological examination is required. Other contraindications include: high-risk BCC or SCC, melanoma, tumors with undefined margins and in cases of proven sensitivity or reaction to cryosurgery [13].

Laser treatment

Rapid development of laser technology increased its use in various dermatologic conditions, such as eyelid tumors. The mechanism of laser therapy is based on selective photothermolysis. It can be achieved by applying laser energy of the appropriate wavelength and pulse duration which leads to precise tissue damage [15]. This principle helps to select the best suited laser for a particular cutaneous lesion. Benign eyelid lesions that can be treated with laser therapies include:

FIGURE 4

Conjunctival papilloma of the palpebral conjunctiva before (A) and after (B) the application of cryosurgical probe.

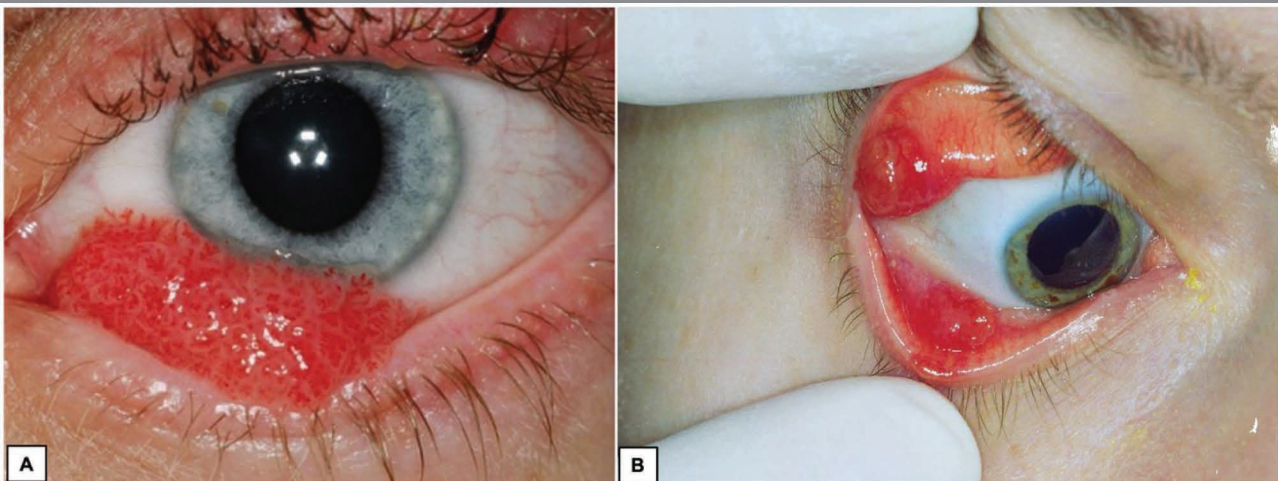


TABLE 1

Features of low-risk SCC or BCC [20].

Diameter < 2 cm
Depth < 3 mm
Lack of neurologic symptoms (i.e. pain, paresthesia)
Well-defined borders
Primary lesion (not a recurrent one)
Nodular or superficial type BCC
Well-differentiated SCC

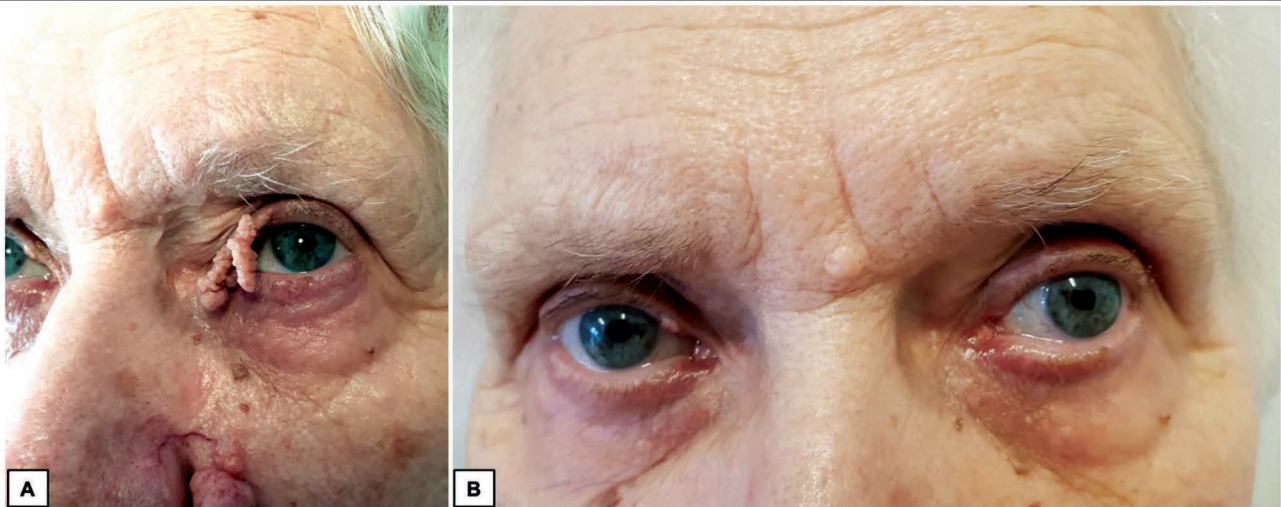BCC – basal cell carcinoma; SCC – squamous cell carcinoma.

vascular lesions, pigmented lesions, focal benign epidermal, adnexal and hyperplastic lesions [3, 15]. In this kind of treatment, it is important to use metal shields placed on the patient's cornea to protect the eye surface and for a physician to wear protective eyeglasses due to possible treatment side effects such as permanent vision loss, retinal ablation and vitreous hemorrhage.

Superficial vascular lesions that include: port wine stains, telangiectasias or infantile hemangiomas, can be treated with the yellow light-emitting pulsed dye laser (PDL) (585–600 nm) or the potassium titanyl phosphate (KTP) laser (532 nm) [15, 16]. Venous malformations and deep hemangiomas may

FIGURE 5

Squamous papilloma of the upper lid before (A) and after (B) 3 series of the cryotherapy.



be effectively managed with a longer wavelength, such as the alexandrite (Alex) (755 nm) or neodymium-doped yttrium aluminum garnet (Nd:YAG) (1064 nm) [15].

Laser technology can be considered in pigmented lesions treatment, such as melanocytic nevi and nevus of Ota. The best suited for those are the Q-switched (QS) lasers. Due to malignant potential of melanocytic nevi, excision followed by histopathological examination remains a treatment of choice. Laser treatment should be performed only in cases in which excision cannot be done [15].

Lasers may also be used as an ablative treatment for focal benign epidermal, adnexal, and hyperplastic lesions. For this indication, carbon dioxide (CO₂) and erbium-doped yttrium aluminum garnet (Er:YAG) lasers are used [15]. Benign eyelid lesions which can be treated with laser ablation are: syringoma, xanthelasma, milia, seborrheic keratosis and its variant – dermatosis papulosa nigra [3, 15].

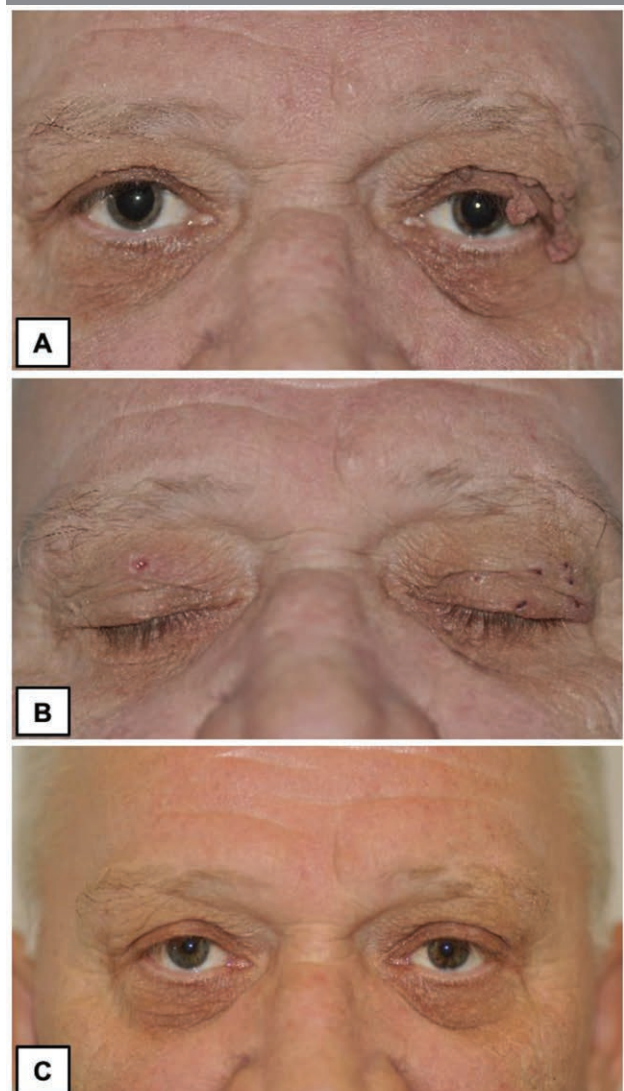
Plasma-based therapies

Nowadays, plasma-based devices are gaining popularity among other ablation therapies. Plasma is one of the four fundamental states of matter, along solid, liquid, and gas. It is formed by applying a sufficiently high electric field across a region of gas, which decreases or increases the number of electrons. That creates positive or negative charged particles called ions and leads to the breakdown of the gas [17, 18].

A plasma generator produces a controlled micro-plasma beam due to the ionization of the gases contained in the air. Focusing the beam on the epidermal lesions leads to their sublimation. Future studies are needed to provide more data about plasma-based ablation therapies, which have promising results in the management of various benign skin lesions such as xanthelasma, verruca vulgaris or squamous papilloma (fig. 6) [17].

FIGURE 6

Multiple squamous papilloma of the upper lids before (A), right after (B) and one month after (C) the plasma-therapy.



CONCLUSIONS

The incidence of eyelid lesions is high in an ophthalmological and dermatological examination. It is important for a physician to be able to distinguish malignant skin changes from benign ones, as they are characterized by higher recurrence rate, metastatic potential and may lead to death. Before proceeding to a specific treatment option, various tests, such a CT scan or RCM can be done to facilitate the decision-making process. If necessary, a biopsy followed by histopathological examination is always a management strategy of choice.

In case of the undoubtedly benign character of a lesion, its removal is optional, most frequently performed by cosmetic reasons. In recent decades various treatment strategies of lesions have developed, such as cryosurgery, laser therapies and plasma-based therapies. The choice of the therapy depends on the origin of lesion, its qualities and physician's preferences. Although these modalities have many advantages, i.e. good cosmetic results and effectiveness, in most cases they destroy the eyelid lesion in a way that makes obtaining a histological sample impossible. For this reason, precarious tumors should be subjected to biopsy before proceeding to the removal procedures.

Figures: from the authors' own materials.

CORRESPONDENCE

Anna Jagielak-Grab, MD

Department of Ophthalmology, Military Institute of Aviation Medicine, Warsaw
01-755 Warszawa, ul. Zygmunta Krasińskiego 54/56
e-mail: anna.jagielak@gmail.com

ORCID

Anna Jagielak Grab – ID – <https://orcid.org/0000-0003-2248-2197>
Dominika Białas – ID – <https://orcid.org/0000-0002-0082-9105>
Paulina Szabelska – ID – <https://orcid.org/0000-0002-6216-0646>
Radosław Różycki – ID – <https://orcid.org/0000-0001-7040-026X>

References

1. Kels BD, Grzybowski A, Grant-Kels JM. Human ocular anatomy. *Clin Dermatol.* 2015; 33(2): 140-6. <http://doi.org/10.1016/j.clindermatol.2014.10.006>.
2. Sendul SY, Akpolat C, Yilmaz Z et al. Clinical and pathological diagnosis and comparison of benign and malignant eyelid tumors. *J Fr Ophthalmol.* 2021; 44(4): 537-43. <http://doi.org/10.1016/j.jfo.2020.07.019>.
3. Stokkermans TJ, Prendes M. Benign Eyelid Lesions. In: StatPearls. Treasure Island (FL): StatPearls Publishing, 2023. <https://www.ncbi.nlm.nih.gov/books/NBK582155/>
4. Tesluk GC. Eyelid lesions: incidence and comparison of benign and malignant lesions. *Ann Ophthalmol.* 1985; 17(11): 704-7.
5. Deprez M, Uffer S. Clinicopathological features of eyelid skin tumors. A retrospective study of 5504 cases and review of literature. *Am J Dermatopathol.* 2009; 31(3): 256-62. <http://doi.org/10.1097/DAD.0b013e3181961861>.
6. Yu SS, Zhao Y, Zhao H et al. A retrospective study of 2228 cases with eyelid tumors. *Int J Ophthalmol.* 2018; 11(11): 1835-41. <http://doi.org/10.18240/ijo.2018.11.16>.
7. Huang YY, Liang WY, Tsai CC et al. Comparison of the Clinical Characteristics and Outcome of Benign and Malignant Eyelid Tumors: An Analysis of 4521 Eyelid Tumors in a Tertiary Medical Center. *Biomed Res Int.* 2015; 2015: 453091. <http://doi.org/10.1155/2015/453091>.
8. Kalemaki MS, Karantanas AH, Exarchos D et al. PET/CT and PET/MRI in ophthalmic oncology (Review). *Int J Oncol.* 2020; 56(2): 417-29.
9. Alexander JL, Wei L, Palmer J et al. A systematic review of ultrasound biomicroscopy use in pediatric ophthalmology. *Eye (Lond).* 2021; 35(1): 265-76.
10. Ferrari B, Salgarelli AC, Mandel VD et al. Non-melanoma skin cancer of the head and neck: the aid of reflectance confocal microscopy for the accurate diagnosis and management. *G Ital Dermatol Venereol.* 2017; 152(2): 169-77. <http://doi.org/10.23736/S0392-0488.16.05316-5>.
11. Zimmerman EE, Crawford P. Cutaneous cryosurgery. *Am Fam Physician.* 2012; 86(12): 1118-24.
12. Thai KE, Sinclair RD. Cryosurgery of benign skin lesions. *Australas J Dermatol.* 1999; 40(4): 175-84. <http://doi.org/10.1046/j.1440-0960.1999.00356.x>.
13. Clebak KT, Mendez-Miller M, Croad J. Cutaneous Cryosurgery for Common Skin Conditions. *Am Fam Physician.* 2020; 101(7): 399-406.

14. Gage AA, Baust J. Mechanisms of tissue injury in cryosurgery. *Cryobiology*. 1998; 37(3): 171-86. <http://doi.org/10.1006/cryo.1998.2115>.
15. Yates B, Que SK, D'Souza L et al. Laser treatment of periocular skin conditions. *Clin Dermatol*. 2015; 33(2): 197-206. <http://doi.org/10.1016/j.clindermatol.2014.10.011>.
16. Brauer JA, Geronemus RG. Laser treatment in the management of infantile hemangiomas and capillary vascular malformations. *Tech Vasc Interv Radiol*. 2013; 16(1): 51-4. <http://doi.org/10.1053/j.tvir.2013.01.007>.
17. Cheles D. Treatment of xanthelasma with fractional plasma. *Esperienze Dermatol*. 2021; 23: 1-6. <http://doi.org/10.23736/s1128-9155.21.00513-6>.
18. Hirst AM, Frame FM, Maitland NJ et al. Low temperature plasma: a novel focal therapy for localized prostate cancer? *Biomed Res Int*. 2014; 2014: 878319. <http://doi.org/10.1155/2014/878319>.

Authors' contributions:

Anna Jagielak-Grab 50%; Paulina Szabelska 20%; Dominika Białas 20%; Radosław Różycki 10%.

Conflict of interest:

The authors declare no conflict of interest.

Financial support:

None.

Ethics:

The content presented in the article complies with the principles of the Helsinki Declaration, EU directives and harmonized requirements for biomedical journals.