

Homocystinuria as a cause of ocular complications requiring surgical intervention



Adam Cywiński¹, Szymon Rzeźwicki², Łukasz Bednarski^{1,2}

¹ Silesian Eye Treatment Centre, Zory
Head: Adam Cywiński, MD, PhD

² Ophthalmology Department, Silesian Hospital in Cieszyn
Head: Agata Plech, MD, PhD

HIGHLIGHTS

Homocystinuria is one of the causes that should be considered in the diagnosis of lens dislocation. Confirming this diagnosis and implementing appropriate treatment allows for the avoidance of many complications, not just ophthalmological ones.

ABSTRACT

A 41-year-old man underwent surgery in both eyes due to diagnosed lens subluxation with significant decrease in visual acuity. In the left eye, an acute attack of angle-closure glaucoma caused by lens subluxation into the anterior chamber resulted in a combined procedure of lensectomy with posterior vitrectomy and silicone oil endotamponade due to iatrogenic retinal detachment. In the right eye, a procedure was performed to remove the subluxated natural lens with simultaneous intrascleral fixation of an artificial lens. During this procedure, the author's "Vampire" technique was used to facilitate the removal of the practically subluxated natural lens and reduce the risk of vitreous loss. Due to intraoperative complications, the left eye required further surgical procedures. Silicone oil removal from this eye was combined with repeat diagnostic testing to identify the cause of lens subluxation. The cause was found to be previously undiagnosed homocystinuria.

Key words: homocystinuria, lens subluxation, angle closure glaucoma, retinal detachment, homocysteine, methionine

INTRODUCTION

Homocystinuria is a rare inherited metabolic disorder that is characterized by elevated levels of homocysteine and methionine in the body. It is caused by decreased activity of cystathionine synthetase in the liver, which catalyzes the condensation of homocysteine with serine to form cystathionine, a precursor of cysteine and cystine [1]. It is a rare disease, its incidence is calculated at 1 case per 100,000 births [2].

Homocystinuria can lead to damage to many internal organs and is a cause of reduced life expectancy. Half of patients develop progressive mental retardation, and about 75% die before the age of 30 due to venous and arterial thrombosis [1]. Mental retardation does not always occur, as was initially suspected [3]. Among the symptoms, ocular manifestations are notable, and characteristic phenotypic features include tall stature, marfanoid appearance, blond hair, blue irises, and flushing of the cheeks.

Currently, the most important tool in the diagnosis of homocystinuria is newborn screening. Blood tests show elevated levels of homocysteine and methionine, and decreased levels of cysteine. In homozygotes, the concentration can reach up to 400 $\mu\text{mol/L}$ [4].

In Poland, since January 1, 2014, screening diagnostics for homocystinuria has been conducted [5]. It should be noted that in our population, there may be several hundred people with homocystinuria who are not aware of it because they have not undergone screening tests. It is also worth remembering the possibility of false negative results, for example, in patients who are pyridoxine-responsive [6].

TREATMENT

The goal of treatment is to achieve a homocysteine concentration below 100 $\mu\text{mol/L}$ [7]. Therapy aims to correct biochemical abnormalities through supplementation and diet. The diet mainly involves avoiding methionine and supplementing with cysteine. Supplementation with vitamin B₆ helps in 50% of cases [2, 8]. Typical treatment includes the administration of pyridoxine and anhydrous betaine, which is available free of charge under the “Treatment of severe congenital hyperhomocysteinemias” drug program. In patients who do not respond to pyridoxine treatment, a diet with the aforementioned restriction of methionine is used, which involves limiting protein intake and supplementing with mixtures of amino acids devoid of methionine. A homocysteine level of $\geq 15 \mu\text{mol/L}$ is considered elevated [9, 10].

In caring for the patient, surgical treatment and oral contraceptives should be avoided. In the case of anesthesia, nitrous oxide should be avoided, and blood glucose should be carefully monitored [11]. The importance of examining the patient's siblings is emphasized due to the increased risk of vascular eye diseases at an early age [6, 7, 12].

Typical phenotypic features of homocystinuria include tall stature, marfanoid appearance, blond hair, blue irises, and flushing of the cheeks. Additionally, atherosclerotic changes are observed at a relatively young age, as well as psychiatric disorders and mental retardation. Osteoporosis, scoliosis, deformity of the chest, and seizures are also described [2].

Patients have a tendency for thromboembolic incidents, and there is a belief that surgical procedures and general anesthesia increase their risk [13, 14]. Vascular disorders affect large and medium-sized arteries and veins throughout the body [2]. There are controversies regarding the influence of homocysteine levels on cardiovascular risk, and it is proposed that only very high concentrations of this amino acid increase this risk [15].

Elevated homocysteine levels that are not the result of a congenital disease may be a consequence of the use of stimulants and the intake of certain medications. Among these factors are smoking, alcohol consumption, coffee consumption, and the use of methotrexate, nitrous oxide, phenytoin, and carbamazepine [16].

CASE REPORT

A 41-year-old man was referred to the private medical center, Silesian Eye Treatment Centre in Zory (Poland), due to a decrease in visual acuity, especially in the left eye. During the diagnostic process, signs of an acute attack of angle-closure glaucoma caused by the subluxation of the crystalline lens into the anterior chamber (AC) of the left eye were diagnosed. An ophthalmologist, specializing in the treatment of glaucoma, performed repositioning of the lens to its proper anatomical position using a dynamic gonioscope and administering drugs to lower intraocular pressure locally and systemically.

Below are color photographs of the anterior segment of both eyes taken during the first consultation visit. In the right eye, a slight subluxation of the natural lens was observed, with its upper edge covered by the upper eyelid (fig. 1A). In the left eye, a significant subluxation of the natural lens was visible. The photograph was taken after its repositioning using a dynamic gonioscope with AC (fig. 1B).

Due to the high risk of recurrent lens subluxation into the AC and consecutive glaucoma attack, the patient was scheduled for lens removal surgery combined with intraocular lens implantation. However, the surgery could not be performed due to sudden, another acute glaucoma attack. The patient was urgently admitted to a local clinical center, where lensectomy was performed. Unfortunately, surgery was complicated by iatrogenic retinal detachment. A posterior vitrectomy with silicone oil endotamponade was performed. The postoperative visual acuity of this aphakic eye was: distance (logMar) with the best correction +8.0 Dsph,

-4.0 Dcyl and stenopeic slit = 0.7, near (Snellen) with the best correction D -3.0.

Because of the unsatisfactory postoperative result, the patient returned to the Silesian Eye Treatment Centre for the treatment of the right eye, where vision had gradually deteriorated. A planned surgery was scheduled using a customized artificial, toric lens with intrascleral fixation. The surgery was performed in a one-day surgery mode. A dedicated toric lens model, Soleko Carlevalle, was used due to the diagnosed corneal astigmatism of 2.75 Dcyl. During the surgery, an anterior vitrectomy was performed to remove the vitreous like also and the remaining lens matter along with the lens capsule. An innovative step of the surgery was the introduction of the author's technique for removing the soft natural lens, called the "Vampire" technique by the author.

This technique is applicable in the presence of a soft natural lens. The procedure is mainly useful in the eyes of young people when there is subluxation or even dislocation of the lens, and the lens is only held by the zonular fibers or on the anterior surface of the vitreous capsule.

The "Vampire" technique – steps:

1. Performing a punctate capsulotomy in the lens capsule by piercing the lens capsule using a knife type MVR 23-25G.
2. Inserting the aspiration tip into the lens and aspirating the lens matter to the extent possible.

3. During aspiration, the irrigation tip is not introduced into the eye.

The main aim of introducing this technique was to reduce the risk of vitreous loss during lens aspiration.

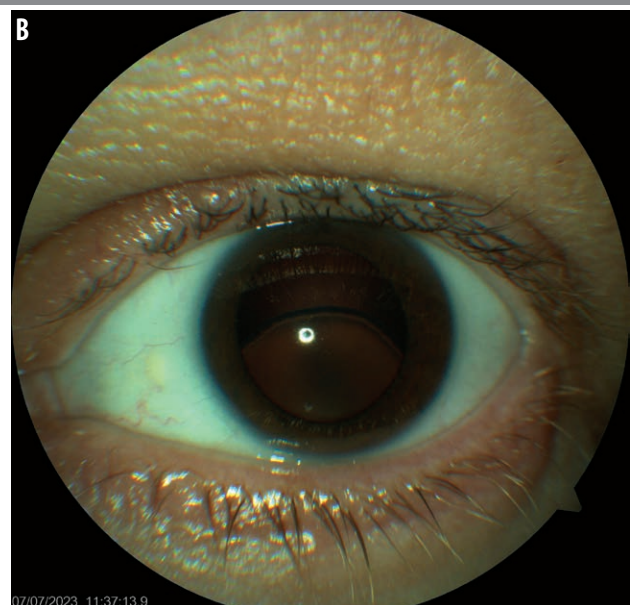
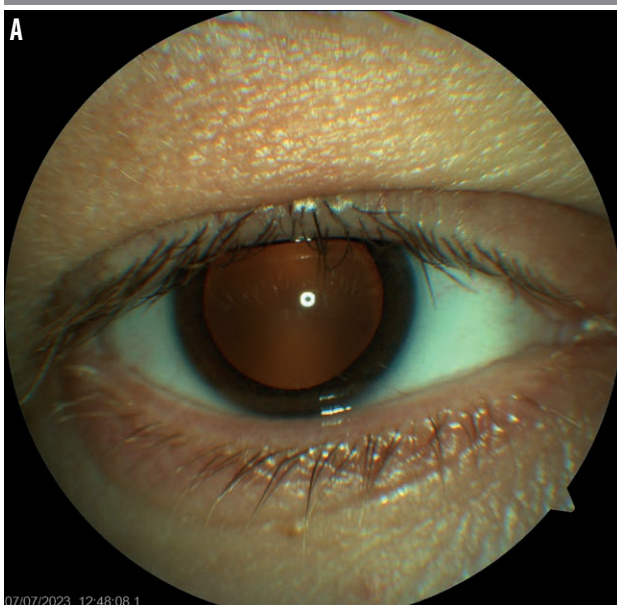
During the surgery, another intraoperative maneuver called the "underlay" technique by Dr. Cywiński was used. This maneuver involves inserting an artificial lens under the not yet removed lens masses present in the AC, increasing the chances of their removal without the need for intervention in the vitreous cavity. The underlay technique is also applicable in cases where it is necessary to remove a subluxated artificial lens and replace it with another model dedicated to fixation. Both techniques were presented in a video available on the Medtube portal entitled: "Vampire" technique in the removal of the natural lens [17]. The performed surgery and the techniques used not only allowed to avoid posterior vitrectomy, but also to preserve the function of the iris sphincter.

A few days after the surgery, moderate bleeding occurred, visible in the vitreous cavity. After its spontaneous resolution, visual acuity reached values: distance (logMar), without correction 0.4, with correction -0.75 Dsph, -1.0 Dcyl, 110° = 0.1; near (Snellen) D -0.5, without correction.

The next planned stage of treatment of the left eye was the removal of silicone oil, combined with the implantation of a lens and iris plastic surgery to reduce the diameter of the pupil. However, after performing a standard preoper-

RYCINA 1


A. Color photograph of the right eye's anterior segment. Status after pharmacological dilation of the pupil. The upper eyelid covers the upper edge of the lens, the visibility of which indicates its subluxation. B. Color photograph of the anterior segment of the left eye after pharmacological dilation of the pupil and the procedure of moving the lens from the AC using a dynamic gonioscope. Significant subluxation of the natural lens is visible.



ative examination, which is an assessment of the number of endothelial cells, the doctor decided only to remove the silicone oil, omitting the procedure to reduce the pupil diameter. A comparison of endothelial cell count in both eyes showed a significant decrease in the left eye, the cells were almost undetectable. A comparative examination performed in the range of endothelial cell count showed that in the left eye, their number was practically undetectable (fig. 2). Previous corneal thickness measurements for the left eye ranged from 750 to 800 μm .

RYCINA 2

Results of the endothelial cell count and corneal thickness examination performed postoperatively in both eyes before the planned procedure of silicone oil removal and iris plasty in the left eye. Attention is drawn to the reduced number of endothelial cells in the right eye (1754/ mm^2), while in the left eye, the number of cells is practically undetectable. The corneal thickness in both eyes exceeded 600 μm , and therefore, the intraocular pressure values require correction.



The presence of a low number of endothelial cells, below the value of 1,000/ mm^2 , significantly increases the risk of irreversible decompensation of the cornea in the situation of performing further surgical procedures in the anterior segment of the eye [18–20].

The silicon oil removal was successfully performed in the Ophthalmology Department of the Silesian Hospital in Cieszyn. This department was mentioned because it was there that a thorough diagnostic was performed to identify possible causes of lens subluxation.

This was also the department where additional diagnostic was performed, which finally identified the cause of the lens subluxation.

The result of this diagnostic was the detection of abnormally high homocysteine levels. Homocystinuria is therefore most likely the cause of all the complications observed in the patient, not only ophthalmic ones. Artificial Intelligence (AI) was used in the diagnostic process, considering two keywords: lens subluxation and tall stature. Although the patient was hospitalized in many clinical and provincial centers this condition was not considered at all, despite the occurrence of a hypercoagulable state in the patient's body. Biochemical tests showed the following values:

Homocysteine – 455 $\mu\text{mol/L}$ (5.46–16.2 $\mu\text{mol/L}$), vitamin B₁₂ – 138 pg/mL (191–663 pg/mL), folic acid – 3.26 ng/mL (4.6–18.7 ng/mL).

The obtained results indicate a nearly 30-fold increase in homocysteine levels, with simultaneous deficiency of vitamin B₁₂ and folic acid. Currently, after the inclusion of appropriate therapy, in the period from 23.03.2024 to 10.05.2024, the level of homocysteine decreased to values of 119–175 $\mu\text{mol/L}$. A vitamin B₁₂ test was also performed: dose 0 – homocysteine level 172 $\mu\text{mol/L}$, dose 200 mg – homocysteine level 154 $\mu\text{mol/L}$, dose 500 mg – homocysteine level 126 $\mu\text{mol/L}$. Methionine reached a value of 62 $\mu\text{mol/L}$.

A genetic test was also performed. In the genetic material examination from 21.02.2024, a heterozygous variant c.833T>Cp.(Ile278Thr) rs 5742905 in the CBS gene was found. The identified change is a known pathogenic variant associated with clinical symptoms of autosomal recessive homocystinuria [21].

Below is a differential diagnosis conducted by AI, including reasons of lens subluxation: Below we present a differential diagnosis of lens subluxation conducted by AI:

- Trauma: blow to the eye or head.
- Age-related changes: with age, the ligaments and other structures that hold the lens in place may weaken, leading to subluxation.
- Genetic disorders: some genetic disorders, such as Marfan syndrome, Ehlers–Danlos syndrome, and homocystinuria, can cause weakening of the connective tissue supporting the lens, leading to subluxation.
- Inflammation: inflammation of the eye, such as inflammation of the vascular membrane of the eye, can cause damage to the ligaments and other structures supporting the lens, leading to subluxation.

- Systemic diseases: some systemic diseases, such as diabetes and hypertension, may increase the risk of lens subluxation.
- High myopia: people with high myopia (severe myopia) may be at increased risk of lens subluxation due to elongation of the eye.
- Retinitis pigmentosa: this hereditary eye disease can cause changes in the eye that increase the risk of lens subluxation.
- Intraocular tumors: tumors in the eye can cause displacement of the lens and other structures.
- Congenital abnormalities: some people may be born with abnormalities in the structure or position of the lens that increase the risk of subluxation.

Until the ophthalmic procedures were performed in 2020–2023, the patient was hospitalized several times for non-ophthalmic reasons. While staying in clinical and provincial hospital departments, the patient was diagnosed with thrombophilia, vascular thrombosis, arrhythmia, bone necrosis, and septic shock. During this time, the patient also underwent several surgical procedures, including endoprosthesis of the left hip joint, heart ablation, amputation of the left lower leg due to popliteal artery thrombosis, and myocardial infarction.

DISCUSSION

Analyzing this extremely rare case raises certain considerations, the issue of diagnosis being the first one. The patient did not receive the diagnosis despite a number of consultations and stays in often renowned clinical centers. Neither did he receive an answer to the question whether his various symptoms were connected to each other eg. the lower leg amputation and the eye pathology? All the above lead to the conclusion – when there is no diagnosis stated, the diagnostic process should be continued, regardless of number of stays in different hospitals.

Considering the fact that human memory can fail us, one should fully use the achievements in the field of diagnostic possibilities, not excluding AI, which, regardless of the level of referral or the size of the center, ensures the possibility of conducting a differential diagnosis at the highest level. Starting to use AI can be a relatively easy way to meet the requirement of continuous professional development.

Regarding the author's Vampire technique presented in this work, searching for similar techniques in the past, an article by Gerding from 1998 deserves attention [22]. The author describes a technique for aspirating a subluxated lens in the sequence: small capsulorhexis (1.5 mm), aspiration of the lens mass using lacrimal duct cannulas. The concept behind the Vampire technique and Gerding's technique seems to be very similar, but the difference is diametrical. Gerding's

technique, which the author used in a child with diagnosed homocystinuria and a lens problem, could have been used in a situation where the patient's natural lens was only subluxated and was held by the zonular fibers. In present times, in the case of subluxation of the lens, a technique with the use of retractors would be used to remove it, trying to preserve not only the capsule but even introduce an artificial lens into it. This historical technique would not have worked in the described case and in states where the patient's natural lens is practically dislocated and is only held by single zonular fibers or on the vitreous capsule. However, both techniques indicate the need to use tailor-made solutions in non-standard cases.

Regarding ocular complications observed in homocystinuria, subluxation of the natural lens is most often mentioned. This condition is a consequence of the pathology in the structure of the apparatus supporting the lens in the eye. The ciliary body is rich in cysteine, the deficiency of which occurs in these patients leading to degeneration of the lens zonules, loss of accommodation, and ultimately displacement of the lens. Ectopia of the lens, which usually occurs before the age of 25, is typically located in the inferonasal quadrant. The displacement usually occurs in both eyes and is symmetrical. The direction of subluxation is not decisive, although subluxation of the lenses located inferiorly or inferiorly-nasally or into the AC suggests homocystinuria. A feature distinguishing homocystinuria from Marfan syndrome is the presence of broken fibers in the ciliary zonule, the number of which increases over time [2, 8]. Ectopia occurs in 80% of patients at the age of 15. In a histopathological examination, a thick layer of PAS-positive (*peripheral anterior synechiae*) material deposited on the surface of the ciliary body is noticeable [1].

During the surgery on the right eye of the described patient, the doctor noted a practical absence of zonular fibers over an area of more than 300° and had the impression that the lens was mainly held by the anterior vitreous capsule and a few remaining zonular fibers. The frequency of lens ectopia in an untreated population of patients can reach up to 80% [14]. As mentioned earlier, displacement of the lens into the AC or its entrapment in the pupil may also occur. These conditions can lead to closure of the angle of filtration and subsequently to secondary angle-closure glaucoma [23]. Other authors report that the lens never displaces upwards undergoes upward subluxation as in Marfan syndrome, which is an important diagnostic indication in patients with a marfanoid body structure. Remaining ocular symptoms that may occur in patients with diagnosed homocystinuria include: high myopia, retinal detachment, peripheral degeneration of the pigment epithelium. Optic nerve atrophy, iris atrophy, anterior staphyloma, lens and corneal opacities have also been described in patients with homocystinuria [1, 23].

In the differential diagnosis of non-traumatic ectopia of the lens, Marfan syndrome, aniridia and congenital glaucoma, Ehlers–Danlos syndrome, hyperlysinemia, Weill–Marchesani syndrome, sulfite oxidase deficiency, familial ectopia lentis, familial microspherophakia, Stickler syndrome, Sturge–Weber syndrome (sporadic), Crouzon syndrome (sporadic) should be considered [2, 13].

CONCLUSIONS

The use of AI in diagnostics should become a permanent method in the search for causes of signs and symptoms presented by the patient leading to the occurrence of the examined pathologies or diseases. Despite the lack of full precision of the answers, it can serve as a kind of reference point for fallible professional human memory.

In the case of subluxation of the natural lens, one should not focus solely on ophthalmic causes of such a state, an example of which is the mentioned homocystinuria. Among many congenital diseases, homocystinuria is remarkable stands out because there is a possibility of preventing its consequences. In this regard, the ophthalmologist may be the first person to suspect this fatal but potentially treatable disease.

It should be remembered that in the patient's family, in heterozygous individuals under 50 years of age, there is an increased risk of thrombosis and retinal vessel occlusion.

The Vampire technique is a procedure that facilitates the removal of a soft, practically dislocated natural lens in a situation where standard techniques are not applicable and we want one wants to avoid posterior vitrectomy.

CORRESPONDENCE

Adam Cywiński, MD, PhD

Śląskie Centrum Leczenia Oczu, Żory

44-240 Żory, ul Okrężna 11

e-mail: adamcyw@gmail.com

tel. +48 502 137 635

ORCID

Adam Cywiński – ID – <http://orcid.org/0000-0001-8732-7396>

References

1. Eagle RC. Eye Pathology an Atlas and Text. 2nd ed. LWW, 2011.
2. Okulistyka dziecięca i zez. BCSC 6. Seria Basic and Clinical Science Course. Hautz W, Loba P, Rękas M. (eds.). Edra Urban & Partner, Wrocław 2021.
3. Cross HE, Jensen AD. Ocular manifestations in the Marfan syndrome and homocystinuria. *Am J Ophthalmol.* 1973; 75: 405-20.
4. Interna Szczeklika 2023/2024. Szczeklika A, Gajewski P (eds.). Medycyna Praktyczna, Kraków 2023.
5. Ministerstwo Zdrowia. Rządowy program badań przesiewowych noworodków w Polsce na lata 2019-2026. <https://www.gov.pl/web/zdrowie/program-badan-przesiewowych-noworodkow-w-polsce-na-lata-2019-2026>.
6. Mulvihill A, Yap SM, O'Keefe M et al. Ocular Findings Among Patients with Late-Diagnosed or Poorly Controlled Homocystinuria Compared with a Screened, Well-Controlled Population. *J AAPOS.* 2001; 5(5): 311-5.
7. Morris A, Kozich V, Santra S et al. Guidelines for the diagnosis and management of cystathionine beta-synthase deficiency. *J Inherit Metab Dis.* 2017; 40: 49–74.
8. Yap S, Rushe H, Howard PM et al. The intellectual abilities of early-treated individuals with pyridoxine-nonresponsive homocystinuria due to cystathionine beta-synthase deficiency. *J Inherit Metab Dis.* 2001; 24(4): 437-47.
9. Yap S, Boers GH, Wilcken B et al. Vascular outcome in patients with homocystinuria due to cystathionine beta-synthase deficiency treated chronically: a multicenter observational study. *Arterioscler Thromb Vasc Biol.* 2001; 21(12): 2080-5.
10. Son P, Lewis L. Hyperhomocysteinemia. In: StatPearls [Internet]. StatPearls Publishing, Treasure Island (FL) 2024.
11. Sacharow SJ, Picker JD, Levy HL. Homocystinuria Caused by Cystathionine Beta-Synthase Deficiency. In: GeneReviews®. Adam MP, Ardinger HH, Pagon RA et al. (eds). University of Washington, Seattle 1993-2021.
12. Moorfields Manual of Ophthalmology. Jackson TL (ed.). Mosby, 2019.
13. Oxford Handbook of Ophthalmology. Murray PI, Denniston AKO. OUP, Oxford 2018.
14. Soczewka i zaćma. BCSC 11. Seria Basic and Clinical Science Course. Rękas M (ed.). Edra Urban & Partner, Wrocław 2021.
15. Smulders YM, Blom HJ. The homocysteine controversy. *J Inherit Metab Dis.* 2011; 34: 93-9.

16. Nygård O, Refsum H, Ueland PM et al. Major lifestyle determinants of plasma total homocysteine distribution: the Hordaland Homocysteine Study. *Am J Clin Nutr.* 1998; 67: 263-70.
17. Cywiński A. Technika "Wampirza" w usunięciu soczewki własnej. [Video] <https://medtube.pl/okulistyka/filmy-medyczne/39678-technika-wampirza-w-usunieciu-soczewki-wlasnej>.
18. Bowling B. *Okulistyka Kliniczna Kanski*. 8th ed. [Polish] Szaflik J, Izdebska J (pol. ed.). Edra Urban & Partner, Wrocław 2017.
19. Orski M. Wpływ różnych czynników na ubytek komórek śródbłonna rogówki. *Okulistyka po Dyplomie.* 2014; 4.
20. Wirbelauer C, Anders N, Pham DT et al. Early postoperative endothelial cell loss after corneoscleral tunnel incision and phacoemulsification in pseudoexfoliation syndrome. *Ophthalmologe.* 1997; 94: 332-6.
21. Gaustadnes M, Wilcken B, Oliveriusova J et al. The molecular basis of cystathionine β -synthase deficiency in Australian patients: genotype-phenotype correlations and response to treatment. *Hum Mutat.* 2002; 20: 117-26.
22. Gerding H. Ocular complications and a new surgical approach to lens dislocation in homocystinuria due to cystathionine- β -synthetase deficiency. *Eur J Pediatr.* 1998; 157(S2): S94-101.
23. Harrison DA, Mullaney PB, Mesfer SA et al. Management of ophthalmic complications of homocystinuria. *Ophthalmology.* 1998; 105(10): 1886-90.

Authors' contributions:

Adam Cywiński: idea, writing the article, editing.

Szymon Rzeźwicki: writing the introduction, editing, collection and literature review.

Łukasz Bednarski: editing, literature review.

Conflict of interest:

None.

Financial support:

None.

Ethics:

The content presented in the article complies with the principles of the Helsinki Declaration, EU directives and harmonized requirements for biomedical journals.