

Corneal imaging and densitometry measurements in patients with Fuchs' dystrophy undergoing penetrating keratoplasty and Descemet's stripping automated endothelial keratoplasty



Khaled Alzahrani^{1,2,3}, Jawaher Alshehri⁴, Arun Brahma²,
Fiona Carley², M. Chantal Hillarby^{1,2}

¹ Division of Pharmacy and Optometry, School of Health Sciences, University of Manchester, UK
Head: prof. Kaye Williams, BSc PhD

² Manchester Royal Eye Hospital, Manchester, UK
Medical Director: Bill Newman

³ Optometry Department, King Fahad Armed Forces Hospital
Head: dr Khaled Alzahrani

⁴ Department of Optometry, Al Baha University, Saudi Arabia
Head: dr Jawaher Alshehri

ABSTRACT

Aims: In the present study, we used the densitometry software from the Oculus Pentacam to compare postoperative corneal clarity between penetrating keratoplasty (PK) and Descemet's stripping endothelial keratoplasty (DSAEK) in patients with Fuchs' dystrophy.

Methods: A retrospective comparative study was carried out at Manchester Royal Eye Hospital. In 28 patients with Fuchs' dystrophy, corneal densitometry measurements were performed 12–18 months after corneal transplantation. The correlations of the densitometry measurements with the best corrected visual acuity (BCVA) and central corneal thickness (CCT) were analysed and compared between eyes that underwent PK and those that underwent DSAEK.

Results: Corneal densitometry measurements in the 33 eyes showed no significant differences between the PK and DSAEK post-surgery groups. There was no significant correlation between CCT and corneal densitometry measurements in either group ($P > 0.05$ in both cases). After DSAEK, corneal densitometry measurements were significantly correlated with BCVA in the central ($P = 0.01$), posterior ($P = 0.007$), and full-depth ($P = 0.008$) 0–2 mm zones of the cornea but not in PK group. The postoperative CCT was significantly different between the two groups ($P < 0.01$).

Conclusion: The 2 types of corneal transplantation resulted in different outcomes in terms of corneal densitometry measurements. Improved visual acuity after DSAEK was found to positively correlate with improvements in corneal clarity. Oculus Pentacam provides an objective evaluation tool to monitor corneal status after surgery.

Key words: cornea, Fuchs, stroma, densitometry, endothelial, dystrophy

HIGHLIGHTS

Improved visual acuity after Descemet's stripping endothelial keratoplasty positively correlates with improvements in corneal clarity. Corneal densitometry can be used to detect subtle changes that occur in the cornea after transplantation and to monitor recovery.

INTRODUCTION

Fuchs' endothelial dystrophy (FED) is usually treated with corneal transplantation [1, 2], which restores healthy endothelial function [3]. The first description of FED was published in 1900 by Ernst Fuchs, who described deposits known as guttata on the Descemet's membrane beneath the corneal endothelium; an abnormal extracellular matrix and endothelial cell loss were also apparent [4].

During the initial phase of the FED, epithelial oedema is absent. However, it builds up progressively in later stages. The degree of epithelial oedema is estimated by measuring the central corneal thickness (CCT). Corneal oedema begins within the central optical area and is a key cause of reduced vision in FED [5]. This is particularly severe in the morning due to reduced tear evaporation during sleep [6]. As the cornea becomes more oedematous, discomfort occurs, followed by extreme pain and photophobia. The eventual effects of extreme endothelial cell loss include stromal swelling, the creation of connective tissue in the stroma and epithelium, corneal oedema, and a clear vision reduction [7]. In 1900, the first successful full-thickness keratoplasty was performed by Edward Zirm. Since then, this approach has seen considerable alteration and progress. Currently, over 3,000 corneal transplants are conducted annually in the United Kingdom alone [8]. FED transplants account for 25.8% of the overall proposed number for corneal transplant [9]. Historically, FED was treated using full-thickness (penetrating) keratoplasty (PK), which replaces all 5 corneal layers. However, as only the endothelial layer is diseased in FED, it is possible to use Descemet's stripping automated endothelial keratoplasty (DSAEK), whereby only the posterior stroma and endothelium are replaced [10].

The success of these surgical procedures is evaluated in terms of best-corrected visual acuity (BCVA) and CCT. Clinically, Pentacam (OCULUS Optikgerate GmbH, Wetzlar, Germany) images are routinely used to assess patients undergoing transplant surgery. However, an update in computer software now allows corneal clarity to be measured in the same image. In the present study, we aimed to evaluate the use of corneal densitometry using Pentacam to assess the outcome of PK and DSAEK.

METHODS

Participants

This study was a retrospective, comparative, non-randomised cross-sectional study. It was approved by the Central Manchester University Hospitals NHS Foundation Trust, Manchester, United Kingdom, and by the local national research ethics committee. The study followed the tenets of the Declaration of Helsinki, and written, informed consent was obtained from all subjects after the study's nature had been ex-

plained to them. The study included patients with FED who had been visiting the Cornea Clinic of the Manchester Royal Eye Hospital. Patients were recruited from the corneal transplantation database, which started on 3rd of November 2015 till 1st of December 2017 for adult participants and juvenile by 2nd of June 2016 till December 2017.

Clinical notes were examined, and relevant information such as age, sex, date of surgery, and type of surgery was recorded for descriptive data analysis, as were postoperative parameters, including BCVA (in LogMAR) and clinical details.

Pentacam imaging

All imaging was performed by the same trained staff in a dark room 12–16 months after surgery. A single image that met the quality requirements of Pentacam analysis was taken from each patient. This study's inclusion criteria were: age ≥ 18 years, history of FED corneal transplantation (PK or DSAEK), completion of a 1-year post-treatment follow-up, availability of a Pentacam image from that time.

Surgical procedures

The surgical procedures (DSAEK and PK) were each performed by 1 of 2 surgeons; they used identical techniques during the respective procedures to minimise variation [11]. PK was performed using a standard technique that employs a Hessburg-Barron trephine (JedMed Instrument Co., St. Louis, MO) [12]. DSAEK was conducted according to standard techniques [13–15]. As FED is a corneal disease associated with ageing, a triple procedure of cataract extraction, intraocular lens implantation, and corneal transplantation was performed in that order when necessary.

Statistical analysis

Data analyses were carried out using SPSS V22.0 statistics software package for Windows. Descriptive statistics were presented as means (\pm standard deviation). The data normality was examined using the Shapiro–Wilk test, which is more appropriate for small sample sizes ($N < 50$). When parametric analysis was possible, the Student's *t*-test for two independent samples was used. All *P*-Values less than 0.05 were considered statistically significant.

RESULTS

A total of 33 eyes of 28 patients were studied. The sample characteristics were comparable between the groups; however, there were more women than men in both groups (PK 11 : 2 ; DSAEK 15 : 5); importantly, this did not constitute a significant difference between the groups ($P = 0.96$). The mean age of patients in the PK group was 70.0 (± 10.0) years, while that in the DSAEK group was 69.9 (± 9.84) years ($P = 0.96$).

In the PK group, 7 eyes (53.8%) achieved a postoperative BCVA of 0.3 LogMAR or better, while in the DSAEK group, 15 eyes (75%) achieved a postoperative BCVA of 0.3 LogMAR or better. The mean postoperative BCVA in the DSAEK group was 0.19 (± 0.12) LogMAR, which was better than that in the PK group: 0.37 (± 0.22) LogMAR; $P = 0.01$. Densitometry measurements showed that DSAEK causes less light scattering than PK in all layers of both the inner 0–2 mm zone of the cornea and the surrounding 2–6 mm annulus zone. However, further statistical analysis showed that none of the densitometry measurements' differences were significant ($P < 0.05$ in all cases; table 1).

TABLE 1
 Postoperative densitometry outcome in both central 0–2 mm and surrounding 2–6 mm of the corneal for anterior, middle, posterior and full depth layers for both PK and DSAEK.

Zones	Layers	PK; M (\pm SD)	DSAEK; M (\pm SD)	P value
0–2 mm	Anterior	26.05 (± 3.16)	25.26 (± 5.33)	0.63
	Central	23.19 (± 3.05)	21.59 (± 3.43)	0.18
	Posterior	18.34 (± 2.54)	17.87 (± 4.26)	0.72
	Full Depth	22.53 (± 2.75)	21.56 (± 3.77)	0.43
2–6 mm	Anterior	29.13 (± 4.34)	26.44 (± 5.8)	0.16
	Central	26.03 (± 5.15)	22.55 (± 5.68)	0.08
	Posterior	20.06 (± 3.8)	18.38 (± 4.66)	0.28
	Full Depth	25.07 (± 4.31)	22.44 (± 5.01)	0.11

DSAEK – Descemet's stripping endothelial keratoplasty; M – median; PK – penetrating keratoplasty; SD – standard deviation.

The mean CCT 1 year after PK treatment was 510.8 (± 54.9) μ m, while that 1 year after DSAEK treatment was 639.55 (± 59.0) μ m. Both CCT and the thinnest corneal area thickness were significantly different between the PK and DSAEK groups ($P < 0.05$) (tab. 2).

TABLE 2
 Postoperative central corneal thickness and thinnest area in both PK and DSAEK.

	PK; M (\pm SD)	DSAEK; M (\pm SD)	P Value
CCT	510.8 (± 54.9)	639.55 (± 59.0)	<0.01*
Thinnest Area	493.5 (± 60.7)	605.2 (± 53.5)	<0.01*

CCT – central corneal thickness; DSAEK – Descemet's stripping endothelial keratoplasty; M – median; PK – penetrating keratoplasty; SD – standard deviation.

Postoperative BCVA was not significantly correlated with the densitometry measurements and CCT after surgery in the PK group. However, in the DSAEK group, both correlations were significant ($P < 0.05$; correlation between

postoperative BCVA and densitometry measurement at the full-depth 0–2 mm: $r = 0.57$, $P = 0.008$; at the middle 0–2 mm: $r = 0.53$, $P = 0.01$; at the posterior 0–2 mm: $r = 5.80$, $P = 0.007$). Neither group showed a significant correlation between CCT and densitometry measurements in any corneal layers and any of the zones ($P > 0.05$). Figure 1 shows a linear regression comparison between the 2 groups at those zones found a significant correlation in DSAEK.

DISCUSSION

DSAEK is a comparatively new method for transplanting the endothelium from a donor cornea, and it is now the primary surgical treatment of FED [11, 16, 17]. DSAEK has several advantages over PK in patients with endothelial dystrophy; it is associated with fewer complications and a shorter recovery time [11, 18, 19]. Several studies have reported that PK and DSAEK differ in several areas [19], including rates of rejection and post-operation BCVA. Updates from Nanavaty have reported similar findings [18]. However, up to our knowledge, the present study was the first to find that postoperative densitometry measurements differed between DSAEK and PK in patients with FED, which show a significant correlation to BCVA in the DSAEK group.

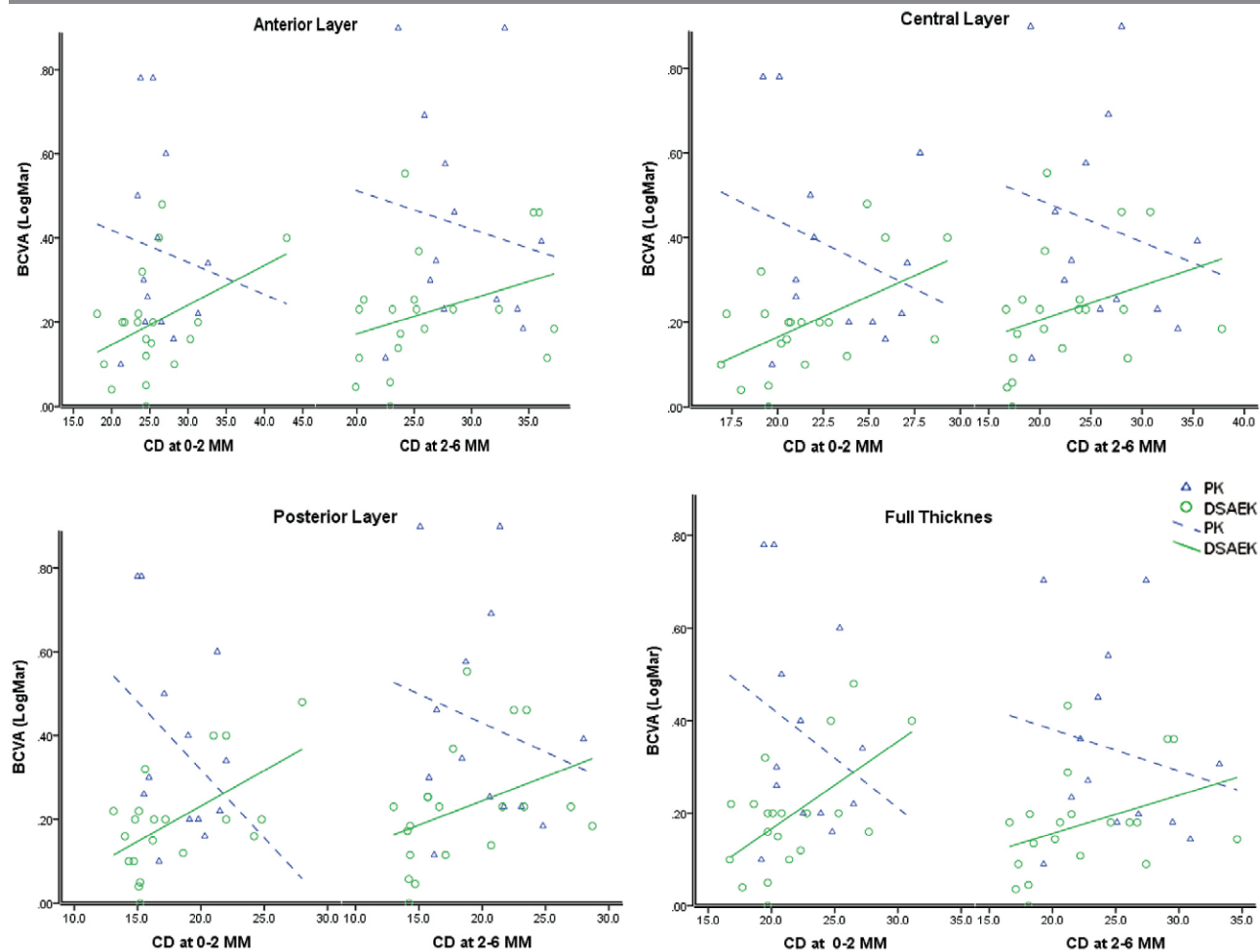
Scheimpflug imaging has numerous applications in corneal assessment. Moreover, with the updated software, it may be possible to measure the amount of backscattered light in diverse cornea regions [20, 21]. In this regard, corneal transparency is attributable to complex mechanisms, including size, regularity, and collagen fibrils arrangement [22].

The present study established that 12–18 months after surgery, the mean corneal densitometry in FED patients was somewhat higher than the normative value quantified in a previously published age-matched set [23, 24]. Patients who undergo PK still receive sutures that must be extracted, while patients who undergo DSAEK do not. Overall, in patients with PK, the corneal graft/host intersection requires 12–24 months of recovery and complete suture extraction. Moreover, as PK involves full-thickness grafting, it contradicts the eyes' structural and immunological integrity and can cause more significant harm than DSAEK. Indeed, PK causes greater damage to corneal tissue. The greater activation of keratocytes likely occurs as a reaction to trauma, leading to raised corneal densitometry measurements.

The average endothelial cell density loss per year after successful PK ranges from 7.8% between 3 and 5 years after surgery [25] to 4.2% between 5 and 10 years after surgery [26]. This is contrasted with a remarkable 50% loss of endothelial cells just 6 months after successful DSAEK [27]. Because the present study involved only a small sample and was retrospective, we had limited ability to research this matter. Therefore, future research must conduct a well-planned

FIGURE 1

The correlation between BCVA and corneal densitometry in PK and DSAEK (* represent significant at P-value of <0.05).



BCVA – best corrected visual acuity; CD – corneal depth; DSAEK – Descemet's stripping endothelial keratoplasty; PK – penetrating keratoplasty.

research that explores the function of the endothelium pump or alternative factors contributing to enhanced corneal transparency in FED following DSAEK.

The present research confirmed that postoperative BCVA is significantly better after DSAEK than after PK, probably because partial suture extraction is necessary during PK. Regarding postoperative BCVA measurement, comparisons between DSAEK and PK are best carried out after entire suture extraction; an additional review of each patient's clinical notes revealed that postoperative BCVA is improved after entire suture extraction. The present study found a considerable association between postoperative BCVA and densitometry quantification in the DSAEK group, corroborating previous studies [28, 29]. However, this correlation did not occur in the PK group. Positive correlations were also found in the central, posterior, and full depth layers.

We should clarify that we excluded patients from our data analysis if they experienced complications during or after surgery. DSAEK is renowned for providing swifter visual

rehabilitation than PK. Nonetheless, this has to be confirmed through additional research employing signals that are more dependable than visual results (e.g. contrast susceptibility and higher order aberration (HOA) steps following procedures), as well as larger sample sizes.

After surgery, visual acuity improvements can take several months or even years [27, 30, 31]. In this regard, visual acuity can be affected by the lamellar graft's thickness and the interfere optical quality of the graft/host interface [29, 32, 33]. However, there was no correlation between BCVA and corneal thickness in the current study compared to the previous studies [34].

Increased corneal densitometry was found in the stroma, the anterior cornea; overall, corneal thickness was also improved. Therefore, the changes detected using densitometry appeared to affect the whole stroma and consisted of more than simply an increase in light scatter as a result of subepithelial fibrosis or augmented scatter from the graft/host interface, although both components still can cause light scattering in post-DSAEK patients [7]. A significant rela-

tionship between visual outcome and corneal densitometry was recently discovered after DSAEK [28], corroborating observations of the present study. To some extent, Koh et al. reported higher values than we did. However, their study did not clearly define which thickness and diameter the densitometry measurements were acquired from. For this reason, the measurements are not directly comparable with those of the present study.

Poor graft interface can lead to graft failure. This illustrates the importance of maintaining a pristine graft interface and avoiding wrinkles in the graft across the pupillary area. In this regard, greater curvature disparities between recipient and donor corneas may promote wrinkle development [16, 35].

After surgery, gradual improvements in visual acuity are associated with increases in optical aberrations and corneal backscatter, which signify that the cornea is steadily restored after corneal oedema, with an average total corneal breadth of about 700 nm. In fact, reduced BCVA after DSAEK is sometimes believed to be caused by corneal backscatter (haze) [34, 36, 37]. However, backscatter cannot influence vision since it is not distributed around the retina. In contrast, forward scatter does alter vision, but it naturally causes glare rather than diminished visual acuity [38–41].

The present study found that the patients' average CCT was 510.8 (± 54.9) μm 1 year after PK and 639.55 (± 59.0) μm 1 year after DSAEK. This constituted a significant difference ($P = 0.0001$) and is similar to the results of [42] who documented an average CCT of 535.0 (± 45.0) μm 6 months after PK; this had increased to 580.0 (± 59) μm 5 years later. Nonetheless, the present study found no statistical correlation between BCVA and CCT in either group. Furthermore, CCT varies greatly among normal eyes.

The present study results agree with those of Terry et al. with regards to DSAEK graft thickness. They stated the following: 'graft thickness may have a small effect on visual outcomes in the extremes of thickness, but not in the common range of 100 μm to 200 μm , and donor thickness has a tenuous relationship with visual outcomes, accounting for only 5% of the variance in vision between patients, and should play a minimal role in surgical planning [40].

The present study was limited by its relatively small sample size and the possibility that suture removal may have affected the outcome, especially with respect to BCVA.

CONCLUSION

The present study showed that corneal densitometry can be used to detect subtle changes that occur in the cornea after transplantation and to monitor recovery. Densitometry may also further our understanding of the cornea in both normal and diseased conditions.

Acknowledgments: The authors thank the Manchester Royal Eye Hospital (corneal clinic) for supporting patient's recruitments for this study. Supported by Armed Forces Medical Services, Ministry of Defence, Riyadh, Saudi Arabia.

The abstract of this study was presented at the 2016 European Association for Vision and Eye Research Conference. This paper was chapter part of PhD thesis which submitted to the university of Manchester by 2018.

CORRESPONDENCE

Khaled Alzahrani, PhD

Optometry Division–Ophthalmology Department
King Fahad Armed Forces Hospital
Jeddah 21159 – Saudi Arabia
e-mail: khaledod@gmail.com

ORCID

Khaled Alzahrani – ID – <https://orcid.org/0000-0003-2325-7688>

References

1. Kang PC, Klintworth GK, Kim T et al. Trends in the indications for penetrating keratoplasty, 1980-2001. *Cornea*. 2005; 24(7): 801-3. <http://doi.org/10.1097/01.icc.0000157407.43699.22>.
2. Weisenthal R, Streeten B. Posterior membrane dystrophies. *Cornea*. 1997; 2: 1063-90.
3. Dapena I, Ham L, Melles GR. Endothelial keratoplasty: DSEK/DSAEK or DMEK – the thinner the better? *Curr Opin Ophthalmol*. 2009; 20(4): 299-307.
4. Bruinsma M, Tong C, Melles G. What does the future hold for the treatment of Fuchs endothelial dystrophy; will 'keratoplasty/still be a valid procedure & quest. *Eye*. 2013; 27(10): 1115-22.
5. Eghrari AO, Gottsch JD. Fuchs' corneal dystrophy. *Expert Rev Ophthalmol*. 2010; 5(2): 147-59.
6. Fuchs E. Dystrophia epithelialis corneae. *Albrecht von Graefes Archiv für Ophthalmologie*. 1910; 76(3): 478-508.
7. Kim JK, Kim SS, Lee HK et al. Laser in situ keratomileusis versus laser-assisted subepithelial keratectomy for the correction of high myopia. *J Cataract Refract Surg*. 2004; 30(7): 1405-11. <http://doi.org/10.1016/j.jcrs.2003.12.053>.
8. Tan DT, Dart JK, Holland EJ et al. Corneal transplantation. *Lancet*. 2012; 379(9827): 1749-61. [http://doi.org/10.1016/S0140-6736\(12\)60437-1](http://doi.org/10.1016/S0140-6736(12)60437-1).
9. Gaum L, Reynolds I, Jones MN et al. Tissue and corneal donation and transplantation in the UK. *Br J Anaesth*. 2012; 108(Suppl 1): i43-7. <http://doi.org/10.1093/bja/aer398>.
11. Keenan TD, Carley F, Yeates D et al.; NHSBT Ocular Tissue Advisory Group and contributing ophthalmologists (OTAG Audit Study 8). Trends in corneal graft surgery in the UK. *Br J Ophthalmol*. 2011; 95(4): 468-72. <http://doi.org/10.1136/bjo.2010.182329>.
12. Lim L, Pesudovs K, Coster DJ. Penetrating keratoplasty for keratoconus: visual outcome and success. *Ophthalmology*. 2000; 107(6): 1125-31.
13. Gorovoy M, Price F. New technique transforms corneal transplantation. *Cataract Refract Surg Today*. 2005; 11: 55-8.
14. Pramanik S, Goins, KM, Sutphin JE. Corneal Endothelial Transplantation: Descemet's Stripping Endothelial Keratoplasty (DSEK). *Eyeworlds.org*. February 23, 2006. <http://www.Eyeworlds.org/cases/54-Descemets-Stripping-Endothelial-Keratoplasty-DSEK.htm>.
15. Gorovoy MS. Descemet-stripping automated endothelial keratoplasty. *Cornea*. 2006; 25(8): 886-9.
16. Price MO, Fairchild KM, Price DA et al. Descemet's stripping endothelial keratoplasty five-year graft survival and endothelial cell loss. *Ophthalmology*. 2011; 118(4): 725-9. <http://doi.org/10.1016/j.ophtha.2010.08.012>.
17. Terry MA, Shamie N, Chen ES et al. Endothelial keratoplasty for Fuchs' dystrophy with cataract: complications and clinical results with the new triple procedure. *Ophthalmology*. 2009; 116(4): 631-9. <http://doi.org/10.1016/j.ophtha.2008.11.004>.
18. Nanavaty MA, Wang X, Shortt AJ. Endothelial keratoplasty versus penetrating keratoplasty for Fuchs endothelial dystrophy. *Cochrane Database Syst Rev*. 2014; 2014(2): CD008420.
19. Nanavaty MA, Shortt AJ. Endothelial keratoplasty versus penetrating keratoplasty for Fuchs endothelial dystrophy. *Cochrane Database Syst Rev*. 2011; (7): CD008420.
20. Lopes B, Ramos I, Ambrósio Jr R. Corneal densitometry in keratoconus. *Cornea*. 2014; 33(12): 1282-6.
21. Alnawaiseh M, Rosentreter A, Eveslage M et al. Changes in Corneal Transparency After Cross-linking for Progressive Keratoconus: Long-term Follow-up. *J Refract Surg*. 2015; 31(9): 614-8. <http://doi.org/10.3928/1081597X-20150820-07>.
22. Maurice DM. The structure and transparency of the cornea. *The Journal of Physiology*. 1957; 136(2): 263-86.
23. Ní Dhubhghaill S, Rozema JJ, Jongenelen S et al. Normative values for corneal densitometry analysis by Scheimpflug optical assessment. *Invest Ophthalmol Vis Sci*. 2014; 55(1): 162-8. <http://doi.org/10.1167/iov.13-13236>.
24. Alzahrani K, Carley F, Brahma A et al. Corneal clarity measurements in healthy volunteers across different age groups: Observational study. *Medicine (Baltimore)*. 2017; 96(46): e8563. <http://doi.org/10.1097/MD.00000000000008563>.
25. Bourne WM, Hodge DO, Nelson LR. Corneal endothelium five years after transplantation. *American Journal of Ophthalmology*. 1994; 118(2): 185-96.
26. Ing JJ, Ing HH, Nelson LR et al. Ten-year postoperative results of penetrating keratoplasty. *Ophthalmology*. 1998; 105(10): 1855-65. [http://doi.org/10.1016/S0161-6420\(98\)91030-2](http://doi.org/10.1016/S0161-6420(98)91030-2).
27. Koenig SB, Covert DJ, Dupps WJ Jr et al. Visual acuity, refractive error, and endothelial cell density six months after Descemet stripping and automated endothelial keratoplasty (DSAEK). *Cornea*. 2007; 26(6): 670-4. <http://doi.org/10.1097/ICO.0b013e3180544902>.
28. Koh S, Maeda N, Nakagawa T et al. Quality of vision in eyes after selective lamellar keratoplasty. *Cornea*. 2012; 31(Suppl 1): S45-9. <http://doi.org/10.1097/ICO.0b013e318269c9cd>.
29. Ivarsen A, Hjortdal J. Recipient corneal thickness and visual outcome after Descemet's stripping automated endothelial keratoplasty. *Br J Ophthalmol*. 2014; 98(1): 30-4.
30. Price MO, Price FW. Descemet's stripping with endothelial keratoplasty: comparative outcomes with microkeratome-dissected and manually dissected donor tissue. *Ophthalmology*. 2006; 113(11): 1936-42.

31. Li JY, Terry MA, Goshe J et al. Three-year visual acuity outcomes after Descemet's stripping automated endothelial keratoplasty. *Ophthalmology*. 2012; 119(6): 1126-9. <http://doi.org/10.1016/j.ophtha.2011.12.037>.
32. Neff KD, Biber JM, Holland EJ. Comparison of central corneal graft thickness to visual acuity outcomes in endothelial keratoplasty. *Cornea*. 2011; 30(4): 388-91.
33. Busin M, Madi S, Santorum P et al. Ultrathin descemet's stripping automated endothelial keratoplasty with the microkeratome double-pass technique: two-year outcomes. *Ophthalmology*. 2013; 120(6): 1186-94. <http://doi.org/10.1016/j.ophtha.2012.11.030>.
34. Mencucci R, Favuzza E, Tartaro R et al. Descemet stripping automated endothelial keratoplasty in Fuchs' corneal endothelial dystrophy: anterior segment optical coherence tomography and in vivo confocal microscopy analysis. *BMC Ophthalmol*. 2015; 15: 99. <http://doi.org/10.1186/s12886-015-0096-x>.
35. Price MO, Giebel AW, Fairchild KM et al. Descemet's membrane endothelial keratoplasty: prospective multicenter study of visual and refractive outcomes and endothelial survival. *Ophthalmology*. 2009; 116(12): 2361-8. <http://doi.org/10.1016/j.ophtha.2009.07.010>.
36. Anshu A, Planchard B, Price MO et al. A cause of reticular interface haze and its management after descemet stripping endothelial keratoplasty. *Cornea*. 2012; 31(12): 1365-8. <http://doi.org/10.1097/ICO.0b013e31823d027d>.
37. Hindman HB, Huxlin KR, Pantanelli SM et al. Post-DSAEK optical changes: a comprehensive prospective analysis on the role of ocular wavefront aberrations, haze, and corneal thickness. *Cornea*. 2013; 32(12): 1567-77. <http://doi.org/10.1097/ICO.0b013e3182a9b182>.
38. Unterlauff JD, Elsaesser K, Grehn F et al. Intraocular Pressure and Trabecular Meshwork Outflow Facility After Descemet Stripping Endothelial Keratoplasty. *J Glaucoma*. 2016; 25(3): 263-8. <http://doi.org/10.1097/IJG.0000000000000208>.
39. Terry MA, Shamie N, Chen ES et al. Precut tissue for Descemet's stripping automated endothelial keratoplasty: vision, astigmatism, and endothelial survival. *Ophthalmology*. 2009; 116(2): 248-56. <http://doi.org/10.1016/j.ophtha.2008.09.017>.
40. Terry MA, Straiko MD, Goshe JM et al. Descemet's stripping automated endothelial keratoplasty: the tenuous relationship between donor thickness and postoperative vision. *Ophthalmology*. 2012; 119(10): 1988-96. <http://doi.org/10.1016/j.ophtha.2012.05.021>.
41. Wacker K, Bourne WM, Patel SV. Effect of Graft Thickness on Visual Acuity After Descemet Stripping Endothelial Keratoplasty: A Systematic Review and Meta-Analysis. *Am J Ophthalmol*. 2016; 163: 18-28.
42. Verdier DD, Sugar A, Baratz K et al.; Cornea Donor Study Investigator Group. Corneal thickness as a predictor of corneal transplant outcome. *Cornea*. 2013; 32(6): 729-36. <http://doi.org/10.1097/ICO.0b013e31827b14c7>.

Authors' contributions:

Khaled Alzahrani 40%; Jawaher Alshehri 15%; Arun Brahma 15%; Fiona Carley 15%; Chantal Hillraby 15%.

Conflict of interest:

None.

Financial support:

None.

Ethics:

The content presented in the article complies with the principles of the Helsinki Declaration, EU directives and harmonized requirements for biomedical journals.