

Differential diagnosis of pituitary macroadenoma before performing head and orbits neuroimaging



Grzegorz Rotuski¹, Jaromir Wasyluk^{1,2}, Radosław Różycki^{1,3}

¹ Ophthalmology Clinic, Military Institute of Aviation Medicine, Warsaw
Head: Radosław Różycki, MD, PhD

² OPTIMUM, Medical Center in Warsaw
Head: Małgorzata Krajewska, MD, PhD

³ ORBITA, Medical Center in Warsaw
Head: Radosław Różycki, MD, PhD

HIGHLIGHTS

Understanding the visual field defects is key to selecting patients for head imaging.

ABSTRACT

Visual field defects resulting from compressive or infiltrative lesions in the visual pathway often differ from typical textbook patterns. This results from asymmetric tumor growth or uneven impact of individual nerve fibres, which also differ in their susceptibility to damage. In addition, the reliability of perimetry based on false positive and negative errors on the part of the examined person must be taken into account. Neuroimaging comes in handy with interpretation of doubtful cases. Unfortunately, sometimes the visual field defects can mimic glaucomatous defects, especially in correlation with elevated intraocular pressure as an incidental finding. This delays making the critical diagnosis and proper treatment of the patient. In ophthalmological practice, knowledge of the proliferative processes of the central nervous system, together with the basic characteristics of these diseases, plays a crucial role in the clinical assessment of indications for extended diagnostics.

Key words: pituitary adenoma, pituitary macroadenoma, optical coherence tomography, OCT, visual field

INTRODUCTION

The image landing on the retina is reduced, inverted and real. It is inverted both in the vertical and horizontal axis. This means that, for example, the upper-right part of the image is received by the inferior-temporal quadrant of the left eye retina and the inferior-nasal quadrant of the right eye retina, respectively. These are the so-called corresponding receptive fields in both eyes, which are subject to fusion during binocular viewing. Due to the field of view of each eye not being perfectly circular, its extreme peripheral parts do not overlap precisely. However, due to the very low visual acuity in such distal sectors, subjective diplopia does not occur.

The visual pathway begins with the photoreceptors of the retina – cones and rods. In the dark, rhodopsin – a pigment present in the cell body – secretes glutamate, which causes constant depolarization of bipolar cells. Under the influence of light, the bent cis-retinal is transformed into straightened trans-retinal and detaches from the opsin, which inhibits the secretion of glutamate, allowing hyperpolarization of the cell membranes of bipolar cells [1]. From there, after the signal is transduced from chemical to electrical, it passes on to the bipolar cells, and thus migrates to the inner layers of the retina. Bipolar cells are classified as “on” if they depolarize in response to light and “off” if depolarization occurs in the dark [2]. Then the impulse passes through synapses with ganglion cells, which are the third neuron of the visual pathway. Long axons of ganglion cells leave the eyeball through the lamina cribrosa, passing further in the myelin sheath through the superior orbital fissure to the sella turcica, before which the fibers from the nasal parts of the retinas cross sides.

After joining the bundle of contralateral temporal fibers, they continue as the left and right visual tracts to the left and right lateral geniculate bodies respectively, and communicate with the fourth and last neuron of the visual pathway. The axons are not randomly situated in the bundles: the ipsilateral ones are arranged in layers 2, 3, 5 and the contralateral ones in layers 1, 4, 6. Fields 1 and 2 contain M cell axons; fields 3, 4, 5, 6 contain P cell axons; and K cell axons terminate between these layers [3].

The fibers then split, arcing to the occipital lobes as the visual radiation – reaching the 6-layered visual cortex. Thus, in relation to the zero meridian, the left-sided parts of the visual field of both eyes behind the optic chiasm are located in the right visual band where they continue to the right lateral geniculate body and the right visual radiation, no longer crossing with the fibers of the left hemisphere of the brain. The trajectory is analogous with the right-sided parts of the visual field. Fibers carrying information from the upper retinal quadrants pass just behind the lenticular nuclei, they are responsible for the lower parts of the visual field, creating the so-called Baum’s loop, which turns

dorsally before ending in a fan-shaped manner in the occipital cortex [4]. In turn, under the lenticular nuclei, fibers from the lower retinal quadrants, i.e. the upper parts of the visual field, first go anterolaterally, and then run in an arcuate manner towards the back, reaching a similar location in the occipital lobe, but above the calcarine sulcus and creating the so-called Meyer’s loop. Beyond these bifurcations, the bundle of macular fibers goes straight to the common target. In this way, the central vision area is located most posteriorly in the occipital lobe, other parts of the visual field on the other hand – the more peripheral they are, the more anteriorly they are located along the calcarine sulcus [5]. Thus, damage to the fibers of the visual radiation in the temporal lobe causes homonymous upper quadrantanopsia called “pie in the sky”, and damage to the parietal lobe causes homonymous lower quadrantanopsia called “pie on the floor” [6]. The visual pathway ends in the occipital cortex, but the interpretation of visual stimuli does not stop there. Some cells of the primary visual cortex (V_1) send their axons towards the parietal and temporal lobes, creating the so-called ventral and dorsal stream for detailed image analysis [7]. Information from P cells, which conduct data about the location of the object, and from M cells, which perceive the movement of the object, goes to field 7 and the upper parts of fields 37 and 39 in the posterior part of the parietal lobe. Additional synaptic connections conveying information from P cells about object color and shape occur with areas 20 and the upper parts of 37 and 39. The dorsal stream is responsible for the spatial orientation of an object in relation to the rest of the environment, the analysis of the direction and speed of its movement, and thus also enables tracking movements of the eyeballs. The ventral stream is in charge of identifying and remembering the type of object and its color, including recognizing and reading text. However, this is not all. It should also be noted that before reaching the lateral geniculate bodies, individual fibers communicate with the suprachiasmatic nucleus of the hypothalamus (regulating the circadian rhythm based on sunlight), the pretectal nuclei (pupil reaction to light and near) and the superior colliculi in the midbrain (positioning the head and body in relation to the environment and intended directions of gaze through smooth tracking movements or rapid adjustments, so-called saccades) [8]. These are sensory nuclei, so they receive signals on the basis of which movements are intended, e.g. pupil constriction is caused by an impulse from the Westphal–Edinger nucleus, and gaze coordination takes place in the medial longitudinal fasciculi (horizontal saccades and the horizontal gaze center, and the interstitial nucleus of Cajal is responsible for maintaining the gaze in a horizontal deviation) and the paracentral reticular formation of the pons (vertical saccades and the center for vertical gaze center, and the prehypoglossal nucleus is responsible for maintaining the gaze in a ver-

tical deviation) [9]. In the thalamus, or more precisely in the peduncle, visual information is integrated through bidirectional connections with the associative cortex of individual cerebral lobes, and damage to this structure may result in sensory aphasia in an ophthalmological examination, i.e. the inability to interpret the image seen by the patient (in the case of the temporal lobe) or disorders of reading, writing, spatial orientation and hemispatial neglect syndrome (in the case of the parietal lobe) [10]. Moreover, vision is an important component of the sense of balance for humans, integrally with stimuli from the semicircular canals and proprioception.

CENTRAL NERVOUS SYSTEM PATHOLOGIES AFFECTING THE VISUAL PATHWAY

Visual field defects, apart from high-tension glaucoma, most often result from ischemia of neurons in the visual pathway, for example in anterior ischemic optic neuropathy. In this paper, we will focus on proliferative pathologies in the anterior, middle and posterior cranial fossa, which should be considered when differentiating changes in the patient's visual field examination. Sectoral demyelinating changes may appear along the entire visual pathway, producing a central scotoma in the image or diffuse visual field defects, which often prompt referral for imaging. In the case of a central scotoma with a history of sudden deterioration of vision, attention should be paid to the possible appearance of defects in the superior-temporal part of the visual field of the other eye. The tumor may then compress the von Willebrand's knee, i.e. fibers from the inferior-nasal parts of the retina that bend forward in the contralateral optic nerve before continuing through the chiasm. This creates the so-called Traquaire's junctional scotoma [11].

The causes of proliferative growths in the orbit can be initially assessed with an ultrasound examination of the eyeball, but the detection of a pathological mass in the periorbital space will most likely require a more detailed assessment with computed tomography or magnetic resonance imaging. Electrophysiological studies can be helpful, in particular visual evoked potentials, which will assess conduction disorders in the visual pathway, as well as OCT (optical coherence tomography), which will show a sectoral decrease in the thickness of the ganglion cell complex and the peripapillary nerve fibers layer.

Visual field disorders may be caused by a disease in the eyeball itself, but also by a pathology in the visual pathway which transmits light stimuli to the cerebral cortex, where the image landing on the retina is interpreted. The causes may include primary and metastatic intracranial tumors (meningioma, glioma, schwannoma, pituitary adenoma, craniopharyngioma, carcinoma of the nasopharynx and paranasal sinuses, sphenoid sinus mucocele, hyperostosis,

e.g. Paget's disease, fibrous dysplasia, sarcoma, leukemic infiltration, lymphoma), aneurysms (of the ophthalmic artery, components of the circle of Willis, arteriovenous fistulas, cavernous sinus hemangioma), cysts (arachnoid cysts, Rathke's pouches), hamartomas (e.g. thalamus), changes of inflammatory origin (demyelinating diseases, granuloma in sarcoidosis, tuberculoma, syphilis, abscesses), ischemic (arteriosclerosis, pituitary apoplexy) and toxic origin [12].

PITUITARY MACROADENOMA – MAKING THE DIAGNOSIS, DIFFERENTIAL AND TREATMENT

Hyperplastic changes in the Rathke pouch are the main changes taken into account in the differentiation of tumors of the sella turcica region [13]. They can be benign cysts or give rise to malignant squamous metaplasia with the development of craniopharyngioma. Typically, pituitary adenoma presents in magnetic resonance imaging as a lesion with a signal similar to gray matter, enhancing homogeneously after contrast administration, but the image may be atypical in the case of tissue necrosis, cystic degeneration or bleeding. Craniopharyngioma statistically most often develops suprasellarly, exerting pressure on the optic chiasm from above, which causes scotomas in the temporal quadrants of the inferior visual field. However, it can also develop intrasellarly and cause visual disturbances similar to the clinical picture of pituitary adenoma. Additionally, it causes balance, mood and behavioral disorders, headaches, polydipsia and polyuria, nausea and vomiting.

CASE REPORT

In simple terms, changes in front of the chiasm usually cause visual field defects in one eye, changes involving the chiasm – bitemporal hemianopsia, and behind the chiasm – contralateral homonymous hemianopsia. In our patient, changes in the visual field involved both temporal quadrants of the visual field of the left eye and the superior temporal quadrant of the right eye. A typical textbook picture in the case of pituitary adenoma causes bitemporal hemianopia, but in practice, an equal cut-off in relation to the zero meridian is rarely observed due to the uneven growth of the tumor and individual asymmetry of the optic chiasm structure. In 10% of cases, the chiasm lies slightly in front of or behind the central part of the pituitary gland. Our patient reported to the emergency ophthalmology department because of a sudden observation of limitations in the field of vision in the morning after waking up. Apart from that, he did not report any other complaints. He denied the abnormalities typical of different types of pituitary adenoma, which are presented in the table 1 [14]. Prolactinoma, a tumor secreting prolactin, is the most common type of tumor (approx. 30%), slightly less frequently histopatho-

logically detected are somatostatinoma secreting growth hormone (approx. 20%) and corticotropinoma secreting cortisol (approx. 10%), the remaining ones include thyrotropinoma secreting thyroid-stimulating hormone (approx. 1%) and other mixed or hormonally inactive tumors [15].

neurosurgical department. The histopathological result revealed a gonadotropic pituitary adenoma. This type of tumor is usually hormonally inactive, therefore it mainly causes symptoms resulting from pressure on the adjacent tissues due to the mass effect [16, 17]. Most often diagnosed

TABLE 1

Disorders typical of different types of pituitary adenoma.

Pituitary tumor	Prolactinoma	Somatostatinoma	Corticotropinoma	Thyrotropinoma
Symptoms	<ul style="list-style-type: none"> • menstrual disorders and infertility • decreased libido • hirsutism (women) • gynecomastia (men) • galactorrhea • bone loss and risk of osteoporosis • delayed puberty in adolescents 	<ul style="list-style-type: none"> • gigantism (children) • acromegaly (adolescents and adults) – enlargement of the hands, feet, jaw bones and tongue • joint pain, carpal tunnel syndrome and osteoporosis • muscle weakness • deepening of the voice • diabetes • hypertension • hypertrophic cardiomyopathy • acanthosis nigricans and tortuous skin of the crown 	<ul style="list-style-type: none"> • Cushing syndrome • obesity • acne • skin stretch marks • bone pain and osteoporosis • hypertension • diabetes • moon face and buffalo hump • hirsutism (women) • menstrual disorders • muscle weakness • reduced immunity 	<ul style="list-style-type: none"> • hyperthyroidism • irritability, nervousness, problems with concentration • hypersensitivity to high temperatures and increased sweating • muscle weakness • accelerated heart rate and palpitations • weight loss despite good appetite • hand tremors • constipation and diarrhea • hair loss and brittle nails • menstrual disorders • infertility • itchy skin • no symptoms of thyroid orbitopathy

Physical examination revealed no signs of increased intracranial pressure. The patient denied headaches (present in almost half of patients with pituitary macroadenoma), nausea, diplopia (in the case of lateral tumor growth with compression of the cavernous sinus along with cranial nerves located inside it), and blurring of vision. Ophthalmoscopically, the optic discs were pale pink at the fundus level with large cupping and denudation of the cribriform plate. Visual field examination 30-2 with a threshold stimulus showed left hemianopsia in the left eye and right quadrantanopsia in the right eye (fig. 1–4). After transsphenoidal resection of the pituitary tumor, the visual field improved significantly (visual field index of left eye 53% → 98% and right eye 93% → 97%), with a false positive and negative error rate of <10%. The glaucoma module of OCT was also performed, showing reduced values of the ganglion cell complex in the nasal sectors, as well as borderline values in the temporal quadrants of the peripapillary nerve fiber layer (fig. 5–8). The values were comparable in the period of 3 months following neurosurgical treatment.

A contrast-enhanced MRI of the head was performed, including one aimed at the pituitary gland. A hyperreflective mass was revealed in the sella turcica, with a diameter of 27 × 37 × 24 mm, which most likely corresponded to a pituitary macroadenoma (fig. 9). The lesion bulged suprasellarly, causing elevation, compression and thinning of the optic chiasm with shallowing of the anterior parts of the recesses of the third ventricle, and slightly protruded into the cavernous sinuses. The patient was urgently referred to the

in men over 50 years of age, it constitutes about ¼ of all macroadenomas. The diagnosis of a gonadotropin-secreting tumor is based on the visualization of a pituitary adenoma in computed tomography or magnetic resonance imaging of the head and the detection of increased levels of gonadotropins or their free subunits (α-SU, β-FSH or β-LH) in serum [18]. In cases of excessive FSH (follicle-stimulating hormone) secretion in men with other symptoms of hypopituitarism, erectile dysfunction is usually not observed, and testosterone and estradiol levels are within the normal range. Sometimes, due to low LH (luteinizing hormone) causing testosterone deficiency, weakness is observed in men, while in women, amenorrhea in the premenopausal period or cystic ovarian changes may be noted, and high estradiol levels are often inadequate for increased FSH levels. LH-secreting tumors are rare, therefore increased FSH levels with often undetectable low LH may suggest a gonadotropin-secreting tumor. This also facilitates differentiation from hypogonadism and menopause, in which the concentrations of both gonadotropins are increased, with a decrease in the level of gonadal hormones. In a gonadotropin tumor secreting FSH, the concentrations of gonadal hormones are rarely reduced. Diagnosis is facilitated by demonstrating a paradoxical increase in the concentrations of gonadotropins and α-SU after thyrotropin-releasing hormone stimulation, which is observed in half of the patients with a gonadotropin tumor.

The treatment of choice is transsphenoidal, if possible complete removal of the adenoma [19, 20]. Unfortunately, this

is not possible in some patients due to the significant evolution of the tumor. Therefore, it is necessary to decompress the optic chiasm and thus improve the field of vision and restore normal pituitary function, while in the case of its hypothyroidism – pharmacologically supplement the hormonal deficiencies. In cases of rapid tumor regrowth, radiotherapy or conservative treatment (dopamine drugs, e.g. bromocriptine or somatostatin analogues, e.g. octreotide) is recommended. In the case of our patient, the neurosurgical team decided not to undergo adjuvant therapy, but due to the removal of the entire pituitary gland, he was recommended lifelong hormonal supplementation. Initial treatment doses included hydrocortisone 20 mg in the morning and 10 mg at noon, desmopressin 30 µg in the morning and 60 µg in the evening (due to symptoms of diabetes insipidus), and levothyroxine 50 µg in the morning.

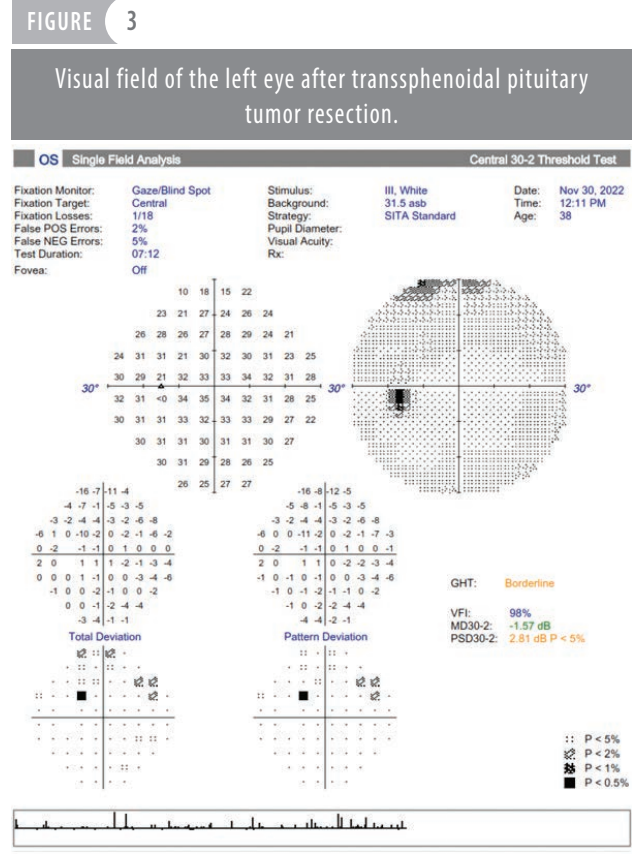
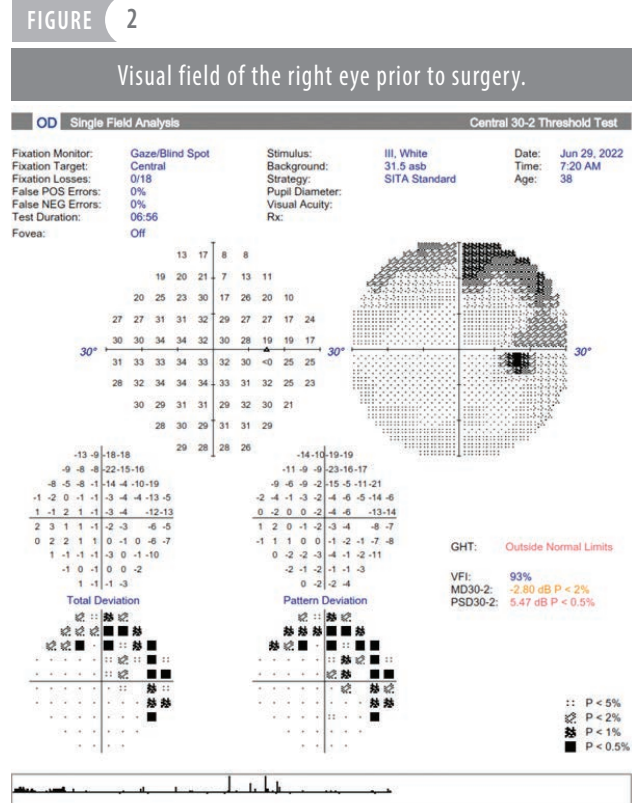
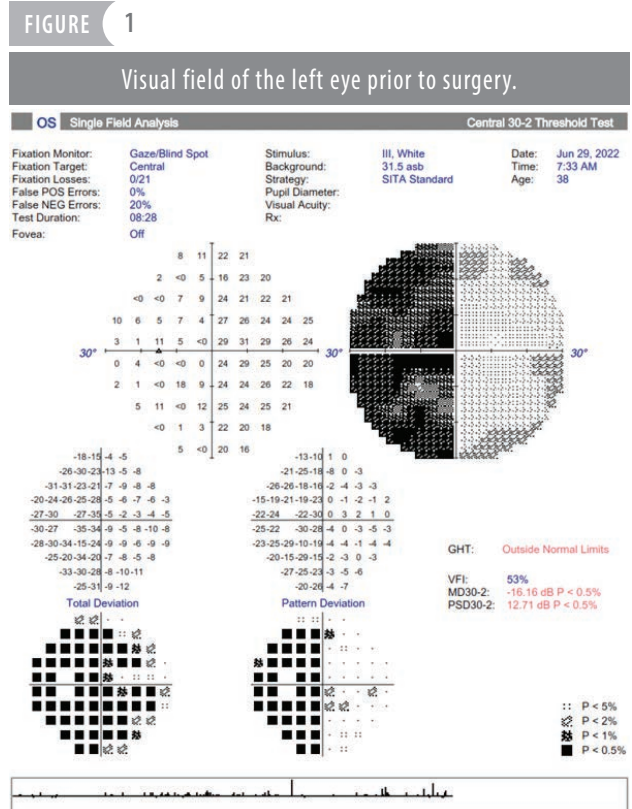


FIGURE 4

Visual field of the right eye after transphenoidal pituitary tumor resection.

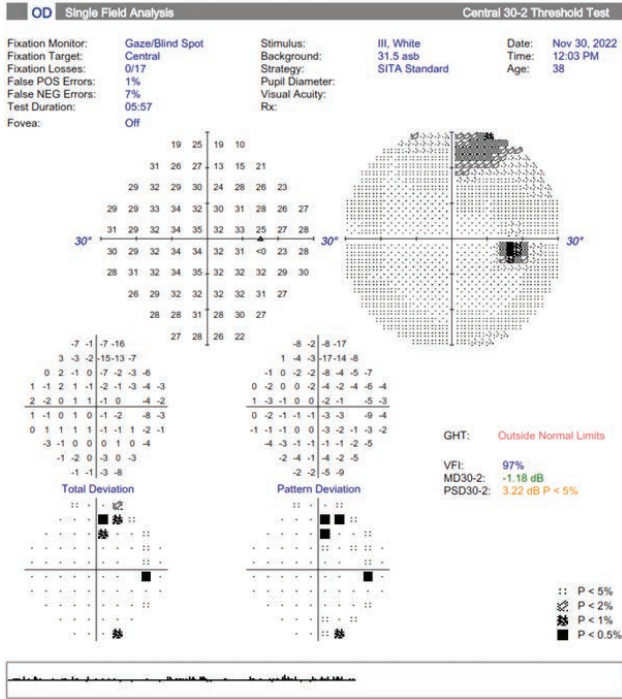


FIGURE 5

Ganglion cell layer in the left eye analyzed on optical coherence tomography with the device Heidelberg Spectralis.

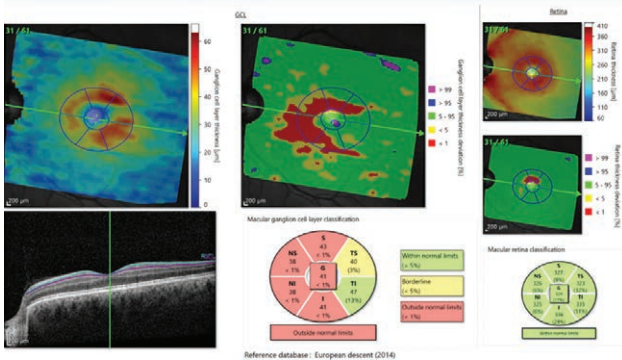


FIGURE 6

Ganglion cell layer in the right eye analyzed on optical coherence tomography with the device Heidelberg Spectralis.

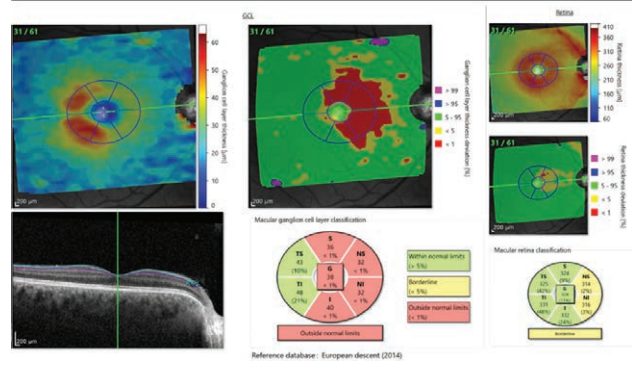


FIGURE 7

Retinal nerve fiber layer in the left eye analyzed on optical coherence tomography with the device Heidelberg Spectralis.

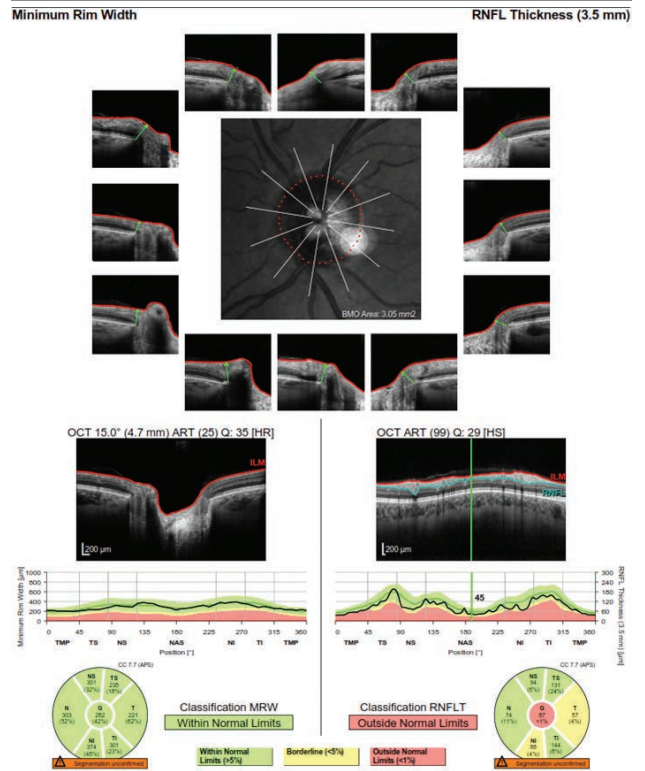


FIGURE 8

Retinal nerve fiber layer in the right eye analyzed on optical coherence tomography with the device Heidelberg Spectralis.

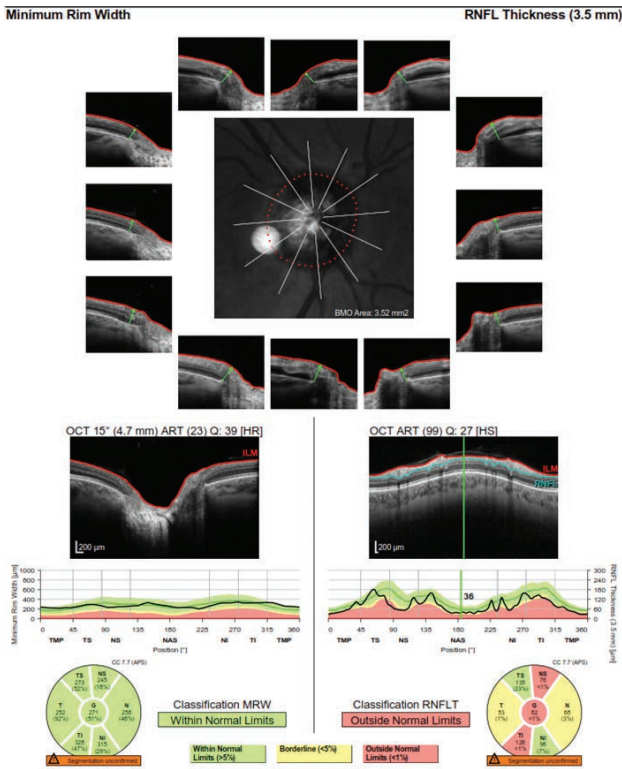
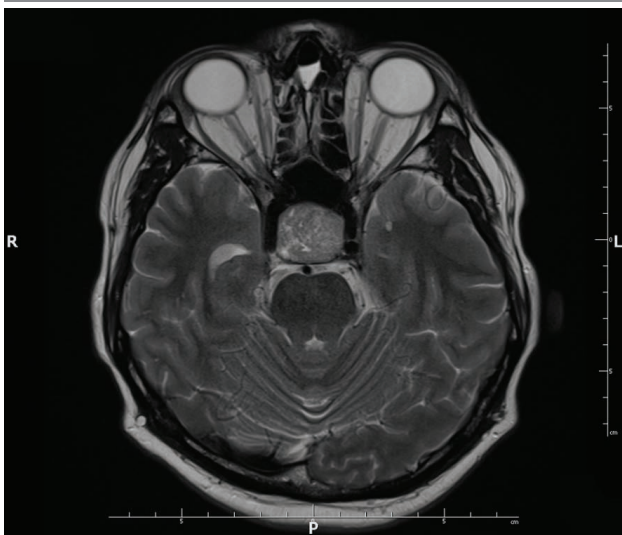


FIGURE 9

Axial T2-weighted scan on magnetic resonance imaging with contrast, visualizing the pituitary tumor.



CONCLUSION

Subjectively noticeable visual field defects, often preceded by non-specific headaches and weakness, may be a sign of a proliferative process in the brain. The area of visual impairment allows us to suspect at which stage of the visual pathway the signal transmission was blocked, which should be confirmed by imaging tests of the head. Visual field defects not exceeding the horizontal meridian and covering both upper or lower quadrants (altitudinal scotomas) most often suggest damage due to compression of retinal neurons in the mechanism of high intraocular pressure (may not be detected at the visit in the case of periodic jumps in this pressure characteristic of pigmentary or pseudo-exfoliative glaucoma) or ischemia caused, for example, by significant restriction of flow in the internal carotid arteries or disturbed blood rheology. Unfortunately, as long as the pressure on the nerve fibers of the visual pathway is not strong, it will not cause deviations in the confrontational visual field test, and in perimetry the defects may also remain unnoticed at that point. Therefore, in relation to pituitary macroadenoma, a thorough history should be taken for systemic disorders of hormonally active tumors. Important clues will also be provided by a thorough ophthalmoscopic assessment of the optic nerve disc and correlation with OCT examination. In assessing the prognosis of the disease, attention should be paid to the thickness of the peripapillary nerve fibers, especially if it is $\geq 60 \mu\text{m}$ in the temporal quadrant and $\geq 105 \mu\text{m}$ in the inferior quadrant, a correlation has been shown between VFI improvement to $>90\%$ and best corrected visual acuity above 20/25 in the postoperative period [21]. However, even with such good treatment effects, it is important to monitor patients for at least 5 years after surgical removal of the tumor due to recurrences, which occur in the case of acute resection in up to $\frac{1}{3}$ of cases, after adjuvant radiotherapy this percentage is slightly lower (approximately 10%).

CORRESPONDENCE**Grzegorz Rotuski, MD**Ophthalmology Clinic, Military Institute of Aviation Medicine
01-755 Warszawa, ul. Zygmunta Krasińskiego 54/56
e-mail: rrotus@hotmail.com**ORCID**Grzegorz Rotuski – ID – <https://orcid.org/0000-0002-4640-8787>Jaromir Wasyluk – ID – <http://orcid.org/0000-0002-0080-6050>Radosław Różycki – ID – <http://orcid.org/0000-0001-7040-026X>**References**

1. Kono M, Goletz PW, Crouch RK. 11-cis- and all-trans-retinols can activate rod opsin: rational design of the visual cycle. *Biochemistry*. 2008; 47(28): 7567-71. <http://doi.org/10.1021/bi800357b>.
2. Nelson R, Connaughton V. Bipolar Cell Pathways in the Vertebrate Retina. In: *Webvision: The Organization of the Retina and Visual System*. Kolb H, Fernandez E, Nelson R (eds.). University of Utah Health Sciences Center, Salt Lake City 1995. <https://www.ncbi.nlm.nih.gov/books/NBK11521/>.
3. Prasad S. Retrochiasmal Disorders. In: Liu, Volpe, and Galetta's *Neuro-Ophthalmology: Diagnosis and Management*, 3rd ed. Liu GT, Volpe NJ, Galetta SL (eds.). Elsevier Inc., Edinburgh 2019: 293-339.
4. Kamali A, Hasan KM, Adapa P et al. Distinguishing and quantification of the human visual pathways using high-spatial-resolution diffusion tensor tractography. *Magn Reson Imaging*. 2014; 32(7): 796-803. <https://doi.org/10.1016/j.mri.2014.04.002>.
5. Vanni S, Tanskanen T, Seppä M et al. Coinciding early activation of the human primary visual cortex and anteromedial cuneus. *Proc Natl Acad Sci USA*. 2001; 98: 2776-80.
6. Cho J, Liao E, Trobe JD. Visual Field Defect Patterns Associated With Lesions of the Retrochiasmal Visual Pathway. *J Neuroophthalmol*. 2022; 42(3): 353-9. <http://doi.org/10.1097/WNO.0000000000001601>.
7. Becker-Bense S, Buchholz HG, zu Eulenburg P et al. Ventral and dorsal streams processing visual motion perception (FDG-PET study). *BMC Neurosci*. 2012; 13: 81. <https://doi.org/10.1186/1471-2202-13-81>.
8. Miller AM, Obermeyer WH, Behan M et al. The superior colliculus–pretectum mediates the direct effects of light on sleep. *Proc Natl Acad Sci USA*. 1998; 95: 8957-62. <http://doi.org/10.1073/pnas.95.15.8957>.
9. Kozicz T, Bittencourt JC, May PJ et al. The Edinger-Westphal nucleus: A historical, structural, and functional perspective on a dichotomous terminology. *J Comp Neurol*. 2011; 519: 1413-34. <https://doi.org/10.1002/cne.22580>.
10. Hillis AE, Wityk RJ, Barker PB et al. Subcortical aphasia and neglect in acute stroke: the role of cortical hypoperfusion. *Brain*. 2002; 125(5): 1094-104. <https://doi.org/10.1093/brain/awf113>.
11. Monga S. Perimetry in Neurological Disorders. In: *Resolving Dilemmas in Perimetry*. Patyal S, Gandhi M. (eds.). Springer, Singapore 2021. https://doi.org/10.1007/978-981-16-2601-2_11.
12. Swinton DJ, Thomas AG. The Visual Pathway – Functional Anatomy and Pathology. *Semin Ultrasound CT MR*. 2014; 35(5): 487-503. <https://doi.org/10.1053/j.sult.2014.06.007>.
13. Farrash FA, Hassounah M, Helmi HA et al. Rathke's cleft cyst presentation mimicking craniopharyngioma: Case report. *Int J Surg Case Rep*. 2020; 68: 104-6. <https://doi.org/10.1016/j.ijscr.2020.01.035>.
14. Lake MG, Krook LS, Cruz SV. Pituitary adenomas: an overview. *Am Fam Physician*. 2013; 88(5): 319-27.
15. Matuszek B, Nowakowski A, Paszkowski T et al. Gonadotropinoma in the menopausal period: practical guidelines. *Menopause Review/Przegląd Menopauzalny*. 2012; 11(3): 183-6.
16. Andino-Ríos GG, Portocarrero-Ortiz L, Rojas-Guerrero C et al. Nonfunctioning Pituitary Adenoma That Changed to a Functional Gonadotropinoma. *Case Rep Endocrinol*. 2018; 2018: 5027859. <https://doi.org/10.1155/2018/5027859>.
17. Thakkar A, Kannan S, Hamrahan A et al. Testicular "hyperstimulation" syndrome: a case of functional gonadotropinoma. *Case Rep Endocrinol*. 2014; 2014: 194716. <https://doi.org/10.1155/2014/194716>.
18. Oommen S, Rice S. Case Report: Atypical presentation of non-functional gonadotropinoma. *F1000Res*. 2023; 12: 674. <http://doi.org/10.12688/f1000research.133438.1>.
19. Prete A, Corsello SM, Salvatori R. Current best practice in the management of patients after pituitary surgery. *Ther Adv Endocrinol Metab*. 2017; 8(3): 33-48. <http://doi.org/10.1177/2042018816687240>.
20. Cote DJ, Smith TR, Sandler CN et al. Functional Gonadotroph Adenomas: Case Series and Report of Literature. *Neurosurgery*. 2016; 79(6): 823-31. <http://doi.org/10.1227/NEU.0000000000001188>.
21. Thammakumpee K, Buddawong J, Vanikieti K et al. Preoperative Peripapillary Retinal Nerve Fiber Layer Thickness as the Prognostic Factor of Postoperative Visual Functions After Endoscopic Transsphenoidal Surgery for Pituitary Adenoma. *Clin Ophthalmol*. 2022; 16: 4191-8. <http://doi.org/10.2147/OPTH.S392987>.

Authors' contributions:

Grzegorz Rotuski – conceptualization, methodology, formal analysis, investigation, resources, original draft preparation, review and editing of the manuscript, visualization, project administration.

Jaromir Wasyluk – conceptualization, methodology, formal analysis, investigation, original draft preparation, review and editing of the manuscript, supervision.

Radosław Różycki – conceptualization, Investigation, original draft preparation, review and editing of the manuscript, supervision.

Conflict of interest:

None.

Financial support:

None.

Ethics:

The content presented in the article complies with the principles of the Helsinki Declaration, EU directives and harmonized requirements for biomedical journals.