

Nodular posterior scleritis with recurrence in contralateral eye – case report



Paulina Siwik, Tomasz Chudoba, Joanna Sempirska-Szewczyk

Department of Ophthalmology, National Medical Institute of the Ministry of the Interior and Administration, Warsaw
Head: Joanna Sempirska-Szewczyk, MD, PhD

HIGHLIGHTS

Given the diagnostic challenge of nodular posterior scleritis and its potential to mimic intraocular tumors, the study underscores the importance of imaging techniques and steroid responsiveness in distinguishing inflammatory conditions from malignancies.

ABSTRACT

Posterior scleritis is a rare, in 80% idiopathic disorder. It can be divided into 2 subtypes: diffuse and nodular. The aim of this study is to report clinical, imaging findings, differential diagnosis and treatment, of a patient with nodular posterior scleritis.

A 45-year-old woman was diagnosed as recurrence of nodular posterior scleritis, after extensive examination. At admission best corrected visual acuity was 20/20 in her left eye. Fundus examination revealed an amelanotic yellowish subretinal mass under the superior nasal arcade, associated with subretinal fluid surrounding it. B-scan ultrasonography, optical coherence tomography findings confirmed the diagnosis. The patient was treated with intravenous steroids for 3 days, followed by oral in tapered dose over 3 weeks. After 7 weeks follow-up subretinal mass totally regressed. The diagnosis of nodular posterior scleritis may provide diagnostic dilemma. Multimodal imaging may be helpful in differential diagnosis. Majority of cases have an excellent prognosis with no recurrence.

Key words: nodular posterior scleritis, posterior scleritis, choroidal mass, exudative retinal detachment, pseudomelanoma, melanotic melanoma

INTRODUCTION

Posterior scleritis (PS) is a rare, and easily overlooked inflammatory disease that concern the sclera located behind the ora serrata [1]. It affects women twice as often as men, with a prevalence of 6 cases per 100,000 persons and mean age of 49.3 years [1, 2]. The disease is 80% idiopathic, although 20% of cases are associated with systemic diseases [1]. PS can be divided into 2 subtypes: diffuse and nodular [3, 4].

We described an extremely rare case, and simultaneously big diagnostic challenge of a patient with idiopathic nodular posterior scleritis (NPS), with multiple recurrence, including contralateral eye in 5-year observation, as well as positive 2-tiered serological exam for *Borrelia burgdorferi* infection.

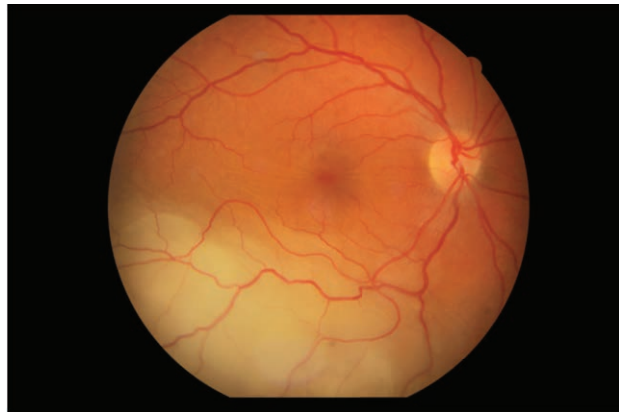
CASE REPORT

A 45-year-old woman, presented to the ophthalmology department with severe headache, mild left periocular pain, and diminution of vision in her left eye for 6 days. Her medical history included class III obesity, autoimmune thyroiditis with euthyrosis, insulin resistance, hypertension and fatty liver. Family history was unremarkable. 5 years earlier she was diagnosed with right eye NPS, and the diagnose was made in the reference ocular oncology department in Krakow, due to specific T-sign on ultrasound examination, and other presenting symptoms typical for PS. During the last episode an extensive secondary exudative retinal detachment was observed, and after exclusion of neoplasm she was admitted to our hospital for treatment. At that time she was complaining about severe headache, right-sided periocular pain, right eyelid swelling and subjective decreased vision. She had best corrected visual acuity (BCVA) 5/5,5 in the right eye and 5/5 in the left eye. Anterior segment examination of the right eye did not revealed any signs of inflammation. Fundus findings comprehend irregular choroidal thickening near the inferior temporal arcade, associated with yellowish lesion, and overlying detached retina, with subretinal fluid in the area of lesion, inferior retina extending up to macula (fig. 1). These findings was easily confirmed in OCT (optical coherence tomography) image.

In computed tomography of the eye, thickening of the posterolateral right eye wall was observed. Blood workup for autoimmune markers revealed slightly elevated antinuclear antibodies (ANA screen), and significantly elevated antithyroid antibodies (ATPO, ATG). Infectious causes were negative, except elevated IgM antibodies for *Borrelia burgdorferi* pathogen, with normal level of IgG antibodies. She was treated with four doses of 1 g intravenous methylprednisolone, followed by tapered oral steroids for 6 weeks, and after positive IgM Western-Blot test oral doxycycline

FIGURE 1

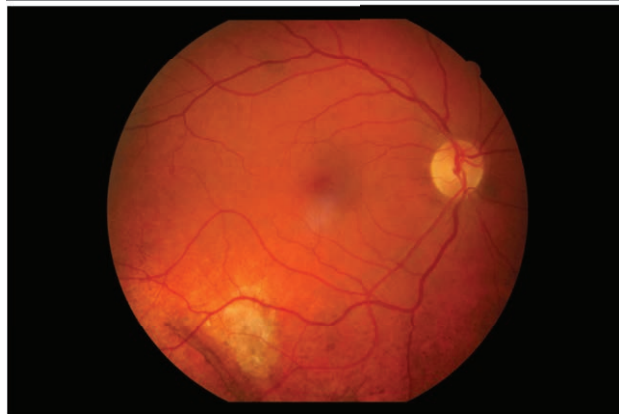
Colour fundus photograph of elevated solitary subretinal lesion in the right eye.



for 14 days was added to the therapy. On the follow-up the mass regressed completely, and the subretinal fluid disappeared, with retinal pigment epithelium atrophy and subretinal scars as the remnant of inflammation (fig. 2).

FIGURE 2

Colour fundus photograph of subretinal scar in the right eye.



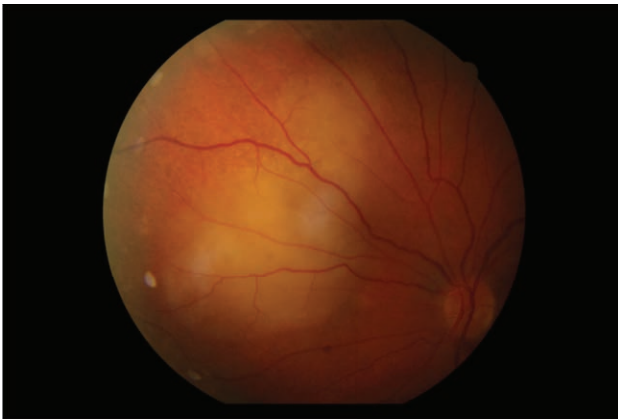Similar symptoms, but less severe, reappeared 3 years later in the same eye, and nearby localization, without any systemic complaints indicated Lyme disease. The patient was treated with oral steroids for 1,5 month, with complete recovery.

In current episode of scleral inflammation her complains involved the left eye. The BCVA was 5/5 in both eyes, and the intraocular pressure measurement was also within normal limits. Extraocular motility was full in all cardinal gazes, and no proptosis was present. The results of a slit-lamp examination of both eyes were within normal limits, and there were no signs of inflammation in anterior chamber, or vitreous. Fundus inspection of the right eye revealed retinal pigment epithelium atrophy with a white scar under the inferior-tem-

poral vascular arcades near the equator corresponding, with previous extent of disease. Clinical findings in the left eye included large, dome-shaped, yellowish, non-pigmented subretinal lesion in the posterior pole covering an area within the nasal arcades with an accumulation of subretinal fluid, and chorioretinal folds (fig. 3).

FIGURE 3

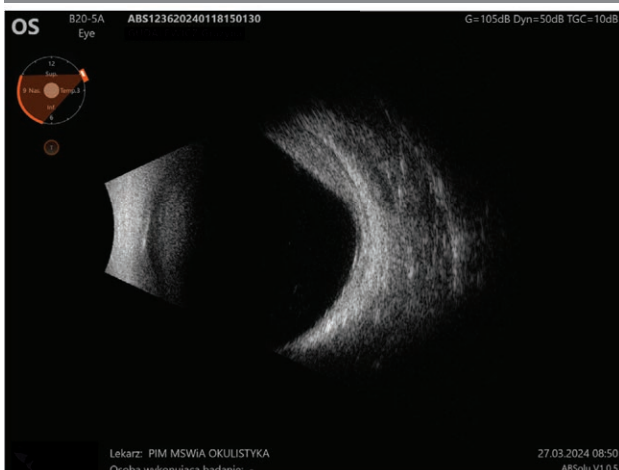
Colour fundus photograph of yellowish, non-pigmented subretinal lesion in the left eye.



Shallow exudative retinal detachment with shifting fluid on periphery and peripapillary area was observed. Diagnostic B-scan ultrasonography revealed a homogenous, medium hyperreflectivity mass lesion with thickened adjacent sclera and minor amount of fluid collection in the sub-Tenon space (fig. 4).

FIGURE 4

Ultrasonography transverse B-mode image of homogenous mass lesion, with thickened adjacent sclera, and minor amount of fluid collection in the sub-Tenon space.



However, no definitive T sign was noted. The nodule measured 10.56 mm in the largest basal diameter, and 3.19 mm in elevation. Shallow exudative detachment was observed inferiorly. Optical coherence tomography examination revealed multifocal retinal detachment, with increased choroidal thickening, and mass adjacent to the choroid modelling retinal outer surface. The initial workup comprised of a detailed uveitis examination was repeated, with negative results for autoimmune serological screening, except for slightly elevated ANA screen. Likewise, HLA-B27 testing was negative. Performed radiological tests included chest X-ray, sacroiliac joint X-ray produced unremarkable results.

Pulse steroid therapy was initiated with a start dose of 1 g intravenous methylprednisolone for 3 days, followed by oral prednisolone 60 mg once daily, tapered over 3 weeks due to uncontrolled glucose levels, obesity and restrictions during preparing procedure for bariatric therapy. On 7 weeks follow up the choroidal lesion distinctively flattened and subretinal fluid has reabsorbed (fig. 5).

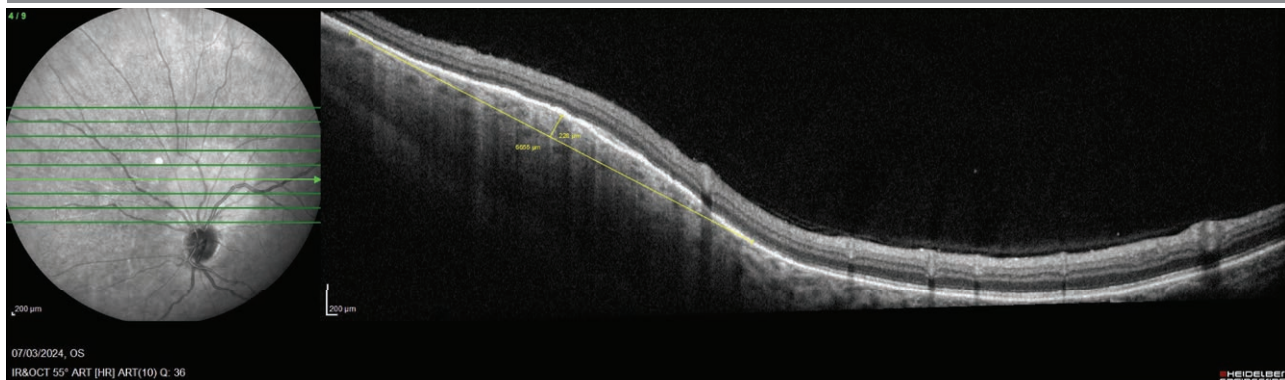
DISCUSSION

NPS most often results in an amelanotic subretinal orange mass lesion, with normal choroidal vascular pattern, overlying subretinal fluid and chorioretinal folds or striae usually surrounding the mass [1]. Other clinical findings may include a macular oedema, papilloedema, elevated intraocular pressure, annular choroidal detachment [1]. It can be also asymptomatic, and easily under-recognized. Typically, patients report the sudden onset of unilateral periocular pain, and severe headache [1]. It is often accompanied by decreased visual acuity, anterior scleritis, binocular diplopia, pain with the eye movement [1].

That condition is included to a group of pseudomelanomas and 0.3–1.5% of patients suspected with malignancy actually has NPS [2]. The differential diagnosis of an amelanotic subretinal mass includes amelanotic choroidal melanoma, choroidal hemangioma, choroidal metastasis, choroidal osteoma, choroidal lymphoma and choroidal granuloma [5, 6]. Currently there is no univocal prove of association with any genetic haplotype [7]. Autoimmune condition related to PS is mainly rheumatoid arthritis. Among other immunological disease only one report describes association of unilateral NPS with Lyme disease [1, 8]. In our case we performed 2-tiered serology exam toward *Borrelia burgdorferi* infection consequently receiving positive results in both steps only in IgM. However it should be taken into consideration that foregoing findings do not necessarily imply an active infection and may result from cross-reactions between Lyme disease serological tests and nuclear antibodies or previous exposure with its high prevalence in endemic area [9, 10]. The isolated positive IgM outcome without seroconversion after 6 weeks, should encourage a differential diagnosis [10].

FIGURE 5

Spectral-domain OCT at 7-week follow-up demonstrates marked flattening of the choroidal lesion with complete reabsorption of subretinal fluid.



The deceitful of Western Blot IgM test evaluation consists of manual interpretation and requires only 2 bands as positive result and the prevalence of false-positive vary from 27.5% to 53.3% [10]. Furthermore, our patient didn't have any symptoms and signs which could be related to Lyme disease except of posterior scleritis. In addition we performed laboratory tests 2 months after first complaints. At that point seroconversion should be achieved. Despite the patient received first line antibiotic treatment we observed relapse twice over. B-scan ultrasonography is a mainstay of diagnosis a NPS and plays a crucial role in the differentiating process [3, 11]. The presence of high reflectivity lesion, oedema in the Tenon capsule (T-sign) due to a thickened sclera, enlargement of optic nerve shadow, subretinal fluid without orbital shadowing strongly indicated NPS [2, 3, 11, 12]. There are no formal guidelines on the diagnostic criteria for the thickening of the sclera, but in the available literature it is assessed to be 2.5 mm [11].

Magnetic resonance imaging (MRI) is the most useful ancillary test to diversify choroidal melanoma from other choroidal tumors [2].

OCT can not itself provide a diagnosis of NPS because of lack of any typical model but can be a valuable tool to support the examination protocol and monitoring the treatment [3].

Fluorescence angiography is also a useful examination in assessment approach which can establish identification of individual neoplasm but it should be kept in mind that pin points leakage is not a distinctive sign as a consequence of its prevalence in choroidal granuloma, melanoma and NPS [2, 12].

In some circumstances when facing diagnostic difficulties biopsy can be performed but it should be considered with caution [3].

PS has favourable response for glucocorticosteroids and for that reason therapeutic trial is advised when an issue with disorder identification appear [3].

Corticotherapy is the mainstay of treatment but the aggressiveness of the therapy vary between the reports [2, 3, 12, 13]. Immunomodulatory drugs are also used usually as a steroid-sparing agent including methotrexate, azathioprine, mycophenolate mofetil, cyclophosphamide, cyclosporin [3, 13]. Even though it is potentially sight threatening condition, visual outcomes are favourable and there were reported very few cases in one series which lead to permanent significant visual impairment in all group of PS [1].

Recurrences of NPS are very rare and we have found only 2 case reports [4, 5, 14]. Single study of whole PS group suggest correlation between relapse and quick taper of treatment and recommended to maintain in recurrence cases 6 month to 1 year low-dose steroids or immunosuppressives to avoid that complication [14]. In the other hand in a major review on both subtypes of PS there was a conclusion that intravenous pulse of methylprednisolone prevents recurrence [1].

CONCLUSION

NPS is an uncommon potential sight-threatening disease which should be distinguished from intraocular choroidal tumors. The lack of characteristic complaints and possibility of asymptomatic cases can lead to misdiagnosis. Furthermore NPS can be easily overlooked. Periocular pain associated with anterior scleritis, exudative retinal detachment and rarely a papilloedema are suggestive of an inflammatory disorder [12]. We recommend multimodal imaging including ultrasonography and MRI as a mainstay of diagnosis. Also in that report we emphasize the role of ancillary test such as OCT and FA to support the diagnosis and therapy monitoring. When the diagnostic dilemma appears it should be considered administrating steroids due to spectacular respond. Majority of cases have an excellent prognosis with no recurrence.

Figures: from authors' own materials.

CORRESPONDENCE

Paulina Siwik, MD

Department of Ophthalmology, National Medical Institute
of the Ministry of the Interior and Administration
02-507 Warszawa, ul. Wołoska 137
e-mail: paulina.siwik@cskmswia.gov.pl

ORCID

Paulina Siwik – ID – <http://orcid.org/0009-0001-6690-8711>

References

1. McCluskey PJ, Watson PG, Lightman S et al. Posterior scleritis: clinical features, systemic associations, and outcome in a large series of patients. *Ophthalmology*. 1999; 106(12): 2380-86. [http://doi.org/10.1016/S0161-6420\(99\)90543-2](http://doi.org/10.1016/S0161-6420(99)90543-2).
2. Babu N, Kumar K, Upadhayay A et al. Nodular posterior scleritis – The great masquerader. *Taiwan J Ophthalmol*. 2021; 11(4): 408. http://doi.org/10.4103/tjo.tjo_20_21.
3. Khadka S, Byanju R, Pradhan S. Posterior Scleritis Simulating Choroidal Melanoma: A Case Report. *Beyoglu Eye J*. 2021; 6(2): 133-9. <http://doi.org/10.14744/bej.2021.56338>.
4. Ozkaya A, Alagoz C, Koc A et al. A case of nodular posterior scleritis mimicking choroidal mass. *Saudi J Ophthalmol*. 2015; 29(2): 165-8. <http://doi.org/10.1016/j.sjopt.2014.06.012>.
5. Agrawal R, Lavric A, Restori M et al. NODULAR POSTERIOR SCLERITIS: Clinico-Sonographic Characteristics and Proposed Diagnostic Criteria. *Retina*. 2016; 36(2): 392-401. <http://doi.org/10.1097/IAE.0000000000000699>.
6. Ally N, Makgotloe A. Nodular Posterior Scleritis Masquerading as a Subretinal Mass. *Middle East Afr J Ophthalmol*. 2021; 27(4): 231-4. http://doi.org/10.4103/meajo.MEAJO_216_19.
7. Anshu A, Chee SP. Posterior scleritis and its association with HLA B27 haplotype. *Ophthalmologica*. 2007; 221(4): 275-8. <http://doi.org/10.1159/000101931>.
8. Krist D, Wenkel H. Posterior scleritis associated with *Borrelia burgdorferi* (Lyme disease) infection. *Ophthalmology*. 2002; 109(1): 143-5. [http://doi.org/10.1016/s0161-6420\(01\)00868-5](http://doi.org/10.1016/s0161-6420(01)00868-5).
9. Grażewska W, Holec-Gąsior L. Antibody Cross-Reactivity in Serodiagnosis of Lyme Disease. *Antibodies (Basel)*. 2023; 12(4): 63. <http://doi.org/10.3390/antib12040063>.
10. John TM, Taeye AJ. Appropriate laboratory testing in Lyme disease. *Cleve Clin J Med*. 2019; 86(11): 751-9. <http://doi.org/10.3949/ccjm.86a.19029>.
11. Maleki A, Ruggeri M, Colombo A et al. B-Scan Ultrasonography Findings in Unilateral Posterior Scleritis. *J Curr Ophthalmol*. 2022; 34(1): 93-9. http://doi.org/10.4103/joco.joco_267_21.
12. Hage R, Jean-Charles A, Guyomarch J et al. Nodular posterior scleritis mimicking choroidal metastasis: a report of two cases. *Clin Ophthalmol*. 2011; 5: 877-80. <http://doi.org/10.2147/OPHT.S21255>.
13. Dutta Majumder P, Agrawal R, McCluskey P et al. Current Approach for the Diagnosis and Management of Noninfective Scleritis. *Asia Pac J Ophthalmol (Phila)*. 2020; 10(2): 212-23. <http://doi.org/10.1097/APO.0000000000000341>.
14. Horo S, Sudharshan S, Biswas J. Recurrent posterior scleritis—report of a case. *Ocul Immunol Inflamm*. 2006; 14(1): 51-6. <http://doi.org/10.1080/09273940500323462>.

Authors' contributions:

Paulina Siwik – concept and design of the analysis, data collection, data contribution, execution of the analysis, writing of the article, graphic design.

Tomasz Chudoba – critical review for important intellectual content, final approval of print version.

Joanna Sempirńska-Szewczyk – critical review for important intellectual content, final approval of print version.

Conflict of interest:

None.

Financial support:

None.

Ethics:

The content presented in the article complies with the principles of the Helsinki Declaration, EU directives and harmonized requirements for biomedical journals.