


Management of trauma-induced anterior necrotizing scleritis in a high-risk occupational setting: resolution with temporary tarsorrhaphy



Ahmad Kunbaz¹, Omer Faruk Yilmaz², Halit Oguz^{1,2}

¹ Istanbul Medeniyet University, Faculty of Medicine, Department of Ophthalmology, Istanbul, Turkey
Head: Prof. Dr. Halit Oguz

² Department of Ophthalmology, Goztepe Prof. Dr. Süleyman Yalçın City Hospital, Istanbul, Turkey
Head: Prof. Dr. Halit Oguz

HIGHLIGHTS

Trauma-induced anterior necrotizing scleritis (ANS) secondary to intraocular foreign body exposure in a welder represents a rare but vision-threatening complication.

ABSTRACT

Objective: This case report highlights the challenges and innovative treatment approaches for managing trauma-induced anterior necrotizing scleritis (ANS), particularly in high-risk occupational settings, such as welding.

Methods: We present the case of a 44-year-old male welder who suffered a metal particle injury in his right eye, leading to ANS. Initial treatments included removal of the foreign body, suturing of the conjunctival tear, and administration of antibiotics and hydrating eye drops. Subsequent treatments for the ensuing ANS included systemic and topical steroids, cyclosporine drops, oral prednisone, vitamin C supplements, dura and amniotic membrane grafting, and autologous serum eye drops. Following the failure of these interventions, a temporary tarsorrhaphy surgery was performed.

Results: Despite the application of various conventional therapies, the patient's condition did not improve significantly until temporary tarsorrhaphy was performed. This intervention, along with an intensive therapeutic regimen, led to the complete healing of the sclera and improved visual acuity.

Conclusion: This case underscores the complexity of treating ANS, especially in cases resistant to standard treatment modalities. The successful use of temporary tarsorrhaphy in conjunction with other treatments highlights the need for an individualized approach to manage such conditions. This case contributes to the growing body of evidence suggesting the potential benefits of revisiting traditional surgical interventions for treating refractory cases of ANS.

Key words: anterior necrotizing scleritis, ocular trauma, welding, tarsorrhaphy, ophthalmology

INTRODUCTION

Ocular injuries remain a major cause of visual impairment and contribute to >12% of work-related traumas [1]. Welders, in particular, face heightened risks due to sustained exposure to metals and ultraviolet (UV) radiation, with reported ocular injuries constituting between 21% and 48% of the overall occupational hazards [2–4]. Arc welding potentially leads to photokeratitis, corneal abrasion, and intraocular foreign body (IOFB) implantation [5]. Predominantly, metallic IOFBs represent a significant morbidity factor among younger patients [6, 7]. Iron-based IOFBs pose a threat of endophthalmitis and scleral melting, known as necrotizing scleritis [7–9].

Anterior necrotizing scleritis (ANS), an aggressive form of scleritis, can manifest post-trauma, postoperatively, secondary to infections, or in conjunction with rheumatological conditions such as rheumatoid arthritis. It is characterized by insidious onset of severe ocular pain and redness. Its management is complex, as healing often demands the removal of necrotic tissue and its overlying conjunctiva,

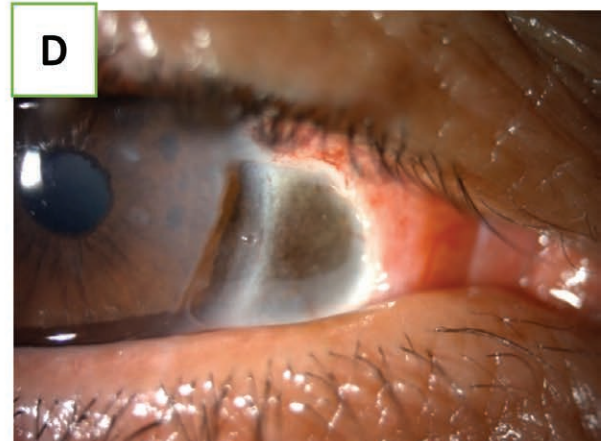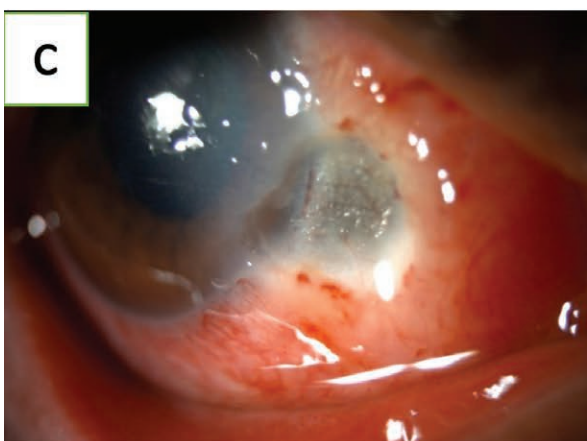
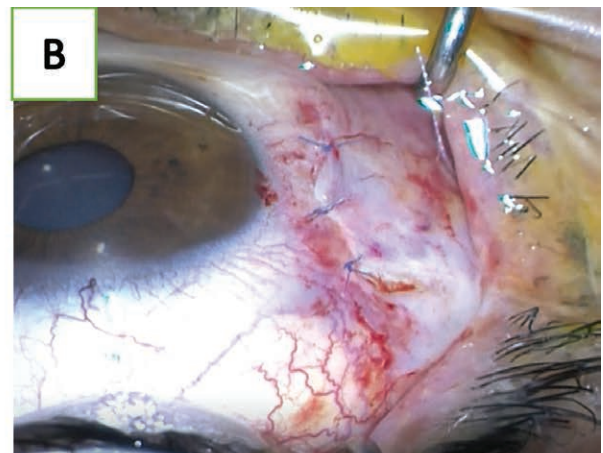
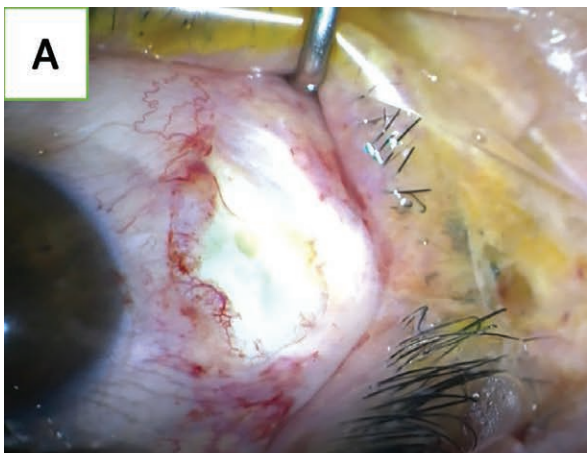raising concerns about epithelialization deficits and the subsequent necessity for grafting. A wide range of therapeutic protocols, from systemic steroids and topical treatments to biological agents and grafts using the periosteum, dura mater, or amniotic membrane, have been explored; however [9–13], no gold standard treatment has been presented for these cases [14]. In this context, we present a case of trauma-induced ANS that was uniquely resistant to conventional interventions, but responsive to an innovative approach.

CASE PRESENTATION

A 44-year-old male was referred to our clinic with the complaint of a metal particle entering his right eye during welding. On presentation to our clinic, his visual acuity was 0.16/1.0, with an intraocular pressure of 18/16 mmHg. In the slit lamp examination, in addition to the conjunctival foreign body, a 6 mm vertical conjunctival tear adjacent to the limbus at the nasal end was detected (fig. 1A). Complete corneal abrasion was noted, although the sclera remained

FIGURE 1

A. Conjunctival vertical tearing before operation. B. Primary suturing of conjunctival tear using 8-0 vicryl sutures. C. Necrotizing sclera and exposed uveal tissue. D. Enlarged sclera melting and exposed uveal tissue despite treatment.



intact. An immediate intervention was sought. Under local anesthesia, the foreign body was removed and the conjunctival incision was sutured using an 8-0 vicryl suture (fig. 1B). The postoperative regimen included antibiotics and hydrating eye drops. One week later, a bluish discoloration was detected in the perilimbal sclera of the right eye. In the trauma area, the sclera was completely dissolved up to the limbus, and uveal tissues were visible. The clinical findings were consistent with those of anterior necrotizing scleritis (fig. 1C). Alongside previous therapy, systemic and topical steroids were initiated. However, within 2 days, significant progression of the necrotic area was observed (fig. 1D). Given the aggressive nature of the disease, an additional surgical intervention was planned. The dura and amniotic grafts were sutured over the affected area using 10-0 nylon sutures (fig. 2A). The postoperative regimen was intensified with autologous serum eye drops 4 times daily, steroid and antibiotic eye drops 4 times daily, cyclosporine drops 2 times daily, oral prednisone 16 mg/24 h, and a daily vitamin C supplement. A compressive bandage was advised for additional

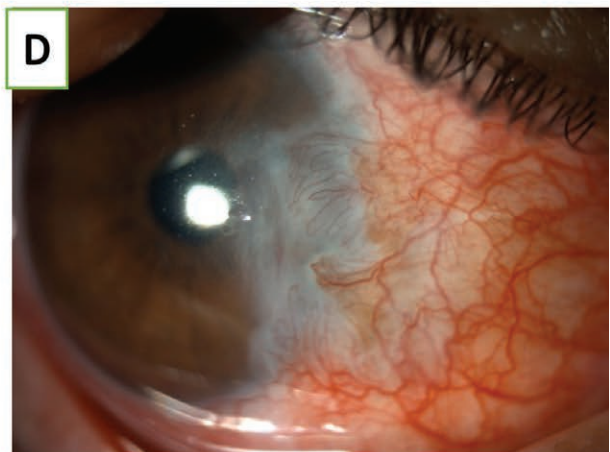
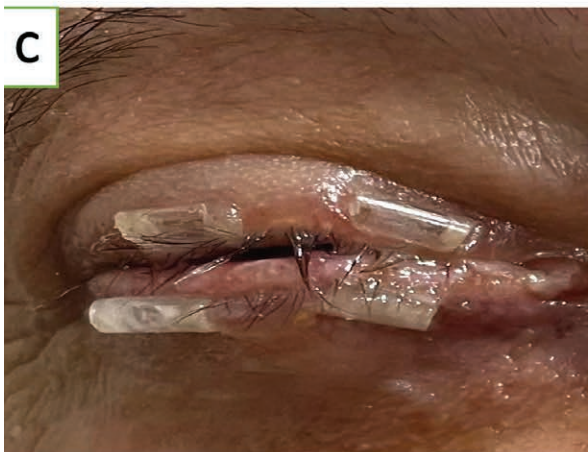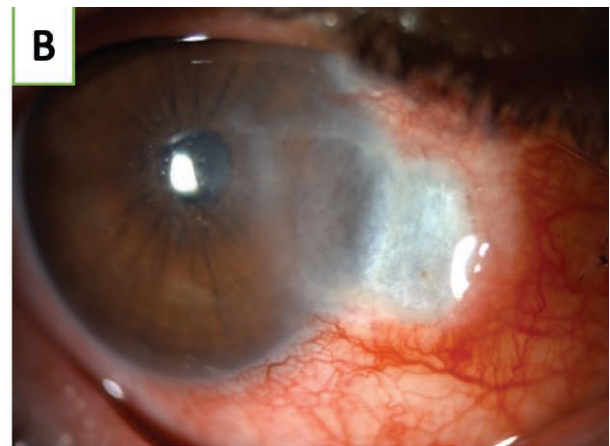
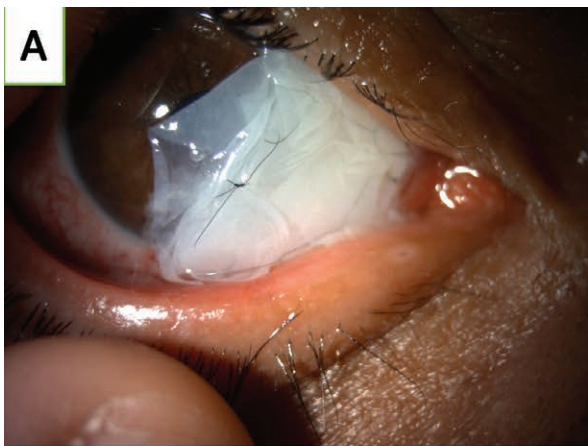support. After 1 week, the dura and amniotic membranes had fallen off. Despite all treatments, scleritis persisted for 2 weeks postoperatively (fig. 2B). Eyelid movement delayed healing of necrotizing scleritis. Urgent temporary tarsorrhaphy surgery was performed under local anesthesia. After the treatment, the same intensive therapeutic regimen was continued (fig. 2C). Miraculously, 2 weeks later, the sclera exhibited complete healing and the tarsorrhaphy was released. The latest evaluation showed a visual acuity of 0.8/1.0, a fully healed sclera, and vascularized nasal conjunctiva (fig. 2D).

DISCUSSION

In our case, following the failure of other treatment modalities, trauma induced ANS healed with tarsorrhaphy application in conjunction with topical treatment. Injuries associated with welding, as highlighted in this case, underscore the multifaceted challenges of ocular trauma in high-risk professionals. A recent study between 2010–2019 in the United States regarding ocular injuries related to the usage

FIGURE 2

A. Dura and amniotic membrane grafting over the injured area. B. Persistent necrotizing scleritis. C. Temporary tarsorrhaphy of the right eye. D. Healing of sclera melting following of the temporary tarsorrhaphy.



of welding equipment showed that 62.1% were flush burns from welding arc UV radiation emissions, followed by foreign body implantation (19.7%) and abrasions (11.1%) [5]. These injuries are partially explained by the lack of sufficient protective equipment at worksites [5].

Anterior necrotizing scleritis (ANS), a severe manifestation of such injuries, presents clinicians with diagnostic and therapeutic purposes. The typical clinical manifestation observed in this patient aligns with the insidious onset of pain and scleral discoloration perilymbally. While the initial presentation mimicked a straightforward conjunctival tear, postoperative scleral necrosis revealed the true extent of the injury's impact.

It is believed that scleritis is a type 3 hypersensitivity reaction, in which vascular injury is the result of culminating factors from antigen-antibody interactions, subsequently fostering an inflammatory T-cell response within episcleral tissues [15]. Thus, scleral destruction in the ANS is primarily attributed to the confluence of fibrocyte activation, infiltration of inflammatory cells to the scleral stroma, and prolonged local vaso-occlusion [14–16].

A case series showed that most surgically induced necrotizing scleritis cases could be treated with oral steroids with or without topical steroid eye drops [17, 18]. Biological agents such as infliximab have been shown to treat rheumatoid arthritis-associated ANS [13]. However, in resistant cases, grafts are still indicated for disease control. Enzenauer et al. were the first to introduce dura mater grafting as a potential treatment for ANS [11]. Similarly, periosteal grafts have been suggested as an alternative to ANS [10]. However, both have shown promising results following the wide use of amniotic membrane transplantation in various ocular diseases and surgeries, such as grafts following pterygium excision and limbal insufficiency [19, 20]. There is an ongoing trend in the use of AMT in patients with ANS [21]. Unfortunately, in our case, none of the above-mentioned treatment modalities was effective in treating ANS.

Temporary tarsorrhaphy is a safe and simple surgery in which the upper and lower eyelids are joined together using simple sutures to partially close the eye. It is a highly effec-

tive method for treating various conditions, such as corneal epithelial defects and different corneal diseases [22]. In addition, tarsorrhaphy prevents conjunctival swelling and exposure after ocular surgery, which aids in the healing process. Temporary tarsorrhaphy minimizes eyelid movement over corneal sutures, conjunctival grafts, and corneal grafts, thus reducing any microtrauma to the surgical site and promoting graft adherence [23]. We believe that temporary tarsorrhaphy was not the healing modality of ANS; rather, it created a sustainable environment for the other treatments applied to function without further exposure to irritation or microbes from outside the ocular surface.

Despite well-known therapeutic approaches for ANS, from topical agents to surgical grafts, the lack of a universal gold standard often makes the treatment pathway trial-and-error, dictated by the aggressiveness of the disease and the patient's responsiveness. The escalated progression of necrosis in this case, even after intensive combined therapy and grafting, indicates a particularly resistant form of ANS. Thus, through the implementation of tarsorrhaphy, we developed a method to promote healing without causing permanent damage to the surrounding tissue. Its success in achieving complete scleral healing opens avenues for reconsidering its role in managing resistant ANS cases.

CONCLUSION

This case reveals the challenges associated with managing trauma-induced anterior necrotizing scleritis, especially in the context of occupational hazards, such as welding. Although existing treatment modalities offer a broad spectrum of interventions, resistance to conventional therapies necessitates innovative approaches. The dramatic resolution post-tarsorrhaphy in this case not only sheds light on the potential role of this procedure in managing refractory ANS, but also advocates for an individualized, patient-centric approach. As the medical community strives towards a gold standard for ANS management, this case offers a compelling testament to the value of revisiting traditional interventions in unconventional contexts.

Figures: from authors' own materials.

CORRESPONDENCE

Dr. Ahmad Kunbaz

Faculty of Medicine, Department of Ophthalmology, Istanbul Medeniyet University
Eğitim district. Fahrettin Kerim Gökay street Kadıköy/
Istanbul 34722, Turkey
Tel. 00902166065200
e-mail: Ahmad.kunbaz@gmail.com
Ahmad.kunbaz@medeniyet.edu

ORCID

Ahmad Kunbaz – ID – <https://orcid.org/0000-0003-2209-8187>
Omer Faruk Yilmaz – ID – <https://orcid.org/0000-0001-5571-3735>
Halit Oguz – ID – <https://orcid.org/0000-0002-0983-5878>

References

1. Iftikhar M, Latif A, Farid UZ et al. Changes in the Incidence of Eye Trauma Hospitalizations in the United States from 2001 Through 2014. *JAMA Ophthalmol.* 2019; 137(1): 48-56.
2. Lombardi DA, Pannala R, Sorock GS et al. Welding related occupational eye injuries: A narrative analysis. *Injury Prevention.* 2005; 11: 174-9.
3. Fiebai B, Awoyesuku EA. Ocular injuries among industrial welders in Port Harcourt, Nigeria. *Clinical Ophthalmology.* 2011; 5(1): 1261-3.
4. Reesal MR, Dufresne RM, Suggett D et al. Welder eye injuries. *J Occup Med.* 1989; 31(12): 1003-6.
5. Yan J, Uppuluri A, Zarbin MA et al. Epidemiology of welding-associated ocular injuries. *Am J Emerg Med.* 2022; 54: 15-6.
6. Zhang T, Zhuang H, Wang K et al. Clinical Features and Surgical Outcomes of Posterior Segment Intraocular Foreign Bodies in Children in East China. *J Ophthalmol.* 2018; 2018: 5861043.
7. Chaudhry IA, Shamsi FA, Al-Harhi E et al. Incidence and visual outcome of endophthalmitis associated with intraocular foreign bodies. *Graefes Arch Clin Exp Ophthalmol.* 2008; 246(2): 181-6.
8. Kaplan HJ. Intraocular Foreign Body and Uveitis. In: *Clinical Cases in Uveitis.* Sandhu HS, Kaplan HJ. Elsevier, 2021; 102-5.
9. Ahearn BE, Lewis KE, Reynolds BE et al. Management of scleral melt. *Ocul Surf.* 2023; 27: 92-9.
10. Rao GN, Aquavella JV, Palumbo AJ. Periosteal graft in scleromalacia. *Ophthalmic Surg.* 1977; 8(5): 86-92.
11. Enzenauer RW, Enzenauer RJ, Reddy VB et al. Treatment of scleromalacia perforans with dura mater grafting. *Ophthalmic Surg.* 1992; 23(12): 829-32.
12. Oh JH, Kim JC. Repair of scleromalacia using preserved scleral graft with amniotic membrane transplantation. *Cornea.* 2003; 22(4): 288-93.
13. Atchia II, Kidd CE, Bell RWD. Rheumatoid arthritis-associated necrotizing scleritis and peripheral ulcerative keratitis treated successfully with infliximab. *J Clin Rheumatol.* 2006; 12(6): 291-3.
14. Kopacz D, Maciejewicz P, Kopacz M. Scleromalacia Perforans –What We Know and What We Can Do. *J Clin Experiment Ophthalmol.* 2013; S2: 009.
15. de Andrade FA, Fiorot SHS, Benchimol EI et al. The autoimmune diseases of the eyes. *Autoimmun Rev.* 2016; 15(3): 258-71.
16. Young RD, Watson PG. Microscopical studies of necrotising scleritis. I. Cellular aspects. *Br J Ophthalmol.* 1984; 68(11): 770-80.
17. Madanagopalan VG, Shivananda N, Krishnan T. Surgically induced necrotizing scleritis after retinal detachment surgery masquerading as scleral abscess. *GMS Ophthalmol Cases.* 2019; 9: Doc18.
18. O'Donoghue E, Lightman S, Tuft S et al. Surgically induced necrotising sclerokeratitis (SINS) – precipitating factors and response to treatment. *Br J Ophthalmol.* 1992; 76(1): 17.
19. Katbaab A, Ardekani HRA, Khoshniyat H et al. Amniotic Membrane Transplantation for Primary Pterygium Surgery. *J Ophthalmic Vis Res.* 2008; 3(1): 23.
20. Anderson DF, Ellies P, Pires RTF et al. Amniotic membrane transplantation for partial limbal stem cell deficiency. *Br J Ophthalmol.* 2001; 85(5): 567-75.
21. Syed ZA, Rapuano CJ. Umbilical amnion and amniotic membrane transplantation for infectious scleritis and scleral melt: A case series. *Am J Ophthalmol Case Rep.* 2021; 21: 101013.
22. Cosar CB, Cohen EJ, Rapuano CJ et al. Tarsorrhaphy: clinical experience from a cornea practice. *Cornea.* 2001; 20(8): 787-91.
23. Gelatt KN, Brooks DE. Surgery of the cornea and sclera. In: *Veterinary Ophthalmic Surgery.* Gelatt KN, Peterson Gelatt J (eds.). W.B. Saunders, 2011: 191-236.

Authors' contributions:

Ahmad Kunbaz – conceptualization, manuscript writing, and literature review.
Omer Faruk Yilmaz – supervision, surgical intervention, case management, and critical revision of the manuscript.
Halit Oguz – supervision, clinical support, and final manuscript approval.

Conflict of interest:

None.

Financial support:

None.

Ethics:

The content presented in the article complies with the principles of the Helsinki Declaration, EU directives and harmonized requirements for biomedical journals.