

# Pigmentary glaucoma – a case report



Katarzyna Paczwa<sup>1</sup>, Magdalena Rerych<sup>1</sup>, Jaromir Wasyluk<sup>1,2</sup>,  
Radosław Różycki<sup>1</sup>

<sup>1</sup> Department of Ophthalmology, Military Institute of Aviation Medicine, Warsaw  
Head: Radosław Różycki, MD, PhD

<sup>2</sup> OPTIMUM Eye Center, Warsaw  
Head: Jaromir Wasyluk MD PhD

## HIGHLIGHTS

The case of advanced and severe pigmentary glaucoma in young patient with its consequences and treatment methods was presented in this article.

## ABSTRACT

Pigmentary glaucoma is a type of secondary open-angle glaucoma. Mainly it is a consequence of pigment dispersion syndrome, which is characterized by pigment accumulation in the anterior segment of the eye. Pigment in the trabecular meshwork can cause increased intraocular pressure leading to glaucomatous damage of the optic nerve. We present a case of 40-year-old myopic male with typical symptoms of pigmentary dispersion syndrome who received late diagnosis of the disease. The correct diagnosis of pigmentary dispersion syndrome is crucial in preventing glaucomatous vision impairment.

**Key words:** pigmentary glaucoma, pigment dispersion syndrome, Krukenberg spindle, glaucoma, visual disability

## INTRODUCTION

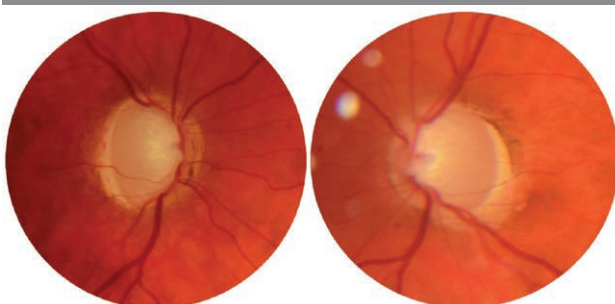
Pigmentary glaucoma (PG) is a type of secondary open-angle glaucoma. It represents 1–1.5 % cases of glaucoma worldwide. Mainly it is a consequence of pigmentary dispersion syndrome (PDS) [1]. PDS is characterized by pigment dispersion and its accumulation in the anterior segment of the eye – trabecular meshwork, corneal endothelium, lens surface and iris [1]. Pigment on the trabecular meshwork cause outflow obstruction of aqueous humor leading to increased intraocular pressure (IOP) and consequently to optic neuropathy [2–4]. PDS is more common among Caucasian man with myopia, between 20–40 years old. Both diseases are described by characteristic triad consisting of: Krukenberg spindle (vertical pigmentation area of the corneal endothelium), hyperpigmentation of meshwork and mid-periphery transillumination defect of the iris [2]. Moreover, studies revealed that more often patients show concave iris configuration leading to reverse pupillary block (RPB) [5]. Other hallmarks of both diseases include pigment deposition on the posterior lens capsule (Scheie stripe or Zentmeyer line) [6], on the anterior hyaloidocapsular ligament (Egger line) [7, 8]. The rate of conversion of PDS to PG is estimated to be 10% in 5 years and 50% in the lifetime [6, 9].

## CASE REPORT

A-40-year-old man presented in May 2023 to ophthalmology department with painless blurry vision in the right eye for several months. The examination revealed the best corrected visual acuity (BCVA) of hand motion in the right eye and 20/20 in the left eye with correction of -5 D. IOP was highly increased to 46 mmHg in the right eye and 42 mmHg in the left eye. The anterior segment evaluation showed deep anterior chamber, mid-periphery transillumination defect of the iris and pigment granules on the iris surface. Moreover, the gonioscopy examination revealed widely open angle with dense dark pigmentation of the trabecular meshwork in its entire circumference. The fundoscopic examination of both eyes showed enlarged cup-disc ratio of 1.0 in the right eye and of 0.9 in the left eye (fig. 1).

FIGURE 1

Disc photography with enlarged cup-disc ratio.



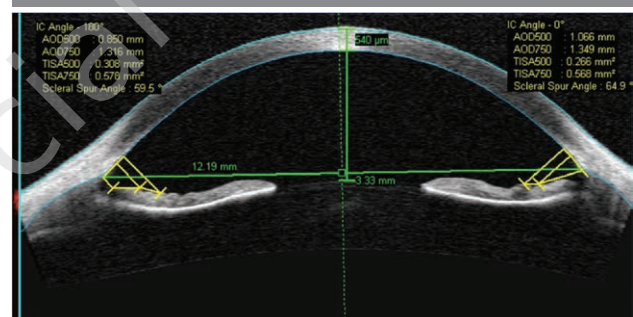
Firstly, patient was treated with hypotensive topical medications to reduce intraocular pressure: carbonic anhydrase inhibitor (also systemic), non-selective  $\beta$ -blocker, prostaglandin.

In the diagnostic process imaging and additional tests were planned.

Anterior segment optical coherence tomography scans revealed a concave iris configuration with increased anterior chamber depth (fig. 2).

FIGURE 2

Anterior optical coherence tomography image of patients concave iris configuration.



Optical coherence tomography showed damaged retinal nerve fibre layer (RNFL) in every quadrant in both eyes (fig. 3).

Visual field examination showed severe deterioration of the visual field with absolute scotoma in the inferior hemisphere in the right eye and closing annular scotoma reaching the center in the left eye (fig. 4, 5).

Patient was diagnosed with PG as a result of PDS. Following the diagnosis, conservative hypotensive therapy was continued.

Moreover, because of the high IOP and advanced glaucomatous optic neuropathy, the patient underwent non-perforating deep sclerectomy with mitomycin C in the right eye. The other eye was left on hypotensive medications.

During the follow-up visits, the IOP was normal and stable in both eyes (tab. 1). However, the visual acuity in the right eye has not improved. Patient remains under close ophthalmological observation.

TABLE 1

IOP measurements during follow-up visits.

	Right eye	Left eye
After introducing topical therapy	22 mmHg	18 mmHg
Post RE surgery	6 mmHg	12 mmHg
7 days post surgery	7 mmHg	12 mmHg
1 month post surgery	10 mmHg	15 mmHg
2 month post surgery	13 mmHg	18 mmHg

FIGURE 3

Optical coherence tomography (OCT) of the retinal nerve fibre layer shows normal average thickness with focal temporal thinning in both eyes, representing a papillomacular bundle injury. OCT of the retinal ganglion cell (RGC) complex shows diffuse RGC loss in both eyes.

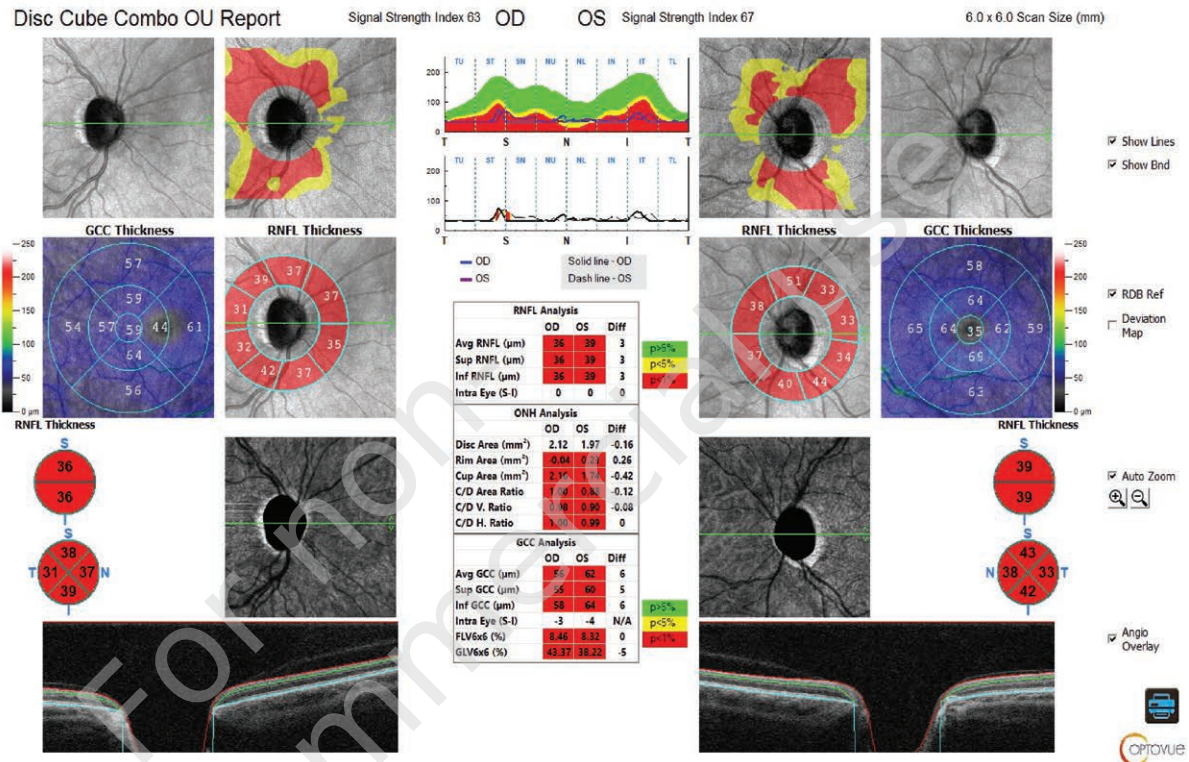


FIGURE 4

Visual field with complete deprivation of the visual field with absolute scotoma in inferior hemisphere in the right eye.





FIGURE 5

Visual field with closing annular scotoma reaching to the center in the left eye.





## DISCUSSION

Pigment dispersion syndrome typically occurs in adult patients [8]. Firstly patients are usually asymptomatic, and the signs of the disease are accidentally discovered during a standard eye examination. PDG may be diagnosed using slit lamp examination, gonioscopy, tonometry, visual field examination and optical coherence tomography [8]. The management and treatment of the disease depends on various factors such as IOP value, glaucomatous optic neuropathy presence of amount of dispersed pigment and patients age [8]. Some studies suggest that, due to decreased pigment production with age, some patient can reach a burn-out phase [2, 8].

The aim of the therapy is lowering the IOP and preventing the glaucomatous damage. It consists of hypotensive medications, laser therapies and surgery.

Laser peripheral iridotomy (LPI) has been suggested in patients with concave iris configuration to prevent RPB by equalizing the pressure in the anterior and posterior chambers and reduce iridolenticular contact [10] leading to increased pigment release. However, the studies are inconclusive in the long-term results of IOP-lowering effect [10, 11].

Local hypotensive drugs consist of prostaglandins,  $\beta$ -blockers, carbonic anhydrase inhibitors and  $\alpha$ -adrenergic agonists. Prostaglandins are considered to be the most effective and well-tolerated and should be considered as an initial treatment of choice [11].

According to European Glaucoma Society, selective laser trabeculoplasty (SLT) can be used as a first-line therapy in PG [12]. This laser therapy shows selective absorption of

energy in pigmented tissue without tissue scarring [11, 13]. Studies shows that SLT efficiency decrease in time, however the procedure can be repeated [2, 11, 14]. At the same time because of highly pigmented trabecular meshwork the patients are more predisposed to the risk of post-SLT elevations of IOP.

Surgical treatment should be considered in case of not reaching the target IOP with maximum topical and laser therapy [7, 8]. Classic trabeculectomy is effective in long-time lowering IOP in PG. Moreover, microinvasive glaucoma surgeries (MIGS), for example canaloplasty, can be an alternative surgical option [15].

In presented case a typical PDS patient was diagnosed with advanced stage of glaucomatous optic neuropathy in course of PG. Because of this glaucomatous damage, especially in the right eye, and high IOP he underwent surgery. The severe visual impairment might have been avoided if a proper diagnose and treatment were introduced earlier.

## CONCLUSION

PG is a rather rare type of secondary open-angle glaucoma and may cause some diagnostic difficulties. The disease may be asymptomatic for a long duration time that is why its diagnosis is frequently delayed. The earlier the disease is detected, the sooner the appropriate treatment can be implemented, which is associated with stopping or delaying the progression of the disease and reducing its dramatic consequences such as a visual loss.

*Figures: from the authors' own materials.*

## CORRESPONDENCE

**Katarzyna Paczwa, MD**

Department of Ophthalmology,  
Military Institute of Aviation Medicine  
01-755 Warszawa, ul. Zygmunta Krasińskiego 54/56  
e-mail: kasiapaczwa@gmail.com

## ORCID

Katarzyna Paczwa – ID – <http://orcid.org/0000-0003-3825-3727>  
Magdalena Rerych – ID – <http://orcid.org/0000-0002-8944-856X>  
Jaromir Wasyluk – ID – <http://orcid.org/0000-0002-0080-6050>  
Radosław Różycki – ID – <https://orcid.org/0000-0001-7040-026X>

## References

1. Scuderi G, Contestabile MT, Scuderi L et al. Pigment dispersion syndrome and pigmentary glaucoma: a review and update. *Int Ophthalmol*. 2019; 39(7): 1651-62. <http://doi.org/10.1007/s10792-018-0938-7>.
2. Wasyluk J, Prost ME. Pigment dispersion syndrome and pigmentary glaucoma. *Contemporary diagnostics and therapeutic approach. Ophthalmotherapy* 2014; 1(1): 35-40.
3. Niyadurupola N, Broadway DC. Pigment dispersion syndrome and pigmentary glaucoma – a major review. *Clin Exp Ophthalmol*. 2008; 36(9): 868-82. <http://doi.org/10.1111/j.1442-9071.2009.01920.x>.
4. Sivaraman KR, Patel CG, Vajaranant TS et al. Secondary pigmentary glaucoma in patients with underlying primary pigment dispersion syndrome. *Clin Ophthalmol*. 2013; 7: 561-6. <http://doi.org/10.2147/OPTH.S42456>.
5. Fornes AM. Pigment dispersion syndrome: The reverse pupillary block theory and new treatment options. *Clin Eye Vis Care*. 1995; 7(4): 229-31. [https://doi.org/10.1016/0953-4431\(95\)00141-7](https://doi.org/10.1016/0953-4431(95)00141-7).
6. Zeppieri M. Pigment dispersion syndrome: A brief overview. *J Clin Transl Res*. 2022; 8(5): 344-50.
7. Noecker RJ. Pigment Dispersion Syndrome and Pigmentary Glaucoma. In: Noecker RJ (ed.). *Glaucoma Medical Therapy: Principles and Management*. Springer, 2008.
8. Zeppieri M, Tripathy K. Pigment Dispersion Glaucoma. In: StatPearls Internet. Treasure Island (FL): StatPearls Publishing, 2023. <https://www.ncbi.nlm.nih.gov/books/NBK580495/>.
9. Siddiqui Y, Ten Hulzen RD, Cameron JD et al. What is the risk of developing pigmentary glaucoma from pigment dispersion syndrome? *Am J Ophthalmol*. 2003; 135(6): 794-9. [http://doi.org/10.1016/s0002-9394\(02\)02289-4](http://doi.org/10.1016/s0002-9394(02)02289-4).
10. Buffault J, Leray B, Bouillot A et al. Role of laser peripheral iridotomy in pigmentary glaucoma and pigment dispersion syndrome: A review of the literature. *Journal francais d'ophtalmologie*. 2017; 40(9): e315-21. <https://doi.org/10.1016/j.jfo.2017.09.002>.
11. Okafor K, Vinod K, Gedde SJ. Update on pigment dispersion syndrome and pigmentary glaucoma. *Curr Opin Ophthalmol*. 2017; 28(2): 154-60. <https://doi.org/10.1097/icu.0000000000000352>.
12. European Glaucoma Society Terminology and Guidelines for Glaucoma, 5th Edition. *Br J Ophthalmol*. 2021; 105(Suppl. 1): 1-169. <https://doi.org/10.1136/bjophthalmol-2021-egsguidelines>.
13. Liput J, Tan W. Selective laser trabeculoplasty for open angle glaucoma. *Ophthalmotherapy*. 2017; 4(4): 199-209.
14. Ayala M, Chen E. Long-Term Outcomes of Selective Laser Trabeculoplasty (SLT) Treatment. *Open Ophthalmol J*. 2011; 5: 32-4. <https://doi.org/10.2174/1874364101105010032>.
15. Brusini, P, Papa V. Canaloplasty in Pigmentary Glaucoma: Long-Term Outcomes and Proposal of a New Hypothesis on Its Intraocular Pressure Lowering Mechanism. *J Clin Med*. 2020; 9(12): 4024. <https://doi.org/10.3390/jcm9124024>.

### Wkład autorów:

Wszyscy autorzy mają taki sam wkład w opracowanie idei i konstrukcji artykułu.

### Konflikt interesów:

Nie występuje.

### Finansowanie:

Nie występuje.

### Etyka:

Treści przedstawione w artykule są zgodne z zasadami Deklaracji Helsińskiej, dyrektywami EU oraz ujednoliconymi wymaganiami dla czasopism biomedycznych.

### Authors' contributions:

All authors have equal contribution to the paper.

### Conflict of interest:

None.

### Financial support:

None.

### Ethics:

The content presented in the article complies with the principles of the Helsinki Declaration, EU directives and harmonized requirements for biomedical journals.