

Scleritis in systemic diseases

**Aneta Pyza¹, Jakub Piórek¹, Ismael Alsoubie¹,
Natalie Papachristoforou¹, Anthony Ueno¹, Julia Kaczmarek¹,
Natalia Wolińska¹, Monika Papież¹, Alan Pigoński¹,
Katarzyna Sajak-Hydzik^{1,2}, Ilona Pawlicka^{1,2}, Agnieszka Piskorz^{1,2},
Maciej Kozak^{1,2}, Anna Maria Roszkowska^{1,3}**



¹ Faculty of Medicine and Health Sciences, Collegium Medicum, Andrzej Frycz Modrzewski Academy in Krakow
Head: prof. KAAFM Janusz Ligeza, PhD

² Clinical Ophthalmology Department, Section „A”, Provincial Ophthalmological Hospital in Krakow
Head: Maciej Kozak, MD, PhD

³ Department of Biomedical and Dental Sciences and Morphofunctional Imaging, University of Messina, Italy
Head: prof. Sergio Baldari

HIGHLIGHTS

Autoimmune diseases are the most common cause of scleritis, which is a serious ophthalmological condition. If it is untreated, can lead to reduced acuity or even loss of vision, therefore, it is important to diagnose the underlying disease as soon as possible and institute appropriate treatment.

ABSTRACT

This paper discusses scleritis in the course of systemic autoimmune diseases such as rheumatoid arthritis, nodular arteritis and granulomatosis with vasculitis. In addition, treatment suggestions based on the available literature are presented. Patients with scleritis resulting from an underlying disease should be diagnosed as soon as possible and given appropriate and effective treatment. Untreated or poorly treated scleritis or underlying disease can lead to severe damage to ocular tissues, loss of vision and eventually even blindness. A meticulous medical history, detailed ophthalmic examination and a series of targeted investigations as part of a multidisciplinary approach to detect any systemic disease are important in the management of scleritis. Rheumatoid arthritis remains the most common systemic rheumatic disease and the most common systemic condition associated with scleritis.

Key words: scleritis, autoimmune diseases, immunomodulatory drugs, glucocorticosteroids, rheumatoid arthritis, systemic lupus erythematosus, granulomatosis with vasculitis, polyarteritis nodosa

INTRODUCTION

The sclera is the thick, outer layer of the eye. It surrounds the eyeball from the orbital side, and in its anterior part it passes into the cornea merging with it in the corneal stroma. Together with the cornea constitutes the outer wall which, thanks to its properties, forms a flexible but resistant, eyeball skeleton. This maintains a constant eyeball shape while the eye muscles are working. The sclera is made up of 3 layers: the dura, the brown lamina, the supratentorial lamina. It is poorly innervated and has poor vascularisation [1].

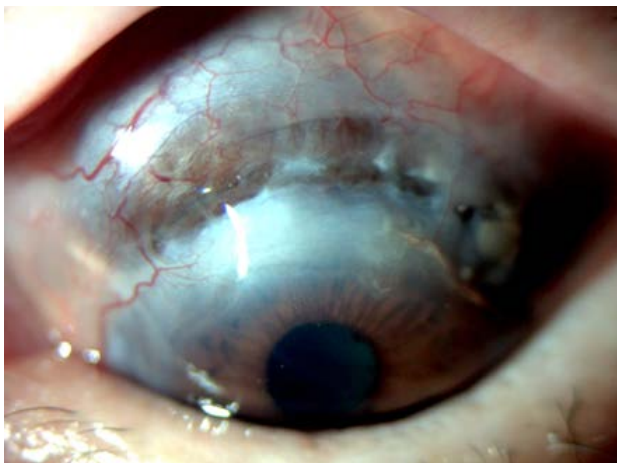
SCLERITIS

Scleritis is a rare eye disorder associated with inflammation of the outer membrane of the eye, the sclera. It is characterised by tissue destruction, which can eventually lead to loss of vision and even blindness [2]. In 1976, a classification of scleritis was developed by Watson and Hayreh, which is still used today. Based on it, the condition is divided into:

1. Anterior scleritis (98%)
 - a. non-necrotizing:
 - nodular
 - diffuse
 - b. necrotizing:
 - with inflammation
 - without inflammation – perforating softening sclera (fig. 1).
2. Posterior scleritis (2%) [3].

FIGURE 1

Perforating softening sclera.



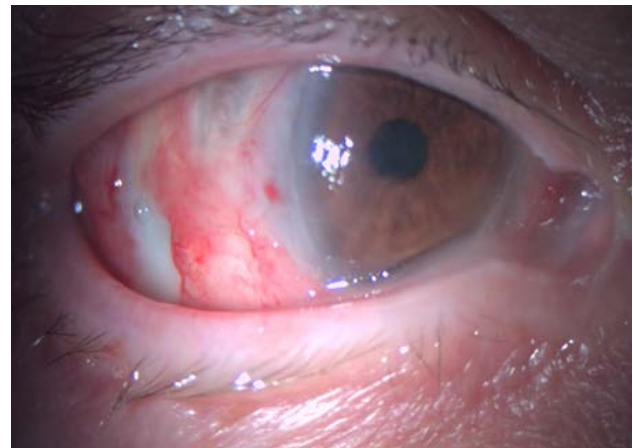
The most common causes of scleritis are systemic autoimmune diseases such as rheumatoid arthritis (RA), granulomatosis with vasculitis, systemic lupus erythematosus and nodular arteritis, for example [4]. Less commonly, scleritis is

caused by a local infection such as herpes zoster or systemic herpes, fungal infection, as well as by certain drugs, ocular trauma or ocular irradiation, and malignant tumours [2].

In patients with autoimmune diseases, such as RA, systemic lupus erythematosus (SLE), nodular arteritis or granulomatosis with inflammation vessels, an episode of inflammation may occur more frequently sclera (fig. 2). It is very important then treatment of the underlying disease. Non-steroidal anti-inflammatory drugs (NSAIDs), glucocorticosteroids, immunosuppressant and biologics are used in the treatment of scleritis [4].

FIGURE 2

Necrotizing inflammation in granulomatosis with polyangiitis.



Failure to treat, or not treating, can lead to serious ocular complications, including to tissue damage, loss of vision and even the eyeball. Consequently, the disease can significantly reduce the patient's quality of life [2].

Women between 30 and 40 years of age are more likely to suffer from this disease. Scleritis may be the first symptom of a general disease. The characteristic symptom of this disease is pain – sometimes ranging from slight discomfort to a very severe and dull ache in the eye that intensifies on touch. This may be accompanied by light sensitivity, frequent tearing, redness and swelling of the sclera. The inflammation can affect one or both eyes. If anterior scleritis is involved, then it usually manifests as severe pain and redness of the eye, usually without loss of visual acuity. This pain may awaken the patient from sleep and may also radiate to the cheek, orbit. On the other hand, if there is posterior scleritis, then there is also severe pain occurring with eye movement, accompanied by impaired eye movement, sometimes with exophthalmos. Redness of the eye may be slight or absent and there is deterioration of vision, which in this case may be associated with serous retinal detachment [5].

RHEUMATOID ARTHRITIS

RA (Latin: *arthritus rheumatoidea, polyarthritus chronica evolutiva*) is an autoimmune disease most commonly associated with scleritis. RA is a chronic systemic disease with an autoimmune basis and an incompletely understood aetiology. In its course, non-specific joint inflammation is characteristic. The most typical symptoms for RA are joint pain, stiffness and swelling – this mainly affects small and medium-sized joints. The disease is primarily associated with symptoms due to joint involvement, but extra-articular and systemic symptoms may also be present. It is not uncommon for RA to co-occur with scleritis and epidural inflammation. The organ of vision can also develop keratoconjunctivitis. Treatment of scleritis in the course of RA can sometimes be difficult. The main treatment options are: methotrexate as a first-line drug at a dose of 25–30 mg/week with appropriate folic acid supplementation. Other drugs include: sulfasalazine or leflunomide, tofacitinib (the janus kinase inhibitor JAK1 and JAK3) and baricitinib (the janus kinase inhibitor JAK1 and JAK2). In addition, glucocorticosteroids, NSAIDs and biologic drugs are used: adalimumab, etanercept, tocilizumab, rituximab [6].

SYSTEMIC LUPUS ERYTHEMATOSUS

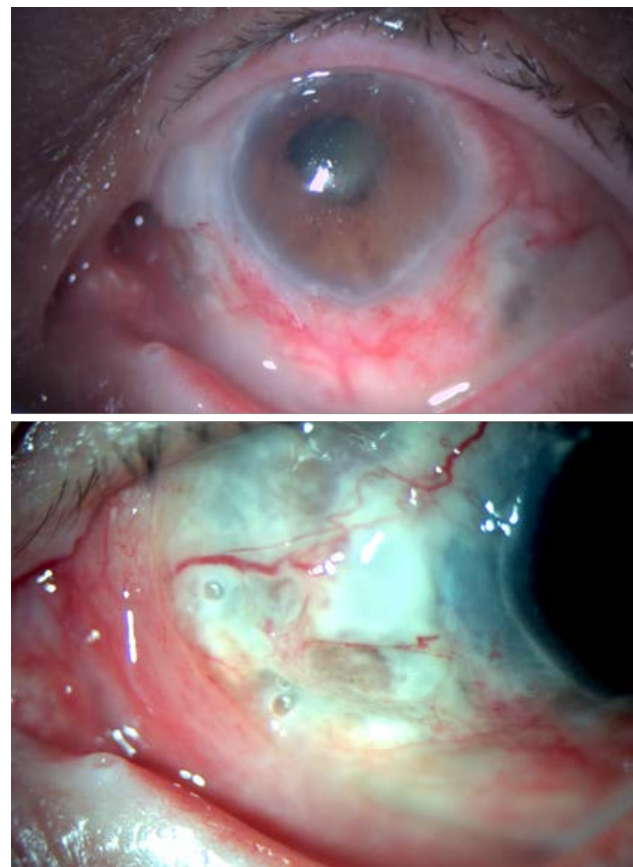
SLE is an autoimmune disease that can involve multiple organs, including the eyeball. The pathogenesis is multifactorial and complex. Also with SLE, there is an inflammation, which is caused by the formation of autoantibodies and immune complexes. As a consequence, this leads to multi-organ damage. In the course of this disease, there is an abnormal inflammatory response of the body, which results from a disturbance of the immune system. The clinical manifestations of SLE are variable, as are the ocular manifestations and may involve any part of the eye [7, 8] and may correlate with systemic disease activity. Silpa-archa et al. described a group of 585 patients with scleritis and epididymitis. In 35.8% an association of SLE with scleritis was observed, and in 27.1% an association of SLE with epididymitis was observed. In addition, Heron et al. in a more recent analysis showed on 1,358 cases with scleritis that it more often accompanies rheumatoid arthritis (6.4–10.4%) compared to SLE (2%). Ocular lesions that may occur in the course of SLE include inflammation of the epithelium and sclera. The treatment of systemic lupus erythematosus is similar to that used in the course of RA [9]. The treatment of SLE includes: NSAIDs, glucocorticosteroids, immunomodulatory drugs (such as methotrexate or mycophenolate mofetil), azathioprine and treatment biologics with belimumab and rituximab [8].

GRANULOMATOSIS WITH POLYANGIITIS

Granulomatosis with polyangiitis (GPA; formerly *Wege-ner's granulomatosis*) is an autoimmune disease associated with small- and medium-sized vasculitis [10]. Typically, anti-neutrophil cytoplasmic antibodies (cANCA) play a major role in GPA. The disease is associated with necrotising granulomatous inflammation of the upper and lower respiratory tract and necrotising glomerulonephritis [11]. Ocular symptoms in the course of GPA can occur in 16–78% of patients, with approximately 27% of undiagnosed GPA patients experiencing them at the onset of the disease [12]. Ocular lesions are mainly inflammation of the sclera and superciliary membrane, conjunctiva, uvea or lacrimal gland (fig. 3). Treatment of granulomatosis with vasculitis consists of glucocorticosteroids, the immunosuppressant cyclophosphamide, the biologic drug rituximab and, in severe cases, plasmapheresis. In maintaining remission, rituximab and one of the drugs azathioprine, methotrexate or mycophenolate mofetil are used [13].

FIGURE 3

Necrotizing inflammation in GPA.



POLYARTERITIS NODOSA

Polyarteritis nodosa (PAN, *polyarteritis nodosa*) is a necrotising inflammation of small or medium-sized arteries, unrelated to ANCA, that can affect ocular tissues. According to the literature, approximately 10–20% of patients with PAN develop ophthalmic symptoms, including scleritis [14]. It is important to highlight the fact that ocular inflammation may be the earliest manifestation of nodular arteritis, as outlined in the article by Akov et al. [15]. Treatment of nodular arteritis is the same as in GPA. The first-line drugs are glucocorticosteroids. Immunosuppressive drugs like cyclophosphamide, mycophenolate mofetil and biologics are not indicated in patients with PAN. However, in cases of severe side effects from glucocorticosteroids treatment, their use is acceptable. Additionally, rituximab is considered to be of potential benefit in some severe cases of PAN [14, 16, 17].

TREATMENT

When scleritis is diagnosed, it is essential to start treatment as soon as possible. The primary aim of therapy is to control the inflammation. Consequently, limiting the destruction of ocular tissues, controlling symptoms – including pain, and preventing sequelae and recurrence of the condition [14, 18]. Local treatment is only ancillary and systemic treatment is always necessary.

The basis in starting treatment is to determine the type of scleritis, as our therapeutic management depends on this. Systemic drugs such as NSAIDs, glucocorticosteroids, immunomodulatory drugs and biologics are used in the treatment of scleritis.

In mild to moderate cases of non-infected scleritis, topical glucocorticosteroid drops may be considered [19]. Topical NSAIDs can reduce ocular inflammation and modulate pain, but their primary use is still usually systemic [20]. For non-arthritis scleritis, NSAIDs are the mainstay of treatment. If no improvement is observed after 1–2 weeks, then consideration should be given to changing the NSAID to another one or excluding this drug from the therapeutic plan and introducing glucocorticosteroids into the therapy. When the applied therapy is ineffective, periocular administration of glucocorticosteroids can be used. When dealing with necrotising scleritis, glucocorticosteroids are the first-line treatment. In cases that are difficult to treat or in cases that require glucocorticosteroids for a long period of time, immunomodulatory drugs – mainly antimetabolites – are recommended for sparing treatment.

NSAID therapy, i.e. in non-arthritis scleritis, can be used: indomethacin 50 mg 3 times a day, ibuprofen 600 mg 3 times a day, naproxen 500 mg 2 times a day, flurbiprofen 100 mg

3 times a day or meloxicam 7.5 mg 3 times a day. Systemic, oral glucocorticosteroid therapy is another treatment option if NSAIDs are ineffective. This should be started with prednisone 1 mg/kg/24 h and continued until 1 month after the scleritis has resolved, after which the dosage should be gradually reduced.

In non-arthritis scleritis, subconjunctival glucocorticosteroid injections, e.g. triamcinolone acetonide (40 mg/ml), have also shown efficacy. In cases of severe scleritis, it may be necessary initially to administer methylprednisolone intravenously at a dose of 0.5 to 1 g in pulses over several days. Side effects such as weight gain, reduced resistance to infection, hyperglycaemia or increased intraocular pressure, which are associated with the use of glucocorticosteroids, must always be kept in mind.

In cases of severe scleritis or when treatment with glucocorticosteroids is ineffective, immunomodulatory drugs should be used. Immunomodulatory therapy is used in patients who do not present improvement after NSAIDs and systemic glucocorticosteroids, to discontinue chronic glucocorticosteroid therapy, during long-term treatment of scleritis or to treat an underlying systemic disease. In clinical practice, of the immunomodulatory drugs, the most commonly used is methotrexate at a starting dose of 0.15 mg/kg body mass in combination with appropriate folic acid supplementation. Other immunomodulatory drugs used in the treatment of scleritis include azathioprine, mycophenolate mofetil and cyclophosphamide. However, a number of studies show that their efficacy compared to methotrexate is lower.

The biologic drugs most commonly used in this case include tumour necrosis factor α (TNF- α) inhibitors such as the monoclonal antibodies adalimumab, infliximab and certolizumab, as well as the soluble TNF receptor fusion protein etanercept and the CD20 inhibitor rituximab. Many studies have demonstrated the efficacy of biologic drugs in the treatment of scleritis. However, there are also reports of an increase in ocular inflammatory diseases that paradoxically appear to be associated with the use of biologic drugs. These studies have looked specifically at etanercept [20].

Drug and dose adjustments should be considered on an individual basis based on clinical response.

In cases of severe and progressive necrotising scleritis, despite therapy, surgical removal of dead scleral tissue and washing with 2.5% betadine solution or broad-spectrum antibiotics should be considered. If there is extensive inflammatory involvement of the sclera, then amniotic membrane transplantation or the sclera itself may be considered [18, 20].

Figures: from the author's own materials

CORRESPONDENCE**med. stud. Aneta Pyza**

Faculty of Medicine and Health Sciences, Collegium Medicum,
Andrzej Frycz Modrzewski Academy in Krakow
30-705 Kraków, ul. Gustawa Herlinga-Grudzińskiego 1
e-mail: pyzaaneta@gmail.com

ORCID

Ismael Alsoubie – ID – <http://orcid.org/0000-0002-0974-3025>
Aneta Pyza – ID – <http://orcid.org/0009-0000-5318-1368>
Julia Kaczmarek – ID – <http://orcid.org/0009-0001-2268-6547>
Natalie Papachristoforou – ID – <http://orcid.org/0009-0006-8417-3794>
Jakub Piórek – ID – <http://orcid.org/0009-0001-4744-1933>
Natalia Wolińska – ID – <http://orcid.org/0000-0003-0975-9163>
Antohny Ueno – ID – <http://orcid.org/0009-0008-6946-4096>
Monika Papież – ID – <http://orcid.org/0009-0008-0397-7825>
Alan Pigoński – ID – <http://orcid.org/0009-0003-9955-0888>
Maciej Kozak – ID – <http://orcid.org/0000-0001-7993-2588>
Ilona Pawlicka – ID – <http://orcid.org/0000-0003-1556-7678>
Katarzyna Sajak-Hydzyk – ID – <http://orcid.org/0000-0002-1973-2717>
Agnieszka Piskorz – ID – <http://orcid.org/0000-0003-4553-0497>
Anna Maria Roszkowska – ID – <http://orcid.org/0000-0002-8083-3437>

References

1. Niżankowska H. Okulistyka. Podstawy kliniczne. PZWL, Warszawa 2007.
2. Vergouwen DPC, Rothova A, Berge JCT et al. Current insights in the pathogenesis of scleritis. *Exp Eye Res.* 2020; 197: 108078.
3. Czaplicka E. Objawy okulistyczne w przebiegu chorób reumatycznych. In: Wielka Interna. Reumatologia. Wyd. II. Puszczewicz M (ed.). Medical Tribune Polska, Warszawa 2016.
4. Abdel-Aty A, Gupta A, Del Priore L et al. Management of noninfectious scleritis. *Ther Adv Ophthalmol.* 2022; 14: 25158414211070879.
5. Promelle V, Goeb V, Gueudry J. Rheumatoid Arthritis Associated Episcleritis and Scleritis: An Update on Treatment Perspectives. *J Clin Med.* 2021; 10(10): 2118. <http://doi.org/10.3390/jcm10102118>.
6. Filipowicz-Sosnowska A. VII; D; 1. Reumatoidalne zapalenie stawów. In: Interna Szczeklika 2020. Gajewski P (ed.). Medycyna Praktyczna, Kraków 2020: 2030-45.
7. Islam MA, Khandker SS, Kotyla PJ et al. Immunomodulatory Effects of Diet and Nutrients in Systemic Lupus Erythematosus (SLE): A Systematic Review. *Front Immunol.* 2020; 11: 1477. <http://doi.org/10.3389/fimmu.2020.01477>.
8. Silpa-archa S, Lee JJ, Foster CS. Ocular manifestations in systemic lupus erythematosus. *Br J Ophthalmol.* 2016; 100(1): 135-41. <http://doi.org/10.1136/bjophthalmol-2015-306629>.
9. Heron E, Gutzwiller-Fontaine M, Bourcier T. Scleritis and episcleritis: diagnosis and treatment. *Rev Med Interne.* 2014; 35: 577-85. <http://doi.org/10.1016/j.revmed.2014.02.004>.
10. Moin KA, Yeakle MM, Parrill AM et al. Ocular and orbital manifestations of granulomatosis with polyangiitis: a systematic review of published cases. *Rom J Ophthalmol.* 2023; 67(3): 214-21. <http://doi.org/10.22336/rjo.2023.38>.
11. Cleary JO, Sivarasan N, Burd C et al. Head and neck manifestations of granulomatosis with polyangiitis. *Br J Radiol.* 2021; 94(1119): 20200914. <http://doi.org/10.1259/bjr.20200914>.
12. Říhová E, Svozílková P, Brichová M et al. Ocular Manifestations of Granulomatosis with Polyangiitis. *Oční projevy granulomatózy s polyangiitidou. Cesk Slov Oftalmol.* 2019; 74(5): 167-74. <http://doi.org/10.31348/2018/5/1>.
13. Musiał J, Szczeklika A, Sznajd J. VII; D; 10.2.1.2. Ziarniniakowatość z zapaleniem naczyń. In: Interna Szczeklika 2020. Gajewski P. (ed.). Wydawnictwo Medycyna Praktyczna, Kraków 2020: 2085-88.
14. Lee AB, Charoenkijakorn C, Stoutin J et al. Neuro-ophthalmic manifestations of Polyarteritis Nodosa. *Eyewiki.* https://eyewiki.aaopt.org/Neuro-ophthalmic_manifestations_of_Polyarteritis_Nodosa.
15. Akova YA, Jabbur NS, Foster CS. Ocular presentation of polyarteritis nodosa. Clinical course and management with steroid and cytotoxic therapy. *Ophthalmology.* 1993; 100(12): 1775-81. [http://doi.org/10.1016/s0161-6420\(93\)31405-3](http://doi.org/10.1016/s0161-6420(93)31405-3).
16. Vazquez-Romo KA, Rodriguez-Hernandez A, Paczka JA et al. Optic Neuropathy Secondary to Polyarteritis Nodosa, Case Report, and Diagnostic Challenges. *Front Neurol.* 2017; 8: 490. <http://doi.org/10.3389/fneur.2017.00490>.
17. Eleftheriou D, Melo M, Marks SD et al. Biologic therapy in primary systemic vasculitis of the young. *Rheumatology (Oxford).* 2009; 48(8): 978-86. <http://doi.org/10.1093/rheumatology/kep148>.
18. Lagina A, Ramphul K. Scleritis. In: StatPearls. StatPearls Publishing, Treasure Island (FL) 2023.

19. Dutta Majumder P, Agrawal R, McCluskey P et al. Current Approach for the Diagnosis and Management of Noninfective Scleritis. *Asia Pac J Ophthalmol (Phila)*. 2020; 10(2): 212-23. <http://doi.org/10.1097/APO.0000000000000341>.
20. Murthy SI, Sabhapandit S, Balamurugan S et al. Scleritis: Differentiating infectious from non-infectious entities. *Indian J Ophthalmol*. 2020; 68(9): 1818-28. http://doi.org/10.4103/ijo.IJO_2032_20.

Authors' contributions:

All authors have equal contribution to the paper.

Conflict of interest:

There is nothing to disclose regarding this manuscript.

Financial support:

None.

Ethics:

The content presented in the article complies with the principles of the Helsinki Declaration, EU directives and harmonized requirements for biomedical journals.