

# Negative dysphotopsia after cataract surgery – a problem that exists



**Marcin Jezierski, Piotr Dobrowolski**

Department of Ophthalmology, Military Institute of Aviation Medicine, Warsaw  
Head: Radosław Różycki, MD, PhD

## HIGHLIGHTS

The symptom of negative dysphotopsia occurring after cataract surgery is an interesting and not fully understood phenomenon, which is of interest not only to ophthalmology, but also to neurobiology.

## ABSTRACT

The aim of this review is to present the most recent knowledge, based on available references, about the problem of negative dysphotopsias, which occur after cataract surgeries. It seems however, despite being quite frequent when taking into account the number of cataract excisions, it lacks common knowledge. Up to this day, the principle of the symptom has a lot of unknowns. Surgical and non-surgical solutions used in cases of unacceptable levels of patient symptoms will be discussed.

**Key words:** negative dysphotopsia, cataract, phacoemulsification, IOL

## INTRODUCTION

The phenomenon of negative dysphotopsia (ND) is known for more than 20 years, when in 2000, Davison was the first one who described it [1]. It is worth mentioning that only a small group of researchers worldwide deal with this problem. Since 2000, relatively few publications were published – using the PubMed platform, after typing „negative dysphotopsia”, only 95 titles are shown.

The principle of the problem is the symptom of the pseudophakic patients, characterized by irritating shadow in the temporal visual field, which is usually crescent, permanent during daylight, in photopic conditions (fig. 1). It seems, the phenomenon is quite common – at the first week following surgery it is reported in up to 26% patients [2]. With time, perceived symptoms decrease so that after 1 year after surgery it ranges from 0.13% to 3.2% [3], after 5 years 1.5% patient are affected [4]. Kinetic perimetry, which range of peripheral visual field is up to 90°, is the only suitable tool for objective assessment of the scotomas that are the consequences of ND. The only accessible on the market, automated kinetic perimeter, capable of such examination, is Octopus 900 constructed by Haag-Streit. The evaluation can also be carried out by manual kinetic perimeter. The standard computerized static perimetry is not suitable for ND assessment, because of the too narrow examination of the visual field area [5, 6].

## ORIGINS OF NEGATIVE DYSPHOTOPSIA

Generally accepted theory explaining the genesis of the phenomenon is hypothesis of the loss of illumination in peripheral, nasal part of the retina. After the removal of crystalline lens and implantation of the artificial one, the substantial deepening of the anterior chamber is visible. Moreover, it creates space between the anterior surface of the implant and posterior plane of the iris, much bigger than noted in phakic eye. This is because of the significantly lower thickness of implanted lens [7]. Rays of light striking at open angle up to 105° of the visual field from the temporal, uncovered margin of the orbit or nose, penetrate the cornea through the anterior chamber and pupil to reach posterior chamber. Some of them, those of the steepest slopes, enter the gap between the iris and the implant and illuminate directly the nasal part of the retina. With the decrease of the angle of light, finally one of the beam hits the intraocular lens (IOL) optical portion refracting at larger angle. In consequence it strikes nasal retina, considerably posterior to the globe than the last, unrefracted light, which misses the implant. This results in forming a gap in illumination of the nasal part of the retina, followed by scotoma in peripheral, temporal portion of patient's visual field (fig. 2) [7–10].

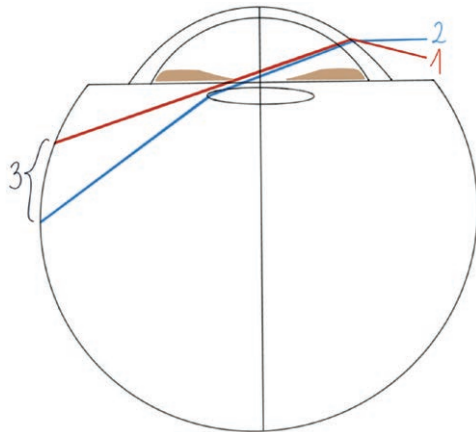
FIGURE 1

Negative dysphotopsia shadow in the temporal part of field of vision.



FIGURE 2

Theory explaining the genesis of ND: 1. The ray entering the gap between the iris and the implant and illuminating directly the nasal part of the retina. 2. The ray hitting the surface of the IOL and refracted at a larger angle. 3. The gap in illumination of the nasal part of the retina.

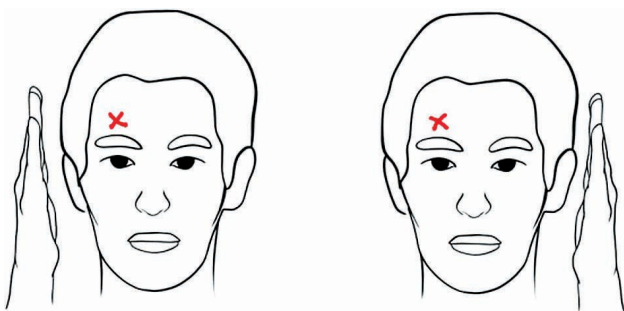


Technically the theory mentioned above would exhaustively explain the phenomenon of ND if it wasn't for the interesting and yet not fully defined observations related to this issue. It was noticed in patients who experienced ND in the right eye that covering its' temporal part of the visual field e.g. with hand would make the noticed shadow disappear, which is the logical consequence of the interruption of the light rays travelling from the temporal visual field according to the theory quoted. Interestingly though, if the patient obscure the left temporal visual field, in the same manner as above, leaving the right temporal vision exposed to light, the irritating shadow in the right eye would also vanish (fig. 3).

This observation was confirmed in experiment where researchers put on the fellow eye special contact lens, which covered periphery of the visual field. After its application, ND scotomas of the affected, uncovered eye, were statisti-

FIGURE 3

The paradox in the manifestation of ND – the shadow also disappears when the fellow eye is covered.



cally smaller than primary when the fellow eye wasn't wearing contact lens [11]. Authors describe this paradox by existence of undefined central and neuroadaptive mechanisms that control this phenomenon [12]. Few unexplained observations in this field support this argument, namely never were the ND perceived in monocular patients, but in binocular ones, usually occur only in one eye. It was alleged that statistically ND more often encounter women, usually in left eye. We don't know why ND occurs only in some patients and why it sometimes becomes persistent [3, 4, 13].

## LITERATURE REVIEW

Therefore, ND still remains the subject of researches and publications. A review of the available literature indicates 3 trends in researches on the phenomenon in question. The first are methods using computer modeling, in which digital models of the eye are used to analyze the path of light rays through particular structures of the globe. Relationships related to their size, shape, refractive index, etc. are examined here. The second are researches on patients who experienced this phenomenon, consisting of accurate biometric measurements of their eyes, with an attempt to find differences in measurement between them and control groups. The third technique is a combination of the two previous methods, i.e. confirmation attempts of clinical data collected from patients in digital models, as important in genesis of ND.

A number of studies conducted so far have resulted in the identification of risk factors that potentially predispose to the occurrence of ND. They can be grouped as factors related to the patient's anatomical features, the properties of the inserted implants and the surgical technique.

Thus, both in digital models and in observations of patients with ND, it was confirmed that a small pupil, hyperopia, a large kappa angle, expressed by pupil decentration, and an oblique configuration of the anterior chamber with a tilt of the iris plane towards the temple predispose to the occurrence of this phenomenon. Of course, a shallow orbit and proptosis play a role in ND by allowing easier penetration of light rays coming from the temporal part of the visual field [2, 7, 8, 14–16].

Studies using magnetic resonance imaging did not confirm the relationship between the configuration of the peripheral, nasal part of the retina, expressed by its distance from the ora serrata and the occurrence of the ND [17].

When it comes to IOLs, computer modeling indicates as risk factors features such as the small size of the optics [18, 19] and the bi-convex shape of the lens compared to the plano-convex shape, where one of the surfaces is flat [8]. However, regardless of the implant shape, the risk of ND occurrence rises with the optical power of the implant. The refractive index of the material, the IOLs are manufactured,

is also important. Digital methods prove that when using a material with a high refractive index, a much larger area of unilluminated peripheral retina is involved than when using a material with a low index [7, 8]. This is acknowledged by clinical observations, where the percentage of ND occurrence in patients who had low refractive index, silicone IOLs implanted, were much lower than patients with hydrophobic acrylic ones [13, 20]. Mathematical models also show the advantage of the rounded edge of the optical part of the implant over its sharp edge, which generates an optical shadow that may be responsible for the ND phenomenon. Furthermore, at least theoretically, it can be argued that the negative spherical aberration of the IOLs may slightly increase the risk of ND [8].

Aspects related to surgical technique have also been proven to be crucial in the development of ND. Primarily, none of ND were observed in patients in whom an IOLs was placed in the ciliary sulcus [21–23]. This solution is obviously not a standard one in cataract surgery and probably won't be. But it nevertheless provides some clue regarding the genesis of ND. This position of the IOL reduces the distance between the anterior surface of the IOL and the posterior plane of the iris, mechanism which was mentioned earlier in terms of the risk of ND. Importantly, it also eliminates the anterior capsule overlying the front surface of implant. It was observed that the removal of this capsule in the nasal area of the IOL using the Nd:YAG laser resulted in an 60% improvement in reduction of symptoms in patients with ND [24]. This confirms the thesis that optical phenomenon resulting from the presence of a significant part of the anterior capsule in front of the IOL on the nasal side may be important in generating ND [8,13,23].

Thanks to the use of computer techniques and clinical observations, it has been proven that horizontal orientation of the IOL haptic, so that light rays coming from the temples hit the IOL junction of the optics and haptics, not only the edge of the optical part, significantly reduces the risk of adverse symptoms. Digital modeling shows that the scattering of light rays by the optic-haptic link may expand the area of the unilluminated peripheral retina, but shifts the region forward, to the ora serrata and blurs its boundaries [25]. In clinical studies, twofold reduction in the incidence of ND was observed with such setting [25, 26]. Therefore, during cataract surgery, whenever possible, it is recommended to position the lens implant in a way that ensures that the optic-haptic junction is located on the nasal side.

No relationship has been confirmed between the location of the corneal incision, temporal, nasal or superior, or the incision in the scleral tunnel and the incidence of ND, both in short-term and persistent forms of the phenomenon [21, 27]. However, attention is attracted to the significance of hydration of the surgical wound as a factor that may boost the risk of short-term ND [3, 4].

The described researches and observations constitute important guidelines for the further development of medical technology in the field of IOL construction, as well as our everyday outpatient and surgical practice. So far, several IOL solutions have been implemented to diminish the risk of negative dysphotopsias. The assumption of their design is to eliminate the presence of an anterior capsule on the front surface of the IOL. The idea behind this is to place the edge of the capsulorrhexis within the implant, leaving the front optical surface free. Examples include the Tassignon lens, the Morcher 90S lens or the Fentis lens from Oculentis [27–29]. Then, a special optical ring implanted in the ciliary sulcus, in front of the primary implant, covers the edge of the capsulorrhexis. The ring construction resembles a 4-haptic lens without a central optic [30]. One of the ideas is to use lenses with an ellipsoidal optics, while oriented horizontally with the major axis, significantly increase the nasal and temporal size of the optics [31].

The authors' observations regarding the management of patients who complain of symptoms of ND are valuable. First of all, we should settle such people down and assure them that the symptom is harmless and transient. Glasses with wide frames limiting the propagation of light from the temporal side may be helpful in therapeutic procedure [3]. Moderate mydriasis using topical eyedrops also provides relief [24, 32]. In early surgical management, removal of the anterior capsule from the IOL surface on the nasal side using an Nd:YAG laser can be considered [24, 33]. It seems that the proposed "pitting" with an Nd:YAG laser in the nasal part of the IOL in order to induce optical irregularities that scatter the light reaching the nasal retina is not an ideal solution due to the risk of positive dysphotopsias [34, 35]. What is worth mentioning with ND, is the fact that posterior Nd:YAG capsulotomy will not resolve patient's symptoms and is not recommended. It is also valid in the context of compromising the integrity of the posterior capsule, which will probably constitute a serious difficulty if the implant needs to be replaced [3, 36].

However, if the symptoms of ND do not subside after 3–6 months following the operation, surgical intervention may be offered to the patient. One of the proposed, relatively non-invasive and low-cost methods is the reverse optical capture (ROC) technique. The technique consists of translocation of the optics anteriorly to the capsulorrhexis, leaving the haptics in the lens capsule. This way, we eliminate the presence of the anterior capsule in front of the IOL and slightly reduce the optical gap between the implant and the iris. Of course, this maneuver requires proper conditions – capsulorrhexis of the appropriate size and shape and haptics of the lens that meet the requirements – 2 arms, not, for example, 4. Moving the IOL in front of the capsulorrhexis that is slightly further from the retina, increases its relative optical power and, consequently, shifts it towards

myopia. However, as it turns out, it is usually rather small and in emmetropic eyes it is around 0.2 Dsph. Worth mentioning is the fact that ROC generates rapidly progressive posterior capsule opacification of the lens, requiring laser capsulotomy [13, 23].

A potentially safe surgical solution may be the implantation of another IOL placed in the ciliary sulcus, anteriorly to the originally implanted lens. This method, called the “piggy back” technique, also requires appropriate anatomical conditions. Here we also eliminate the presence of the anterior capsule in front of the IOL and reduce the optical gap between it and the iris. We can use commercially available IOLs, used to correct residual refractive errors after the primary procedure, achieving reduction of the symptoms in 73% patients [32]. On the similar principle works implantation of the sulcus-fixated ring, mentioned above. The method seems to be very effective, completely eliminating symptoms in 93% of patients. It is also relatively simple, what is emphasized by the authors [30].

We can also decide to replace the lens, using as a secondary IOLs a silicone one with a rounded optical edge fixated in the ciliary sulcus, or one of the technologically advanced IOL described and proposed earlier [14, 21, 22].

Although, as mentioned before, the symptoms of ND usually occur in one eye, if the patient has a problem in the first eye, when planning surgery on the second one, we should consider the initial use of one of the preventive solutions related to ND. Undoubtedly, primary use of the ROC technique or primary insertion of a three-piece IOL into the ciliary sulcus can be considered. Implantation, of one of the mentioned, special IOLs may also be planned.

## CONCLUSION

To conclude, it should be stated that ND after cataract surgeries are quite common, although not fully understood, have their source in the optical determinants of the pseudophakic eye, yet probably also controlled centrally. Fortunately, due to the short-term nature of the symptoms in majority of patients, as well as the established therapeutic methods of treatment, in those patients in whom those signs persist, phenomenon doesn't seem to be dangerous. Undoubtedly, in clinical practice we should consider the risk of ND occurring in our patients, as well as know its genesis and therapeutic options for providing appropriate help.

*Figures: from the author's own materials.*

## CORRESPONDENCE

**Marcin Jeziński, MD, PhD**

Department of Ophthalmology, Military Institute of Aviation Medicine  
01-755 Warszawa, ul. Krasińskiego 54  
e-mail: mjeziński@wiml.waw.pl

## ORCID

Marcin Jeziński – ID – <https://orcid.org/0009-0005-6989-1360>  
Piotr Dobrowolski – ID – <https://orcid.org/0009-0009-8108-9361>

## References

1. Davison JA. Positive and negative dysphotopsia in patients with acrylic intraocular lenses. *J Cataract Refract Surg.* 2000; 26: 1346-55.
2. Makhotkina NY, Nijkamp MD, Berendschot TTJM et al. Effect of active evaluation on the detection of negative dysphotopsia after sequential cataract surgery: Discrepancy between incidences of unsolicited and solicited complaints. *Acta Ophthalmol.* 2018; 96: 81-7.
3. Osher RH. Negative dysphotopsia: Long-term study and possible explanation for transient symptoms. *J Cataract Refract Surg.* 2008; 34: 1699-707.
4. Sharma P, Kalia S, Chouhan JK. Incidence and causes of negative dysphotopsia after uncomplicated cataract surgery – A randomized clinical trial. *Indian J Ophthalmol.* 2021; 69: 1786-91.
5. Makhotkina NY, Berendschot TTJM, Nuijts RMMA. Objective evaluation of negative dysphotopsia with Goldmann kinetic perimetry. *J Cataract Refract Surg.* 2016; 42: 1626-33.
6. Rozendal LRW, van Vught L, Luyten GPM et al. The Value of Static Perimetry in the Diagnosis and Follow-up of Negative Dysphotopsia. *Optom Vis Sci.* 2022; 99(8): 645-51.
7. Holladay JT, Zhao H, Reisin CR. Negative dysphotopsia: The enigmatic penumbra. *J Cataract Refract Surg.* 2012; 38: 1251-65.
8. Holladay JT, Simpson MJ. Negative dysphotopsia: Causes and rationale for prevention and treatment. *J Cataract Refract Surg.* 2017; 43: 263-75.
9. Simpson MJ. Intraocular lens far peripheral vision: image detail and negative dysphotopsia. *J Cataract Refract Surg.* 2020; 46(3): 451-8.
10. Erie JC, Simpson MJ, Bandhauer MH. Influence of the intraocular lens optic-haptic junction on illumination of the peripheral retina and negative dysphotopsia. *J. Cataract Refract Surg.* 2019; 45: 1335-9.
11. Masket S, Rupnik ZM, Fram NR et al. Binocular Goldmann visual field testing of negative dysphotopsia. *J Cataract Refract Surg.* 2020; 46: 147-8.

12. Masket S, Rupnik Z, Fram NR. Neuroadaptive changes in negative dysphotopsia during contralateral eye occlusion. *J Cataract Refract Surg.* 2019; 45: 242-3.
13. Masket S, Fram NR, Cho A et al. Surgical management of negative dysphotopsia. *J Cataract Refract Surg.* 2018; 44: 6-16.
14. Henderson BA, Geneva II. Negative dysphotopsia: A perfect storm. *J. Cataract Refract Surg.* 2015; 41: 2291-312.
15. van Vught L, Luyten GPM, Beenakker JWM. Distinct differences in anterior chamber configuration and peripheral aberrations in negative dysphotopsia. *J. Cataract Refract Surg.* 2020; 46: 1007-15.
16. Karhanová M, Pluháček F, Mlčák P et al. The importance of angle kappa evaluation for implantation of diffractive multifocal intra-ocular lenses using pseudophakic eye model. *Acta Ophthalmol.* 2015; 93: e123-8.
17. van Vught L, Dekker CE, Stoel BC et al. Evaluation of intraocular lens position and retinal shape in negative dysphotopsia using high-resolution magnetic resonance imaging. *J Cataract Refract Surg.* 2021; 47: 1032-38.
18. Erie JC, Simpson MJ, Mahr MA. Effect of a 7.0 mm intraocular lens optic on peripheral retinal illumination with implications for negative dysphotopsia. *J. Cataract Refract Surg.* 2022; 48: 95-9.
19. Bonsemeyer MK, Becker E, Liekfeld A. Dysphotopsia and functional quality of vision after implantation of an intraocular lens with a 7.0 mm optic and plate haptic design. *J Cataract Refract Surg.* 2022; 48: 75-82.
20. Masket S, Rupnick Z, Fram NR et al. Surgical management of positive dysphotopsia: U.S. perspective. *J. Cataract Refract Surg.* 2020; 46: 1474-9.
21. Vámosi P, Csákány B, Németh J. Intraocular lens exchange in patients with negative dysphotopsia symptoms. *J. Cataract Refract Surg.* 2010; 36: 418-24.
22. Burke TR, Benjamin L. Sulcus-fixated intraocular lens implantation for the management of negative dysphotopsia. *J Cataract Refract Surg.* 2014; 40: 1469-72.
23. Masket S, Fram NR. Pseudophakic negative dysphotopsia: Surgical management and new theory of etiology. *J Cataract Refract Surg.* 2011; 37: 1199-207.
24. Folden DV. Neodymium: YAG laser anterior capsulectomy: Surgical option in the management of negative dysphotopsia. *J Cataract Refract Surg.* 2013; 39: 1110-5.
25. Henderson BA, Yi DH, Constantine JB et al. New preventative approach for negative dysphotopsia. *J Cataract Refract Surg.* 2016; 42: 1449-55.
26. Manasseh GSL, Pritchard EWJ, Rothwell AEJ et al. Pseudophakic negative dysphotopsia and intraocular lens orientation: A prospective double-masked randomized controlled trial. *Acta Ophthalmol.* 2020; 98: 14368.
27. Bhalla JS, Gupta S. Dysphotopsia – Unraveling the Enigma. *Off Sci J Delhi Ophthalmol Soc.* 2016; 27: 97-101.
28. Rupnik Z, Elekes A, Vámosi P. Clinical experience with an anti-dysphotopic intraocular lens. *Saudi J Ophthalmol.* 2022; 36(2): 183-8.
29. Darian-Smith E, Versace P. Visual performance and positional stability of a capsulorhexis-fixated extended depth-of-focus intraocular lens. *J Cataract Refract Surg.* 2020; 46(2): 179-87.
30. Roop P, Nayak S, Kittur A et al. Evaluation of a new device to treat negative dysphotopsia. *J Cataract Refract Surg.* 2024; 50(2): 122-7.
31. Taubenslag KJ, Groos EB, Parker MG et al. Successful treatment of negative dysphotopsia with in-the-bag intraocular lens exchange using a wide ovoid IOL. *Cataract Refract Surg.* 2016; 42(2): 336-7.
32. Erie JC, Simpson MJ, Bandhauer MH. Effect of a sulcus-fixated piggyback intraocular lens on negative dysphotopsia: Ray-tracing analysis. *J Cataract Refract Surg.* 2019; 45: 443-50.
33. Cooke DL, Kasko S, Platt LO. Resolution of negative dysphotopsia after laser anterior capsulotomy. *J. Cataract Refract Surg.* 2013; 39: 1107-9.
34. Feng Y, Weinlander E, Shah M. Targeted Lens Pitting to Treat Negative Dysphotopsia. *J Refract Surg.* 2021; 37: 212-4.
35. Bath PE, Dang Y, Martin WH. Comparison of glare in YAG-damaged intraocular lenses: Injection-molded versus lathe-cut. *J Cataract Refract Surg.* 1986; 12: 662-4.
36. Stulting DR. Cataract surgical problem: April Consultation #2. *J Cataract Refract. Surg.* 2005; 31: 651-2.

**Authors' contributions:**

All authors have equal contribution to the paper.

**Conflict of interest:**

None.

**Financial support:**

None.

**Ethics:**

The content presented in the article complies with the principles of the Helsinki Declaration, EU directives and harmonized requirements for biomedical journals.