

Long-term effects of epithelium-off corneal cross-linking in keratoconus therapy



Magdalena Maleszka-Kurpiel^{1,2}, Aleksandra Jackowiak³,
Marta Robak¹

¹Optegra Eye Health Care Clinic in Poznan
Medical Director: Jolanta Oficjalska, MD, PhD

²Department of Optometry, Chair of Ophthalmology and Optometry, Poznan University of Medical Sciences
Head: prof. Wojciech Warchoł, MD, PhD

³Poznan University of Medical Sciences
Head: prof. Zbigniew Krasieński, MD, PhD

HIGHLIGHTS

The corneal cross-linking treatment has proven effectiveness in inhibiting the progression of keratoconus, but its long-term effects on visual acuity and flattening of the cornea cannot be predicted.

ABSTRACT

Background: We report a well-documented cases of progressive corneal flattening and visual improvement after epithelium-off corneal cross-linking (epi-off CXL) for keratoconus with long-term follow-up.

Case report: Two young men reported with deterioration of vision and diagnosed keratoconus few months earlier. Corneal tomography confirmed the previous diagnosis. Considering the age of the patients it was decided to perform epi-off CXL in both eyes. Based on several years of observation, no progression of the disease has been observed. In both cases, good visual acuity is maintained, what is unexpected the reduction in the maximum keratometry reading is still flattening also corneal thickness is reduced.

Conclusion: Continuous long-term flattening and corneal thinning after corneal cross-linking seems to be unpredictability in some cases. Our report highlights the importance of long-term evaluation of crosslinking techniques.

Key words: keratoconus, corneal cross-linking, CXL, epithelium-off corneal cross-linking, epi-off CXL, corneal flattening

INTRODUCTION

Keratoconus (KC) is a non-inflammatory, progressive, chronic corneal disease that leads to loss of corneal stiffness causing steepening, thinning and irregularity leading to significant deterioration of vision [1]. The disease begins at puberty and progresses through the third–fourth decades of life. Most affected patients are males [2, 3]. The main risk factors for the disease include genetic factor [4, 5], atopy [6] and eye rubbing [7, 8].

The prevalence of KC depends on geographical zones, age and classification and varies from 1/223 in USA [9] to 1/10 in Greece [10] based on the latest data. According to recent reports, the incidence of the disease in the adult Polish population is 549 per 100,000 [11].

The development of diagnostic tools allows the diagnosis of the KC at early stage of advancement than before. The gold standard in KC diagnosis is corneal tomography. Currently available anterior segment OCT (AS-OCT) with high resolution [12] allowing the separation of the thickness of the corneal epithelium. Focal thinning of the corneal epithelium coinciding with the steepest point of the cornea is the first sign of change towards KC preceding a decrease in visual acuity [13]. Another early KC signs is inter-eye asymmetry in keratometry, pachymetry and refraction [14].

A well-documented method of corneal stabilization is the corneal cross-linking procedure (CXL) [15–17]. The procedure consists of soaking the corneal tissue with vitamin B₂ – riboflavin and exposing it to UV-A light (wavelength of 365 nm). New connections between the amino groups resulting from photopolymerization increase the stiffness and mechanical resistance of the cornea [18].

Is still unknown when the procedure fail, how cornea will change during the long period of time, and which preoperative parameters may help us to predict final effect [19].

As shown by recent reports presented during the ARVO 2024 conference, by Hwang et al. only 1.2% of keratoconic eyes required either repeat treatment or corneal graft surgery, but the CXL procedure's failure was more likely to occur with allergies, atopic disease in the patient history [20].

We have to remember that CXL procedure is used to stop progression of the KC and strength cornea, it is our goal.

There are some long-term studies, they confirms stabilization of KC after CXL with improvement in keratometry which was maintained at 10years [21].

The CXL treatment has been around since 2003, recent years have brought us many CXL options and CXL devices, but we still must learn and observe results, especially the long-term effects, they may be excessive, as in our two cases, but rarely the treatment may failure.

The challenge is to diagnose the disease at the earliest possible stage and implement appropriate treatment and maintaining good quality of vision.

The aim of the article was to present unexpectedly excessive long-term functional results based on keratometric measurements, spherical and cylindrical equivalent values, and visual acuity in patients with KC after the use of the accelerated epi-off CXL technique.

CASE 1.

19-years-old man came to the clinic Optegra Poznań in 2018 with deterioration of vision, especially in right eye and KC diagnosed 3 months earlier.

Visual acuity was 0.9 cc sph +1.75, cyl -2.50 ax 72° on right eye and 1.1 cc sph +0.50 cyl -0.50 ax 90° on left eye.

Ophthalmological examination revealed no abnormalities on posterior pole. Based on corneal tomography performed on WaveLight Oculyzer II (Alcon) KC in both eyes was diagnosed, more advanced in right eye (fig. 1).

Corneal cross-linking was performed in accordance with the accelerated protocol (epi-off procedure, 12 min of irradiance) [22, 23] in both eyes 2 and 3 months later. After CXL topical antibiotics, steroids and a bandage lens were applied. No complications were recorded.

During follow-up visits parameters like: steepest keratometry (K_{max}), central corneal thickness (CCT), visual acuity (VA) and manifest refraction in Snellen notation (Rx, sph/cyl/axis) and corneal tomography were analyzed (tab. 1).

TABLE 1

Case 1. Analysis of selected pre-op and post-op parameters of the cornea, visual acuity and refraction of both eyes.

CASE 1								
	Right eye				Left eye			
	K_{max}	CCT	VA	Rx	K_{max}	CCT	VA	Rx
Pre-op	54.7	460	0.9	+1.75/-2.50/72	46.1	501	1.1	+0.50/-0.50/90
CXL Right eye / Left eye								
1-year post-op	51.2	402	0.9	+1.25/-1.00/68	45.2	444	1.0/1.1	plano
2 years post-op	45.3	384	0.9	-0.25/-0.75/5	42.5	425	1.1	plano
3 years post-op	44.4	381	0.9	0.00/-0.50/25	42.3	420	1.1	+0.75/0/0
4 years post-op	43.6	391	1.1	plano	42.3	422	1.1	plano

FIGURE 1

Case 1. Preoperative exam. Axial curvature (front) map WaveLight Oculyzer II, right/left eye.

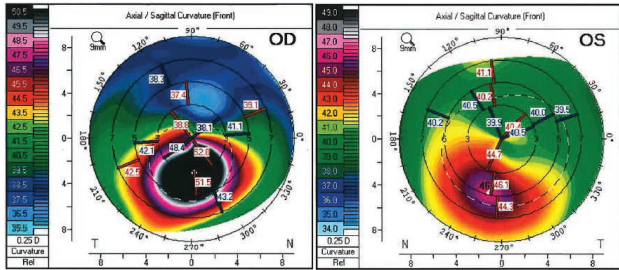


FIGURE 2

Case 1. Axial curvature (front) map Pentacam (Oculus). Compare map 2 years and 4 years postoperative exam. Right eye.

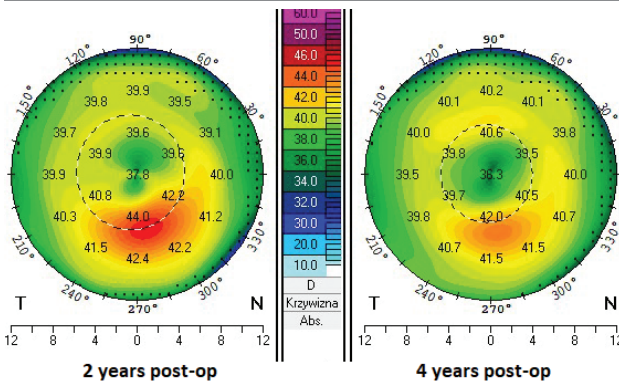
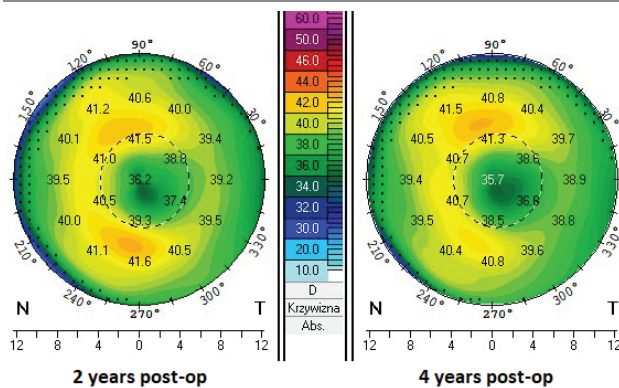


FIGURE 3

Axial curvature (front) map Pentacam (Oculus). Compare map 2 years and 4 years postoperative exam. Left eye.



Four years after the procedure, corneal flattening based on K_{max} measurement is observed, respectively 10.5 D and 3.8 D in right eye and left eye. There are no signs of disease progression such as: decrease in corneal thickness, increase

in keratometry, increase anterior and posterior elevation. High, stable visual acuity is maintained (fig. 2, 3).

CASE 2.

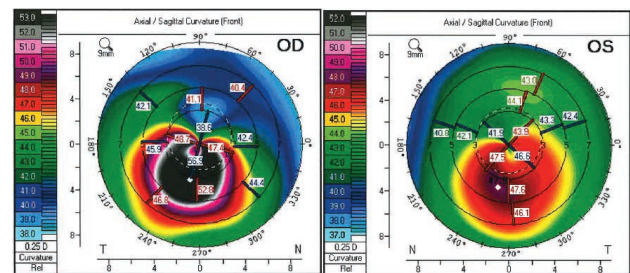
23-years-old men came to the clinic Optegra Poznań with diagnosis of KC.

Visual acuity was 0.8 cc sph 0.00, cyl -1.50 ax 70° on right eye and 1.1 cc sph +0.50 cyl -1.00 ax 90° on left eye.

Ophthalmological examination revealed no abnormalities. Corneal tomography performed on WaveLight Oculyzer II (Alcon) confirmed the diagnosis of KC in both eyes, more advanced in the right eye (fig. 4). Corneal cross-linking (epi-off procedure, 12 min of irradiance) was performed in the right eye, 1 month later in the left eye. Standard postoperative care was applied. No postoperative complications were reported.

FIGURE 4

Case 2. Preoperative exam. Axial curvature (front) map WaveLight Oculyzer II, right/left eye.



Selected tomographic data and visual acuity data has been collected in table 2.

During the 5-year observation period, the corneal epithelial profile changed, especially in the more advanced eye, the right one. Further corneal flattening (7.3 D and 3.2 D in the right and left eye) and stable visual acuity are observed (fig. 5–12).

The cornea was clear without opacity postoperatively.

DISCUSSION

CXL is a procedure initiated in 2003, which significantly changed the prognosis in the case of KC. A few years after the procedure was popularized, the percentage of patients requiring corneal transplantation due to cornea decreased significant [24]. According to *The Global Consensus on Keratoconus and Ectatic Diseases* in pediatric and young adults CXL should be performed as soon as possible after diagnosis, documentation clinical progression of disease is not mandatory. After the procedure, corneal parameters change and require constant observation.

TABLE 2

Case 2. Analysis of selected pre-op and post-op parameters of the cornea, visual acuity and refraction of both eyes.

CASE 2	Right eye				Left eye			
	K _{max}	CCT	VA	Rx	K _{max}	CCT	VA	Rx
Pre-op	56.9	464	0.8	0.00/-1.50/70	47.9	489	1.1	+0.50/-1.00/90
CXL Right eye / Left eye								
2 years post-op	53.4	460	1.0	0.00/-1.00/85	46.4	479	1.1	+0.50/-0.50/90
3 years post-op	52.0	461	0.9	+0.25/-1.25/65	46.3	472	1.1	+0.75/-0.75/90
4 years post-op	52.0	454	0.9	-0.25/-1.50/80	45.8	475	1.1	+0.50/-0.50/90
5 years post-op	49.6	458	1.1	+0.50/-1.50/90	44.7	461	1.1	+1.75/-1.25/100

FIGURE 5

Case 2. Axial curvature (front) map Pentacam (Oculus). Compare map 2 years and 5 years postoperative exam. Right eye.

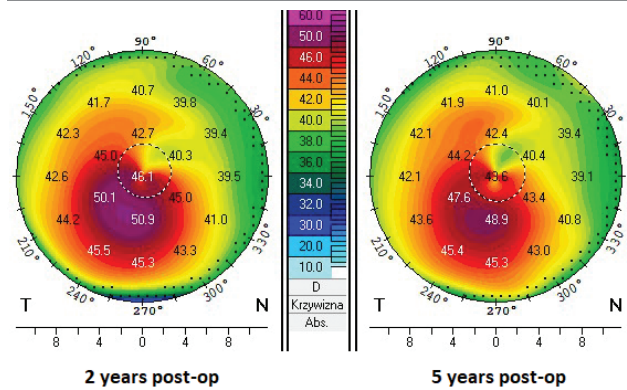


FIGURE 7

Case 2. Axial curvature (front) map MS-39 (CSO). Compare map 2 years and 4 years postoperative exam. Right eye.

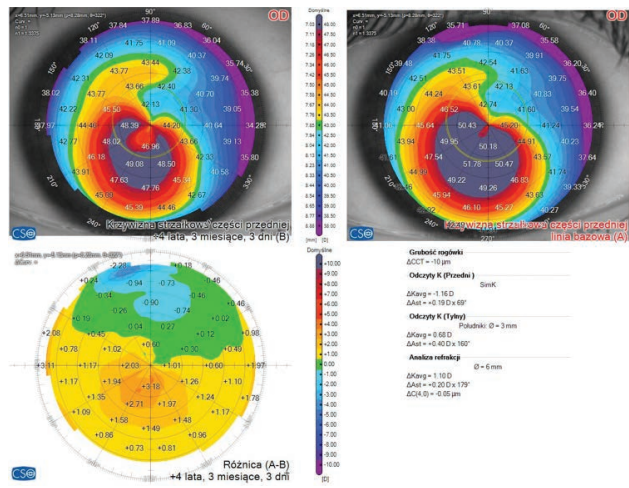


FIGURE 6

Case 2. Axial curvature (front) map Pentacam (Oculus). Compare map 2 years and 5 years postoperative exam. Left eye.

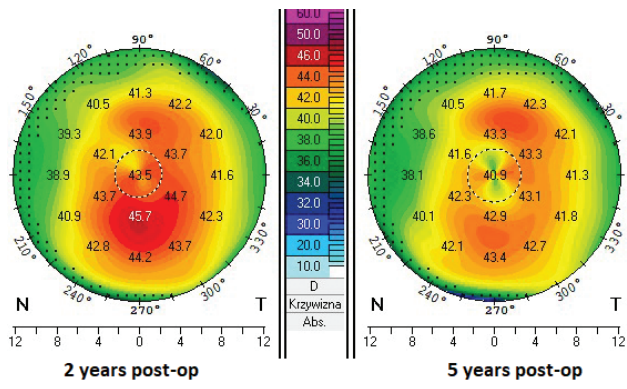


FIGURE 8

Case 2. Axial curvature (front) map MS-39 (CSO). Compare map 2 years and 4 years postoperative exam. Left eye.

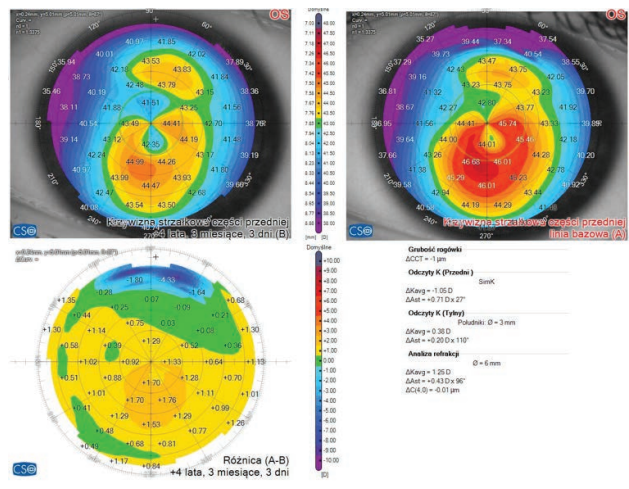


FIGURE 9

Case 2. Epithelial map MS-39 (CSO). Compare map 2 years and 4 years postoperative exam. Right eye.

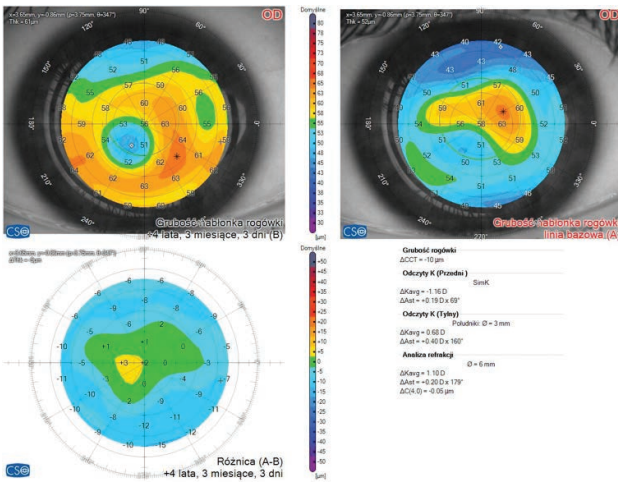
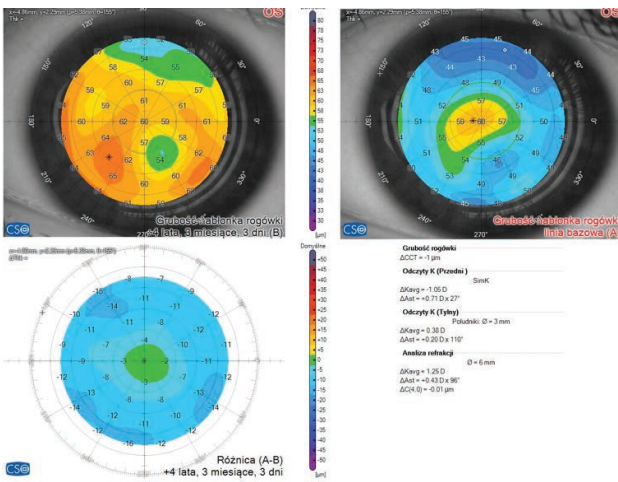


FIGURE 10

Case 2. Epithelial map MS-39 (CSO). Compare map 2 years and 4 years postoperative exam. Left eye.



Corneal flattening is well-described after CXL for KC, with a mean flattening of 1.6 D after one year and up to 3 D observed after 5 years [25]. In our case 1 it was respectively 10.5 D and 3.8 D in right eye and left eye, and in case 2, 7.3 D and 3.2 D in the right and left eye.

The greatest flattening of the cornea occurred in the first 2 years after the procedure. In the following years of observation, changes in the K_{max} parameter decreased. A similar characteristic of the K_{max} change over time, here stabilization of K_{max} in the period of 1 to 3 years after the procedure, was observed in the study Nicula et al. [21]. In the cited study, inhibition of KC progression was noted in the 10-year follow-up period. Our observations allow drawing conclusions from the 5-year follow-up period.

FIGURE 11

Case 2. Postoperative AS-OCT – cornea. Right eye.

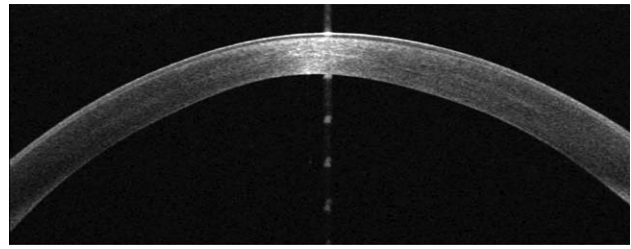
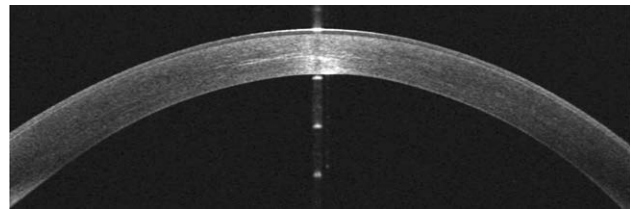


FIGURE 12

Case 2. Postoperative AS-OCT – cornea. Left eye.



Kymionis et al. [26] was the first to report excessive flattening in only one eye of a KC patient who underwent CXL in both eyes, and with documented haze on AS-OCT. In our cases we didn't observe haze that would explain so excessive flattening.

Santhiago et al. reported two cases of progressive flattening after CXL, but both with a K_{max} of 64 D. In our case, the patient 1 had a K_{max} of 54.7 D (right eye) and 46.1 D (left eye), and patient 2 56.9 D and 47.9 D [27].

Seifert et al. [28] observed a tendency toward cornea thickening beyond 5 years after CXL, up to 5 years post-CXL, the median thickness was reduced and almost returned to baseline after 10 years. Caporossi et al. also reported an increase in corneal thickness during the 4-year postoperative period [29].

In our cases we observed CCT significant decreased after the CXL procedure. A minor process of thickness increase is observed in 3 of the 4 eyes discussed after 4–5 years after surgery. We need longer observation to clearly observe this trend.

Analyses of Wittig-Silva et al. indicated that pachymetry measured by ultrasound did not reveal changes in corneal thickness in 3-year follow-up [30]. In our group CCT was checked based on in Scheimpflug imaging what can underestimate the corneal thickness [31].

Our observation is consistent with studies that suggest epithelial regularization (i.e., the maximum–minimum epithelial thickness difference is reduced) occurs after CXL [32, 33]. This regularization might indicate an improvement of the condition. In the keratoconic eyes, Reinstein et al. reported that the corneal epithelium tends to be thinner

over the apex and thicker over the adjacent areas, after cross-linking this profile remain the same [33]. This could slightly mask flattening of the underlying stroma. It is worth to highlight that visual acuity of our patients stay maintained at very good quality. That's why quick diagnosis prevents patients from lowered quality of vision.

CONCLUSION

KC is a disease that, in its early stages of development, despite changes in refraction, may not reduce BCVA (best corrected visual acuity). Early diagnosis of the disease allows the use of procedures whose effectiveness has been proven and maintaining good visual acuity. Some parameters such as corneal flattening and thinning changes for long time after CXL. It would be of interest for patients and physicians to identify preoperative parameters that predict such flattening and how it changes visual acuity remain to be elucidated we need more study.

Figures: from authors' own materials.

CORRESPONDENCE

Magdalena Maleszka-Kurpiel, MD, PhD

Optegra Eye Health Care Clinic
61-101 Poznań, ul. Wenecjańska 8
e-mail: m.maleszka-kurpiel@optegra.com.pl

ORCID

Magdalena Maleszka-Kurpiel – ID – <http://orcid.org/0000-0001-7307-8333>

References

1. Rabinowitz YS. Keratoconus. *Surv Ophthalmol*. 1998; 42: 297-319.
2. Li X, Rabinowitz YS, Rasheed K et al. Longitudinal study of the normal eyes in unilateral keratoconus patients. *Ophthalmology*. 2004; 111: 440-6.
3. Wagner H, Barr JT, Zadnik K. Collaborative longitudinal evaluation of keratoconus (CLEK) Study: methods and findings to date. *Contact Lens Anterior Eye*. 2007; 30: 223-32.
4. Loukovitis E, Sfakianakis K, Syrmakesi P et al. Genetic aspects of keratoconus: a literature review exploring potential genetic contributions and possible genetic relationships with comorbidities. *Ophthalmol Ther*. 2018; 7: 263-92.
5. Kabza M, Karolak JA, Rydzanicz M et al. Multiple differentially methylated regions specific to keratoconus explain known keratoconus linkage loci. *Invest Ophthalmol Vis Sci*. 2019; 60: 1501-9.
6. Zadnik K, Barr JT, Edrington TB et al. Baseline findings in the Collaborative Longitudinal Evaluation of Keratoconus (CLEK) Study. *Invest Ophthalmol Vis Sci*. 1998; 39: 2537-46.
7. Balasubramanian SA, Pye DC, Willcox MD. Effects of eye rubbing on the levels of protease, protease activity and cytokines in tears: relevance in keratoconus. *Clin Exp Optom*. 2013; 96: 214-8.
8. Jaskiewicz K, Maleszka-Kurpiel M, Michalski A et al. Non-allergic eye rubbing is a major behavioral risk factor for keratoconus. *PLoS One*. 2023; 18(4): e0284454. <http://doi.org/10.1371/journal.pone.0284454>.
9. Harthan JS, Gelles JD, Block SS et al. Prevalence of Keratoconus Based on Scheimpflug Corneal Tomography Metrics in a Pediatric Population From a Chicago-Based School Age Vision Clinic. *Eye Contact Lens*. 2024; 50(3): 121-5. <http://doi.org/10.1097/ICL.0000000000001072>.
10. Kanellopoulos AJ, Kanellopoulos AJ. Topographic Keratoconus Incidence in Greece Diagnosed in Routine Consecutive Cataract Procedures: A Consecutive Case Series of 1250 Cases over 5 Years. *J Clin Med*. 2024; 13(8): 2378. <http://doi.org/10.3390/jcm13082378>.
11. Kanclerz P, Przewłócka K, Toprak I et al. The prevalence of keratoconus in northern Poland: A cross-sectional study of patients from a primary healthcare practice. *Cont Lens Anterior Eye*. 2023; 46(4): 101846. <http://doi.org/10.1016/j.clae.2023.101846>.
12. Alghamdi A, Khan MS, Dakhil TA. Understanding Corneal Epithelial Thickness Mapping. *Middle East Afr J Ophthalmol*. 2023; 29(3): 147-55. http://doi.org/10.4103/meajo.meajo_207_22.
13. Reinstein DZ, Archer TJ, Gobbe M. Corneal epithelial thickness profile in the diagnosis of keratoconus. *J Refract Surg*. 2009; 25: 604-10.
14. Maleszka-Kurpiel M, Michalski A, Robak M et al. Inter-eye asymmetry in manifest refraction, keratometry and pachymetry in eyes with keratoconus. *Klinika oczna*. 2020; 122: 112-6.

15. Sarma P, Kaur H, Hafezi F et al. Short- and long-term safety and efficacy of corneal collagen cross-linking in progressive keratoconus: A systematic review and meta-analysis of randomized controlled trials. *Taiwan J Ophthalmol*. 2023; 13(2): 191-202. <http://doi.org/10.4103/2211-5056.361974>.
16. Meiri Z, Keren S, Rosenblatt A et al. Efficacy of Corneal Collagen Cross-Linking for the Treatment of Keratoconus: A Systematic Review and Meta-Analysis. *Cornea*. 2016; 35(3): 417-28. <http://doi.org/10.1097/ICO.0000000000000723>.
17. Maleszka-Kurpiel M, Michalski A, Robak M et al. Influence of corneal cross-linking on visual acuity and topometric indices in keratoconus. *Klinika Oczna/Acta Ophthalmologica Polonica*. 2020; 122(4): 165-70. <http://doi.org/10.5114/ko.2020.101652>.
18. Koller T, Mrochen M, Seiler T. Complication and failure rates after corneal crosslinking. *J Cataract Refract Surg*. 2009; 35: 1358-62.
19. Wen D, Li Q, Song B et al. Comparison of standard versus accelerated corneal collagen cross-linking for keratoconus: a metaanalysis. *Invest Ophthalmol Vis Sci*. 2018; 59: 3920-31.
20. Hwang B, Pecsok M, Cheng BT et al. Rates of Failure of Corneal Crosslinking for Keratoconus in the United States. *Invest Ophthalmol Vis Sci*. 2024; 65(7): 4569.
21. Nicula C, Pop R, Rednik A et al. 10-Year Results of Standard Cross-Linking in Patients with Progressive Keratoconus in Romania. *J Ophthalmol*. 2019; 2019: 8285649. <http://doi.org/10.1155/2019/8285649>.
22. Wollensak G, Spoerl E, Seiler T. Riboflavin/ultraviolet-a-induced collagen crosslinking for the treatment of keratoconus. *Am J Ophthalmol*. 2003; 135: 620-7.
23. Brittingham S, Tappeiner C, Frueh BE. Corneal cross-linking in keratoconus using the standard and rapid treatment protocol: differences in demarcation line and 12-month outcomes. *Invest Ophthalmol Vis Sci*. 2014; 55: 8371-6.
24. Godefrooij DA, Gans R, Imhof SM et al. Nationwide reduction in the number of corneal transplantations for keratoconus following the implementation of cross-linking *Acta Ophthalmol*. 2016; 94: 675-8.
25. Koller T, Pajic B, Vinciguerra P et al. Flattening of the cornea after collagen crosslinking for keratoconus. *J Cataract Refract Surg*. 2011; 37(8): 1488-92. <http://doi.org/10.1016/j.jcrs.2011.03.041>.
26. Kymionis GD, Tsoularas KI, Liakopoulos DA et al. Excessive Corneal Flattening and Thinning After Corneal Cross-linking: Single-Case Report With 5-Year Follow-up. *Cornea*. 2015; 34(6): 704-6.
27. Santhiago MR, Giacomini NT, Medeiros CS et al. Intense early flattening after corneal collagen cross-linking. *J Refract Surg*. 2015; 31(6): 419-22.
28. Seifert FK, Theuersbacher J, Schwabe D et al. Long-Term Outcome of Corneal Collagen Crosslinking with Riboflavin and UV-A Irradiation for Keratoconus. *Curr Eye Res*. 2022; 47(11): 1472-8. <http://doi.org/10.1080/02713683.2022.2117383>.
29. Caporossi A, Mazzotta C, Baiocchi S et al. Long-term results of riboflavin ultraviolet a corneal collagen cross-linking for keratoconus in Italy: the Siena eye cross study. *Am J Ophthalmol*. 2010; 149(4): 585-93. <http://doi.org/10.1016/j.ajo.2009.10.021>.
30. Wittig-Silva C, Chan E, Islam FM et al. A randomized, controlled trial of corneal collagen cross-linking in progressive keratoconus: three-year results. *Ophthalmology*. 2014; 121: 812-21.
31. Wu W, Wang Y, Xu L. Meta-analysis of Pentacam vs. ultrasound pachymetry in central corneal thickness measurement in normal, post-LASIK or PRK, and keratoconic or keratoconus-suspect eyes. *Graefes Arch Clin Exp Ophthalmol*. 2014; 252: 91-9.
32. Rocha KM, Perez-Straziota CE, Stulting RD et al. Epithelial and stromal remodeling after corneal collagen cross-linking evaluated by spectral-domain OCT. *J Refract Surg*. 2014; 30: 122-7.
33. Reinstein DZ, Gobbe M, Archer TJ et al. Epithelial thickness profile as a method to evaluate the effectiveness of collagen cross-linking treatment after corneal ectasia. *J Refract Surg*. 2011; 27: 356-63.

Authors' contributions:

M.M.K.: study design, preparation of tables, figures, writing of manuscript.

M.R.: preparation of tables, figures, writing of manuscript.

A.J.: preparation of tables, figures, writing of manuscript.

All authors contributed to critical revisions and approved the final version of the manuscript.

Conflict of interest:

None.

Financial support:

None.

Ethics:

The content presented in the article complies with the principles of the Helsinki Declaration, EU directives and harmonized requirements for biomedical journals.