

Diseases of the cornea and ocular surface – an optimal management



Monika Udziela^{1,2}

¹ Chair and Department of Ophthalmology, Faculty of Medicine, Medical University of Warsaw
Head: prof. Jacek P. Szaflik, MD, PhD

² Independent Public Clinical Ophthalmology Hospital in Warsaw
Head: prof. Jacek P. Szaflik, MD, PhD

HIGHLIGHTS

This paper discusses the ocular surface diseases, including iatrogenic dry eye disease, as well as prophylactic management and therapy.

ABSTRACT

The ocular surface diseases including dry eye disease are still increasing issue worldwide. Mild disorders are not sight threatening, but in advanced stages they may lead to serious complications. In some cases the treatment itself is the main cause for developing or aggravation of the dry eye disease, especially in patients with risk factors. The exact examination allows to avoid the misdiagnosis and to choose the optimal management.

Key words: ocular surface, cornea, ocular surface disease, dry eye disease, dexpanthenol

INTRODUCTION

In specialized nomenclature, the term “ocular surface” refers to the complex set of structures that constitute the protective apparatus of the eye and the surface of the eyeball. Thus, when referring to the ocular surface, we include the eyelids (along with their associated glands and eyelashes), the lacrimal apparatus, the conjunctiva of both the eyelid and the globe (primarily its epithelial layer), the tear film, and the cornea (primarily its epithelium). The term “ocular surface” also encompasses the blood and lymphatic vessels, the immune system, and the innervation of the aforementioned structures. Ocular surface disease refers to any pathological condition affecting these components, including dry eye syndrome (DES), allergic disorders, infections, degenerative changes, and tumors [1, 2]. The cornea is one of the most critical components of the ocular surface, serving as a transparent window to the world. Its clarity, curvature, and appropriate moisture level — maintained by the overlying tear film — are essential for proper vision. Dysfunction of other ocular surface structures can significantly impact corneal health and integrity.

OCULAR SURFACE DISEASE VS. DRY EYE SYNDROME

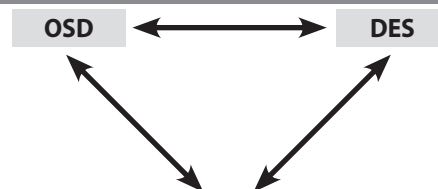
Ocular surface disease (OSD) is defined as a disorder affecting the structures that comprise the ocular surface, leading to tear film abnormalities and the development of DES. As a result, the ocular surface loses its ability to protect the deeper layers and structures of the eye, leading to chronic and bothersome sensory symptoms as well as varying degrees of visual impairment.

A lack of adequate protection – normally provided by the ocular adnexa, conjunctival epithelium, and tear film – can lead to inflammation, infection, and damage to the tissues of the anterior segment of the eye. This raises an important question: Is OSD the same as DES?”

Both conditions are characterized by multifactorial pathogenesis. In the literature, they are almost always discussed together, as abnormalities of the ocular surface contribute to the development of DES, while DES – especially when resulting from iatrogenic factors or systemic diseases – can, in turn, lead to further damage of the ocular surface (fig. 1). The current definition of dry eye syndrome (DES) describes it as a multifactorial ocular surface disease (OSD) characterized by a loss of tear film homeostasis, accompanied by ophthalmic symptoms such as tear film instability and hyperosmolarity, ocular surface inflammation and damage, and neurosensory abnormalities – factors that are both characteristic features and contributors to the disease pathogenesis [3]. The pathomechanism of DES is often described as a vicious cycle that can be extremely difficult to interrupt. Failure to recognize or address the early symptoms of OSD and DES in some patients may lead to severe

FIGURE 1

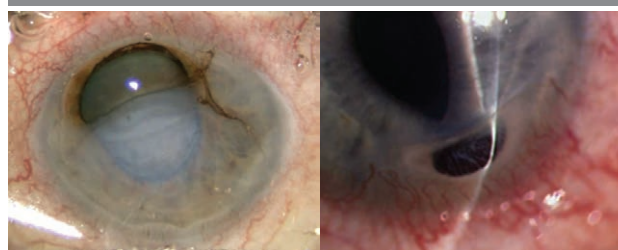Diagram illustrating the relationship between OSD, DES, and pathologies affecting specific structures of the eye and its protective apparatus.



- Eyelid disorders: blepharitis, Meibomian gland dysfunction (MGD), anatomical abnormalities
- Conjunctival diseases: allergic conjunctivitis, infectious inflammation, degenerative changes (e.g., pterygium)
- Secondary corneal disorders: degenerations, trophic and infectious ulcers, corneal perforations

FIGURE 2

Corneal perforations in patients with severe DES.



complications, including corneal perforation [4], which poses a risk of vision loss or, in extreme cases, may necessitate enucleation due to endophthalmitis (fig. 2).

IATROGENIC DRY EYE SYNDROME

Epidemiological data indicate an upward trend in the incidence of DES, particularly among individuals over the age of 30 – although cases are also observed in the pediatric population. This increase is influenced by changing lifestyles, as well as environmental and socioeconomic factors. Numerous risk factors for DES have been identified. Experts have categorized them into modifiable and non-modifiable factors, each further subdivided into proven, probable, and unproven. Among the proven non-modifiable risk factors are age (aging), gender, race, connective tissue diseases, the presence of Sjögren's syndrome, and Meibomian gland dysfunction (MGD) [5].

As new research on DES continues to emerge, previously unproven risk factors are being reclassified as probable, and formerly probable factors are increasingly recognized as proven. The most recent expert consensus report, published in 2023 after 2.5 years of work, is divided into ten sections and addresses a wide range of risk factors, including contact lens use, cosmetics, digital device exposure, select-

ed medications and treatments, environmental conditions, lifestyle, nutrition, and social determinants of health [6].

In the therapeutic process, the potential adverse effects of medications – both topical and certain systemic agents – on the condition of the ocular surface are often overlooked. Moreover, all ophthalmic surgical procedures carry the risk of inducing OSD. Both the surgical procedure itself – through disruption of tissue integrity, induction of inflammation, and the cytotoxic effects of substances used intraoperatively – and the medications administered in the perioperative and postoperative periods are recognized as causative factors of so-called iatrogenic DES. In such cases, the treatment of one condition may become the cause of another, potentially equally burdensome for the patient [7]. Cataract surgery is the most commonly performed surgical procedure worldwide. Patients undergoing this operation are typically older individuals who are often treated for other systemic conditions and thus already possess at least one risk factor for DES. It is also not uncommon for cataract patients to be undergoing treatment for glaucoma, where long-term pharmacotherapy – especially polytherapy – can induce adverse changes on the ocular surface. In such cases, both the perioperative and postoperative periods are associated with an exacerbation of pre-existing DES.

Iatrogenic DES can result from virtually any ophthalmic procedure, ranging from eyelid surgery and refractive procedures to corneal cross-linking (CXL) and intraocular surgeries such as phacoemulsification, glaucoma surgery, keratoplasty, vitrectomy, or combined interventions [8, 9]. Therefore, it is essential to assess the condition of the ocular surface prior to any planned surgical procedure and to conduct a thorough medical history. This should include information on comorbidities and their treatment, previous methods of refractive error correction, known allergies, occupational and lifestyle factors, smoking status, and other relevant risk factors.

For example, patients undergoing laser refractive surgery are typically young but often have a history of long-term contact lens use, extended screen time, and symptoms consistent with so-called office eye syndrome. It is estimated that 40–45% of patients qualified for laser refractive correction already present with dry eye symptoms, and the incidence of dry eye following the procedure reaches approximately 70%. In most cases, these symptoms resolve within a few months [10].

DIAGNOSTIC PITFALLS IN CONJUNCTIVAL AND CORNEAL DISORDERS

Dry eye syndrome can present in mild, moderate, or severe forms. Fortunately, the most common presentation is mild and does not pose a threat to the integrity of the visual system. Moderate and severe forms typically occur in patients

with additional risk factors, such as autoimmune diseases, which often fall under the care of rheumatologists, dermatologists, or hematologists.

Patients with rheumatic diseases – most commonly rheumatoid arthritis (RA) – as well as those with dermatological conditions such as atopic dermatitis (AD) and psoriasis, hemato-oncological disorders, a history of bone marrow transplantation, chemotherapy, or radiotherapy, and individuals with ulcerative colitis should undergo periodic ophthalmologic evaluations as part of the prevention and management of ocular complications related to their underlying disease.

In certain situations, symptoms of DES and OSD may be exacerbated and are sometimes misdiagnosed and improperly treated. A lack of improvement in such cases can represent a significant diagnostic and therapeutic pitfall. For example, a patient with moderate punctate epitheliopathy (PE) may be misdiagnosed with infectious conjunctivitis and unnecessarily prescribed antibiotic eye drops. Such treatment, instead of providing relief, may worsen the condition of the ocular surface due to the toxic effects of both the antibiotic and its preservative on the conjunctiva. This can lead to increased conjunctival hyperemia, while switching from one antibiotic to another may further aggravate the inflammatory component of DES and intensify the patient's symptoms.

A similar situation may occur with the use of antiallergic medications. A patient who is not experiencing a purely allergic reaction, but rather has DES or a coexisting condition involving both, may experience worsening of DES symptoms after taking antihistamines due to their inhibitory effect on tear secretion. Without adequate hydration support, the symptoms of allergic inflammation may paradoxically intensify instead of resolving.

Patients with moderate-to-severe forms of DES may, over time, develop signs of keratitis. Filaments may appear on the ocular surface, the corneal epithelium becomes irregular or exhibits other signs of **epitheliopathy, and erosions and scarring can form**. These changes significantly increase the risk of secondary infections of bacterial, viral, fungal, protozoal, or mixed etiology. In an era of rapidly increasing antimicrobial resistance, antibiotics should not be prescribed prophylactically. According to current guidelines for the treatment of DES and OSD, first-line therapy should include preservative-free drops and gels with moisturizing and regenerative properties. Additionally, breaking the self-perpetuating inflammatory cycle may require the use of topical corticosteroids and/or cyclosporine A [11]. As in the previous examples, the introduction of antibiotic therapy in cases of misdiagnosed infectious keratitis may not only fail to provide clinical improvement but can also exacerbate symptoms and patient discomfort. Individuals at risk – particularly those with a history of chronic treat-

ment, ophthalmic procedures, or surgery – require special attention during diagnosis and a treatment plan tailored to their clinical condition. Paradoxically, in some cases, discontinuing eye drops altogether may be more beneficial than continuing inappropriate or excessive polypharmacy.

THERAPEUTIC MANAGEMENT AND THE ROLE OF DEXPANTHENOL

Regardless of the underlying cause or severity of OSD, including punctate epitheliopathy (PE), tear substitution remains an essential component of first-line therapy. Recommended formulations include preservative-free eye drops, emulsions, and gels – particularly those free of benzalkonium chloride (BAK). Proper evaluation and protection of the ocular surface prior to planned ophthalmic procedures or surgeries is a crucial step in the therapeutic process. It not only prepares the patient for surgery but also enhances the accuracy of preoperative diagnostic tests – such as corneal topography and intraocular lens power calculations – and helps reduce or even eliminate the impact of drug toxicity and the risk of postoperative corneal complications. This has a significant impact on patient satisfaction with surgical outcomes. Therefore, preoperative recommendations should always include the use of ocular surface preparations with moisturizing and regenerative properties. In patients with more severe forms of DES, it is essential to carefully select the timing of surgery during a period of controlled inflammation and to extend the use of appropriate anti-inflammatory medications throughout the perioperative and postoperative periods. The standard postoperative regimen of topical medications following ophthalmic surgery typically includes an antibiotic, a non-steroidal anti-inflammatory drug (NSAID), corticosteroid eye drops, and a regenerative agent – preferably in gel form, such as dexpanthenol.

Dexpanthenol is an analog of pantothenic acid and exhibits identical biological activity. It stimulates fibroblast proliferation and collagen synthesis, thereby accelerating the healing of corneal damage. Pantothenic acid and its derivatives are considered non-toxic and well tolerated. Thus, dexpanthenol is used in the treatment of non-inflammatory keratopathies, as a healing agent for corneal and conjunctival injuries, recurrent corneal erosions, damage related to contact lens use, and as an adjunctive therapy in the treatment

of infectious ocular inflammations. In Poland, dexpanthenol gel has been used in ophthalmology since 1996, and data on its efficacy and tolerability are supported by nearly 30 years of clinical experience. Dexpanthenol does not interact with other medications, making it a safe and effective adjunct both in perioperative preparation and as part of the postoperative treatment regimen [12].

Dexpanthenol may be used for an extended period following the completion of antibiotic or anti-inflammatory treatment, if needed. It is typically administered 2–4 times daily into the conjunctival sac and onto the corneal surface. Both moisturizing eye drops and dexpanthenol can be safely recommended by physicians of other specialties – such as rheumatologists, dermatologists, oncologists, and others – who manage patients at risk of developing OSD and DES. More recently, preservative-free multicomponent eye drop formulations have become available, containing substances with moisturizing, soothing, and regenerative effects on the ocular surface – such as hyaluronic acid, trehalose, fucoidan, and dexpanthenol. In cases where single- or dual-component preparations provide insufficient improvement, these advanced combinations offer a safe and effective alternative for the treatment of ocular surface disorders.

CONCLUSIONS

Ocular surface diseases, including DES, are an increasingly significant public health concern. It is estimated that **Meibomian gland dysfunction (MGD)** – which is responsible for the more common evaporative form of DES – affects 38–68% of individuals over the age of 40. While the mild form of DES is the most prevalent, its exacerbation and progression to moderate or severe stages in patients with additional risk factors may pose a direct threat to ocular health. Preparations with moisturizing and regenerative properties are an optimal component of therapy at every stage of OSD and DES management. Regenerative treatment of the ocular surface is particularly important in the perioperative and postoperative periods for most ophthalmic patients, and dexpanthenol in gel form has proven to be effective in this role. The duration of therapy should be determined individually, based on clinical presentation and specific indications.

All figures are from the authors' authors' own materials.

CORRESPONDENCE

Monika Udziela, MD, PhD

Samodzielny Publiczny Kliniczny Szpital Okulistyczny
03-709 Warszawa, ul. Sierakowskiego 13
e-mail: monika.udziela@wum.edu.pl

ORCID

Monika Udziela – ID – <https://orcid.org/0000-0001-5036-2091>

References

1. Aragona P, Rolando M. Towards a dynamic customised therapy for ocular surface dysfunctions. *Br J Ophthalmol*. 2013; 97(8): 955-60.
2. Willcox MDP, Argüeso P, Georgiev GA et al. TFOS DEWS II tear film report. *Ocul Surf*. 2017; 15(3): 366-403.
3. Craig JP, Nichols KK, Akpek EK et al. TFOS DEWS II definition and classification report. *Ocul Surf*. 2017; 15(3): 276-83.
4. Singh S, Das AV, Basu S. Ocular involvement in Sjögren syndrome: risk factors for severe visual impairment and vision-threatening corneal complications. *Am J Ophthalmol*. 2021; 225: 11-7.
5. Stapleton F, Alves M, Bunya VY et al. TFOS DEWS II Epidemiology Report. *Ocul Surf*. 2017; 15(3): 334-65.
6. Craig JP, Alves M, Wolffsohn JS et al. TFOS Lifestyle Report Executive Summary: A Lifestyle Epidemic - Ocular Surface Disease. *Ocul Surf*. 2023; 30: 240-53.
7. Gomes JAP, Azar DT, Baudouin C et al. TFOS DEWS II iatrogenic report. *Ocul Surf*. 2017; 15(3): 511-38.
8. Mencucci R, Vignapiano R, Rubino P et al. Iatrogenic Dry Eye Disease: Dealing with the Conundrum of Post-Cataract Discomfort. A P.I.C.A.S.S.O. Board Narrative Review. *Ophthalmol Ther*. 2021; 10(2): 211-23.
9. Mastropasqua L, Barboni P, Savini G et al. Refractive surgery and dry eye. *Eur J Ophthalmol*. 2023 May 22: 11206721231176312.
10. Zhao PF, Zhou YH, Hu YB et al. Evaluation of preoperative dry eye in people undergoing corneal refractive surgery to correct myopia. *Int J Ophthalmol*. 2021; 14(7): 1047-51.
11. Jones L, Downie LE, Korb D et al. TFOS DEWS II Management and Therapy Report. *Ocul Surf*. 2017; 15(3): 575-628.
12. Raczyńska K, Iwaszkiewicz-Bilikiewicz B, Stozkowska W et al. Clinical evaluation of provitamin B5 drops and gel for postoperative treatment of corneal and conjunctival injuries. *Klin Oczna*. 2003; 105(3-4): 175-8.

Conflict of interest:

None.

Financial support:

None.

Ethics:

The content presented in the article complies with the principles of the Helsinki Declaration, EU directives and harmonized requirements for biomedical journals.