ARTYKUŁ PRZEGLĄDOWY REVIEW ARTICLE

DOI: 10.24292/01.OT.131126

Article ID: A131126

Therapeutic application of contact lenses in ocular surface diseases



Dominik Wierczyński, Patryk Młyniuk

Department of Ophthalmology, Collegium Medicum, Nicolaus Copernicus University, Bydgoszcz

Head: prof. Bartłomiej J. Kałużny, MD, PhD

HIGHLIGHTS

Contact lenses evolved from refractive aids to essential therapeutic tools, offering corneal protection, myopia control, and innovative drug delivery for severe ocular surface diseases.

ABSTRACT

State of knowledge: Rigid and scleral lenses are the gold standard for correcting ectasia and irregular astigmatism. In severe disorders like dry eye or Stevens–Johnson syndrome, scleral lenses provide crucial hydration. Soft bandage lenses accelerate epithelial healing after keratorefractive surgeries and corneal cross-linking. Furthermore, specialized lenses manage myopia progression and facilitate visual rehabilitation.

Conclusions: Contact lenses are versatile therapeutic tools for both vision restoration and advanced corneal protection.

Key words: therapeutic contact lenses, scleral lenses, corneal diseases, ocular surface, bandage lenses

Copyright © Medical Education

INTRODUCTION

Beyond the correction of refractive errors, contact lenses play a crucial role in managing corneal and ocular surface diseases. They constitute a versatile therapeutic modality that supports visual rehabilitation and preserves corneal structural integrity across a wide spectrum of pathologies [1–3].

Specific lens designs are developed to address particular clinical indications. Soft bandage lenses are widely used to accelerate healing following injuries or surgeries, such as corneal cross-linking. On the other hand, rigid gas-permeable (RGPCL), hybrid (HCL), and scleral lenses are considered the gold standard for corneal ectasia, as they correct irregular astigmatism and often represent the only viable option for achieving the functional vision. In severe surface disorders, like dry eye syndrome (DES) or Stevens–Johnson syndrome (SJS), scleral lenses provide essential hydration and protection. Additionally, specialized lenses are employed for myopia control and prosthetic rehabilitation.

The aim of this review is to summarize the current guidelines and indications for the therapeutic use of contact lenses, with a special focus on their application in corneal irregularities and ocular surface diseases [1, 3–6].

CLASSIFICATION AND TYPES OF THERAPEUTIC CONTACT LENSES

Therapeutic contact lenses can be classified based on the material, properties, and design. The choice of a specific type depends on the underlying pathology, the required duration of wear, and the therapeutic goal (e.g., pain relief, mechanical protection, or visual rehabilitation) [7].

RIGID GAS PERMEABLE AND SPECIALITY CONTACT LENSES

Rigid contact lenses, historically evolved from PMMA to modern polymers containing silicon and fluorine, are characterized by high shape stability and high oxygen permeability (Dk/t) exceeding 160 ISO/Fatt [7]. RGPCL, with diameters ranging from 8.6 mm to 10.0 mm and base curves between 6.1 and 8.9 mm, can correct spherical refractive errors from -40.00 D to +40.00 D and astigmatism up to 8.0 D (fig. 1). Clinically, RGP serve as the primary indication for stage I and II keratoconus according to the Amsler–Krumeich classification, effectively compensating corneal irregularities to improve visual acuity. In cases of mechanical intolerance, a "piggy-back" system is utilized, where the RGPCL is fitted over a soft carrier lens. Market forecasts for 2025–2030 indicate significant growth in this segment, particularly across Asia and Oceania [7–11].

HCL integrate a rigid gas-permeable center (base curve 5.5–10.0 mm) with a soft hydrogel or silicone-hydrogel skirt (total diameter 14.9–15.5 mm). This design aims to combine the high optical quality of traditional RGPCL with enhanced centration stability and improved wearing comfort (fig. 2). However, their functional lifespan is limited to approximately 6 months due to deposit accumulation on the soft skirt. The choice between these two modalities often presents a clinical dilemma regarding comfort versus physiological stability in ectasia management. A 2019 clinical study comparing HCLs with standard RGPCLs in keratoconus patients highlighted significant limitations of hybrid technology. The research revealed that while HCLs improved centration, they were associated with a higher incidence of complications, such as giant papillary conjunctivitis and epithelial edema. Furthermore, keratometric analysis demonstrated that traditional RGPCLs maintain corneal flattening more effectively (mean 50.21 [±4.85] D) compared to hybrid lenses (48.03 [±3.51] D). This suggests that in long-term keratoconus therapy, the enhanced comfort of an HCL may come at the expense of corneal physiological stability. Consequently, RGPCLs remain the method of choice for stages I and II of the disease, while HCLs are primarily recommended for mild to moderate irregularities where rigid lens intolerance presents a significant barrier to treatment [2, 12].

FIGURE 1

Fluorescein image of deepened RGPCL with slit lamp (source: archives of the Oftalmika Eye Clinic, Bydgoszcz, Poland).

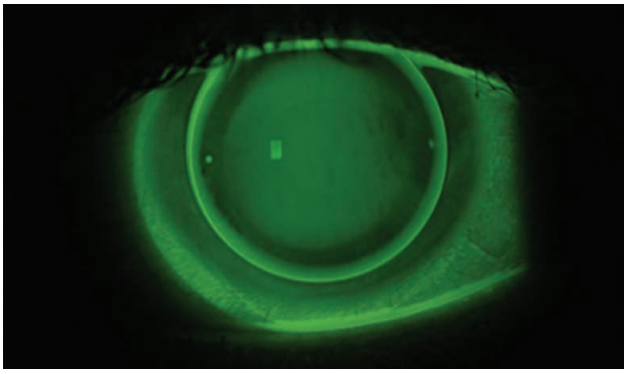

Mini-scleral and scleral lenses, defined by large diameters (13.0–25.0 mm) and sagittal heights of 3.0–5.4 mm (fig. 2), vault over the entire corneal surface and rest on the relatively insensitive sclera. This design creates a fluid-filled reservoir that is fundamental to the PROSE (Prosthetic Replacement of the Ocular Surface Ecosystem) system, providing continuous hydration and mechanical protection. A critical finding from this review is the re-definition of the scleral lens from a purely optical device to a therapeutic "liquid bandage".

They are now considered the gold standard for managing advanced ectasias (stage III–IV keratoconus, Pellucid Marginal Degeneration – PMD) and represent a breakthrough in the management of severe cicatrizing and desiccating conditions, such as SJS, mucous membrane pemphigoid (MMP), and neurotrophic keratopathy. Recent advancements in manufacturing technology and design customizability have significantly

Copyright © Medical Education

lowered the barrier to entry for practitioners. Consequently, there is a marked increase in the clinical utilization of scleral lenses, making them a first-line non-surgical intervention for complex ocular surface diseases [3, 6, 12–14].

Beyond mechanical protection and hydration, an emerging area of research points to a future evolution of scleral lenses into advanced pharmacotherapeutic systems. Traditional eye drops are characterized by notably low bioavailability, with only approximately 5% of the active substance typically absorbed. To address this, scleral lenses are currently being investigated for their ability to function as an active drug reservoir. This mechanism has the potential to maintain a constant concentration of a therapeutic agent on the ocular surface, which could radically improve the prognosis for patients suffering from SJS, MMP, and neurotrophic keratopathy. Although this application remains largely experimental, it highlights a prospective shift in management strategies where sustained drug release and mechanical protection may become as integral to therapy as vision correction in advanced pathologies, significantly expanding future therapeutic modalities [1, 3, 6, 9, 13–16].

FIGURE 2

Difference in the construction of rigid contact solutions: corneal, scleral, and hybrid (source: own photo).



SOFT CONTACT LENSES

Soft contact lenses, originally developed from HEMA polymers by Otto Wichterle in the 1960s, have evolved into the dominant modality for both refractive correction and ocular surface management. Currently, they are categorized based on their material composition into hydrogel and silicone-hydrogel (SiH) lenses (fig. 3). Hydrogel lenses, characterized by a base curve of 7.0–9.5 mm and a diameter of 12.5–14.5 mm, offer spherical corrections ranging from -20.00 D to +10.00 D and cylindrical corrections up to -5.75 D. Their water content varies significantly, categorized into low (<50%) and high (>50%) hydration groups, with modern daily disposables like BioTrue ONEday (Bausch + Lomb, USA) reaching up to 78% water content. However, their clinical utility in therapeutic applications is limited by low oxygen permeability; studies indicate that extended wear exceeding 6 nights poses a risk of corneal hypoxia, and the material demonstrates a higher affinity for microbial adherence compared to rigid lenses [17–19].

FIGURE 3

Soft contact lens (source: own photo).



The introduction of silicone-hydrogel (SiH) materials in 1999 marked a significant therapeutic advancement in contactology. By incorporating silicone elastomers, these lenses achieve oxygen transmissibility (Dk/t) levels 5 to 10 times higher than traditional hydrogels, effectively maintaining physiological corneal metabolism even during sleep. With standard parameters including a base curve of 7.4–9.4 mm and a diameter of 14.0–15.5 mm, SiH lenses quickly became the preferred choice for continuous, extended wear. However, confronting these superior material properties with global market realities reveals an interesting clinical paradox. While SiH lenses logically dominate the market, accounting for 64% of fittings in the US in 2018, traditional hydrogels still surprisingly retain a significant 22% share (fig. 4). This persistence suggests that for standard daily wear, where the risk of corneal hypoxia is considerably lower, factors such as reduced material stiffness and cost-effectiveness continue to drive patient preference. Simultaneously, there is a clear, health-conscious shift toward daily disposable lenses. An analysis of the Polish market, for example, highlights that the daily disposable segment grew from 20% in 2013 to 37% in 2021, driving a 70% increase in overall market value within less than a decade. This trend indicates that contact lenses have transitioned from a niche product to a mainstream medical device, and the growing emphasis on hygiene is gradually phasing out the need for complex lens care systems, which is a crucial factor in infection prevention [20–22].

In the management of DES and SJS, clinical evidence suggests the use of SiH lenses with large diameters and low-to-medium water content to minimize tear film dehydration, contrasting with high-water content hydrogels that may exacerbate dryness.

Beyond refraction, soft SiH lenses serve a critical role as bandage modalities. They are indicated for managing recurrent corneal erosions, bullous keratopathy, and post-surgical recovery following cross-linking (CXL) or keratorefractive procedures. Clinical data supports their efficacy in treating small corneal perforations (under 2 mm), either as a standalone therapy or

Copyright © Medical Education

combined with tissue adhesives [2, 8, 22]. Furthermore, in cases of chemical burns, photographic evidence from slit-lamp examinations has documented complete re-epithelialization within 5 days under the protection of a bandage lens.

Innovations in soft lens optics have also extended their application to myopia control, confirming a definitive clinical transition from passive correction to active therapy. For instance, the MiSight soft lens (CooperVision, USA), utilizing ActiveControl technology, employs myopic defocus to retard axial elongation in pediatric patients, offering an effective alternative to rigid orthokeratology. Another notable advancement in this field is the ACUVUE Abiliti 1-Day lens (Johnson & Johnson Vision, USA), which, although currently unavailable on the Polish market, utilizes novel RingBoost technology to create a treatment ring of myopic defocus, further expanding the non-invasive therapeutic options for pediatric patients. Concurrently, long-term studies on orthokeratology have demonstrated an impressive average annual increase in axial length of only 0.16 mm. The combined success of advanced soft defocus lenses and orthokeratology (Ortho-K) makes contact lenses the primary tool in combating the global myopia epidemic, significantly surpassing traditional eyeglass methods in overall effectiveness [1, 23, 24].

Additionally, much like scleral modalities, soft lens matrices are being actively investigated as advanced drug delivery systems. By loading these lenses with nanoparticles or incorporating vitamin E diffusion barriers, researchers aim to provide a sustained release of therapeutics such as pilocarpine and timolol. This innovative approach is designed to overcome the notoriously low bioavailability that limits standard topical eye drops [23–26].

FIGURE 4

Estimated market structure (source: author's own elaboration based on data from [20, 21]).

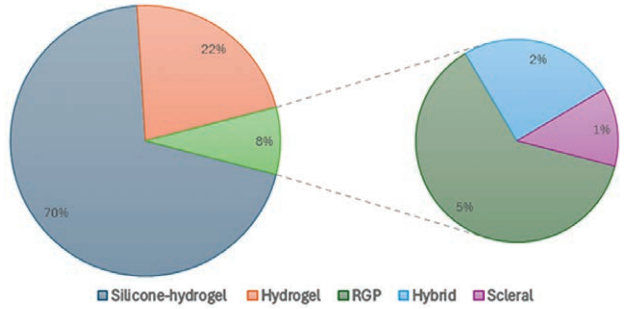

TABLE 1

Anterior ocular surface disorders considering the type of contact lens recommended for their treatment (source: author's own elaboration based on data from [2, 3, 8, 9, 12, 15, 16, 18, 22, 27–30]).

Clinical category	Examples of pathologies	Recommended contact lens
Primary corneal ectasias	1. Keratoconus (grades I–IV)	**Grades I–II**: RGPCL, scleral/mini-scleral, HCL. **Grades III-IV**: scleral/mini-scleral.
	2. Pellucid marginal degeneration (PMD)	RGPCL, scleral/mini-scleral.
Secondary irregularities	1. Post-keratoplasty (PKP)	HCL, post-graft RGPCL, bandage lenses (SiH), scleral/mini-scleral.
	2. Corneal irregularities: e.g. Post-LASIK ectasia, post-trauma scarring	HCL, scleral/mini-scleral, RGPCL, bandage lenses.
	3. High irregular astigmatism	Scleral/Mini-scleral lenses, RGPCL, HCL.
Severe ocular surface disease	1. Dry eye syndrome (DES)	Scleral/Mini-scleral, SiH, hydrogel.
	2. Sjögren's syndrome	Scleral/Mini-scleral (PROSE system), SiH.
	3. Stevens–Johnson syndrome (SJS)	Scleral/Mini-scleral (PROSE system).
	4. Ocular cicatricial pemphigoid (MMP)	Scleral/Mini-scleral (PROSE system), SiH.
	5. GVHD	Scleral/Mini-scleral.
Corneal healing & protection	1. Recurrent erosions, abrasions	Bandage lenses (SiH), scleral/mini-scleral.
	2. Chemical/Thermal burns	SiH lenses, scleral/mini-scleral lenses.
	3. Neurotrophic keratopathy	Scleral/Mini-scleral (PROSE system), SiH.
	4. Exposure keratopathy	Scleral/Mini-scleral lenses.
	5. Bullous keratopathy	RGPCL, bandage lenses (SiH), scleral/mini-scleral lenses.
Mechanical/Tectonic support	1. Small perforations (<1–2 mm)	SiH.
Myopia management	1. Progressive myopia in children	SiH, Hydrogel, orthokeratology lenses (Ortho-K).
Other	1. Standard refractive correction (presbyopia, hyperopia, myopia, anisometropia)	**Presbyopia:** SiH lenses, hydrogel lenses, multifocal RGPCL, HCL. **Hyperopia**: soft contact lenses, multifocal. **Myopia:** soft contact lenses, orthokeratology lenses (Ortho-K). **Anisometropia:** RGPCL, soft contact lenses.
	2. Regular astigmatism	Toric hydrogel lenses, toric SiH lenses, RGPCL.
	3. Aphakia	RGPCL, SiH.
	4.Aniridia/Coloboma/ Leukoma/Heterochromia	Prosthetic lenses, colored contact lenses.
	5. Pterygium	Prosthetic lenses, scleral/mini-scleral.
	6. Glaucoma/Diabetes	Biosensor lenses.

GVHD – graft-versus-host disease; HCL – hybrid contact lenses; LASIK – Laser-Assisted in situ Keratomileusis; PROSE – Prosthetic Replacement of the Ocular Surface Ecosystem; RGPCL – rigid gas-permeable contact lenses; SiH – silicone-hydrogel lenses.

Copyright © Medical Education

CONCLUSION

Modern contactology clearly demonstrates that for patients with corneal irregularities (such as advanced ectasias), severe refractive errors, or aphakia, contact lenses often serve as the only viable method for achieving functional, and frequently excellent, vision. When traditional spectacle correction fall short in these complex clinical scenarios, specialty lenses, particularly rigid gas-permeable designs, emerge as an absolutely indispensable tool for visual rehabilitation, ultimately restoring patients' everyday functionality.

Another pivotal advancement enhancing ophthalmic care is the application of soft contact lenses as therapeutic "bandages". For patients recovering from mechanical trauma, chemical burns, or invasive keratorefractive surgeries, these bandage lenses create a physical barrier that drastically accelerates epithelial healing. Equally important, they effectively shield exposed nerve endings on the corneal surface, leading to a dramatic reduction in pain and photophobia.

Furthermore, the revolutionary impact of scleral lenses in managing severe ocular surface diseases like Stevens–Johnson syndrome, cicatricial pemphigoid, and neurotrophic keratopathy cannot be overstated. This PROSE treatment provides continuous hydration and shields the eye from the destructive friction of the eyelids. Ultimately, it protects the globe from pathological desiccation, ulceration, and in extreme cases, perforation.

In today's era of excessive and prolonged screen time among children, adolescents, and young adults, specialty contact lenses, including soft lenses with defocus technology and rigid Ortho-K lenses, have become a critical preventive tool. Their role extends far beyond standard myopia correction; they actively slow the progression of nearsightedness by inhibiting excessive axial elongation of the eye. This intervention directly protects the delicate retina, significantly lowering the lifelong risk of severe, myopia-associated ocular pathologies like retinal detachment and glaucoma.

Looking toward the future, the next great frontier appears to be the evolution of contact lenses into advanced, precision drug-delivery systems. By incorporating cutting-edge technologies like nanoparticles, vitamin E diffusion barriers, and scleral lens fluid reservoirs, researchers aim to definitively overcome the notoriously low bioavailability of traditional eye drops. While these innovations remain in intensive experimental and clinical trials, the global medical community eagerly anticipates their arrival.

Ultimately, these advancements prove that contactology is far from a closed chapter. Despite tremendous therapeutic successes, challenges remain, such as the persistent risk of severe corneal infections linked to poor hygiene and the ongoing need to refine polymers for enhanced wettability and biocompatibility. However, these limitations serve as prime catalysts for future research and development, ensuring that the coming years will bring even more groundbreaking breakthroughs in vision protection and eye care.

CORRESPONDENCE
med. stud. Dominik Wierczyński
Department of Eye Diseases and Optometry, CM UMK
85-094 Bydgoszcz, ul. M. Skłodowskiej-Curie 9, Poland
e-mail: wierczynskidominik00@gmail.com

ORCID
Dominik Wierczyński – ID – http://orcid.org/0009-0008-1757-965X
Patryk Młyniuk – ID – http://orcid.org/0000-0002-2321-8411

Cite as: Wierczyński D, Młyniuk P. Therapeutic application of contact lenses in ocular surface diseases. Ophthatherapy. 2026; 13(4): A131126.

References

1. Sridhar MS. Anatomy of cornea and ocular surface. Indian J Ophthalmol. 2018; 66: 190-4.
2. Sah R, Sharma N, Priyadarshini K et al. Contact lenses for the treatment of ocular surface diseases. Indian J Ophthalmol. 2023; 71: 1135-41.
3. Chaudhary S, Ghimire D, Basu S, et al. Contact lenses in dry eye disease and associated ocular surface disorders. Indian J Ophthalmol. 2023; 71: 1142-53.
4. Santodomingo-Rubido J, Carracedo G, Suzaki A et al. Keratoconus: An updated review. Cont Lens Anterior Eye. 2022; 45(3): 101559.
5. Contacts: Specialty Lens Types. The Ohio State University. https://wexnermedical.osu.edu/eye-care-ophthalmology/conditions-and-services/contact-lenses/specialty-lens-types.

Copyright © Medical Education

6. Musgrave CSA, Fang F. Contact Lens Materials: A Materials Science Perspective. Materials (Basel). 2019; 12(2): 261.
7. Janiszewska D. Stożek rogówki. In: Wylęgała E, Tarnawska D, Dobrowolski D (eds.). Choroby rogówki Bedeker Okulistyczny. Tom IV. Górnicki Wydawnictwo Medyczne, Wrocław 2015: 69-74.
8. Oleszczyńska-Prost E. Podstawy soczewek kontaktowych. In: Grzybowski A (ed.). Okulistyka. Edra, Wrocław 2018: 59-63.
9. Tsubota K, Mashima Y, Murata H et al. A Piggyback Contact Lens for the Correction of Irregular Astigmatism in Keratoconus. Ophthalmology. 1994; 101: 134-9.
10. Contact Lens Market Geography Segment Analysis Source. Mordor Intelligence. https://www.mordorintelligence.com/industry-reports/contact-lens-market.
11. Chou B. Are Hybrid or Scleral Contacts Better? ReVision Optometry. https://revisionoptometry.com/blog/are-hybrid-or-scleral--contacts-better/.
12. Saraç Ö, Kars ME, Temel B et al. Clinical evaluation of different types of contact lenses in keratoconus management. Cont Lens Anterior Eye. 2019; 42: 482-6.
13. Wang, JW, Rixen JJ, Goins KM et al. Ocular Manifestations of Stevens-Johnson Syndrome: 13-year-old female with mucosal and dermatologic eruptions. EyeRounds.org. https://eyerounds.org/cases/192-Stevens-Johnson.htm.
14. Jinabhai A, Radhakrishnan H, O'Donnell C. Pellucid corneal marginal degeneration: A review. Cont Lens and Anterior Eye. 2011; 34: 56-63.
15. Lim L, Lim EWL. Therapeutic contact lenses in the treatment of corneal and ocular surface diseases – A review. Asia Pac J Ophthalmol (Phila). 2020; 9: 524-32.
16. Dobrowolski D. Zastosowanie soczewek kontaktowych w chorobach rogówki. In: Wylęgała E, Tarnawska D, Dobrowolski D (eds.). Choroby rogówki Bedeker Okulistyczny. Tom IV. Górnicki Wydawnictwo Medyczne, Wrocław 2015: 185-90.
17. Kyle RA, Steensma DP, Shampo MA. Otto Wichterle – Inventor of the First Soft Contact Lenses. Mayo Clinic Proceedings 2016; 91: 1-2.
18. Konstrukcje soczewek kontaktowych. Optyka. 2010; 1: 48-50.
19. Nicolson PC, Vogt J. Soft contact lens polymers: an evolution. Duluth, Georgia 2001.
20. Rynek soczewek kontaktowych w Polsce. Nielseniq. https://nielseniq.com/global/pl/news-center/2017/rynek-soczewek-kontaktowych-w-polsce/.
21. GfK: Na rynku soczewek widać wzrosty. ISB zdrowie. https://www.isbzdrowie.pl/2023/02/gfk-na-rynku-soczewek-widac-wzrosty/.
22. Segre L. Contact lens basics: Types of contact lenses and more. All about vision. https://www.allaboutvision.com/ru/optika/kontaktniye-linzi/tipi/osnovy/.
23. Lv H, Liu Z, Li J et al. Long-Term Efficacy of Orthokeratology to Control Myopia Progression. Eye Contact Lens. 2023; 49: 399-403.
24. Chamberlain P. Further comparison of myopia progression in new and established myopia control treatment (MiSight® 1 day) groups. Contact Lens and Anterior Eye. 2019; 42 (6, Supplement 1): 42e16.
25. Gote V, Sikder S, Sicotte J et al. Ocular drug delivery: Present innovations and future challenges. J Pharmacol Exp Ther. 2019; 370: 2-84.
26. Carr W, Schaeffer J, Donnenfeld E. Treating allergic conjunctivitis: A once-daily medication that provides 24-hour symptom relief. Allergy Rhinol (Providence). 2016; 7(2): 107-14.
27. Kański JJ. Okulistyka kliniczna. 6 ed. (Polish edition editor: Szaflik J). Elsevier, 2007: 100-330.
28. Grosvenor T. Primary Care Optometry. Elsevier Inc., 2007.
29. Sutherland RL, VanLeeuwen WN. Soft contact lenses. Can Med Assoc J. 1972; 107(1): 49-50.
30. Lim L, Lim EWL. Current perspectives in the management of keratoconus with contact lenses. Eye (Basingstoke). 2020; 34: 1-18.

Authors' contributions:
Dominik Wierczyński: research concept, literature review, drafting of the manuscript, preparation of the references and editing of the text.
Patryk Młyniuk: substantive supervision, clinical verification of the content, proofreading and approval of the final version of the manuscript.

Conflict of interest:
None.

Financial support:
None.

Ethics:
The content presented in the article complies with the principles of the Helsinki Declaration, EU directives and harmonized requirements for biomedical journals.

Copyright © Medical Education