

Outcomes of posterior chamber iris-claw intraocular lenses implantation in aphakic eyes with insufficient capsular support: retrospective observational study

Ilona A. Kaczmarek¹, Jaromir Wasyluk^{1,2}, Ilona Jędrzejewska²,
Małgorzata Myślińska¹, Marek E. Prost¹

¹Klinika Okulistyki, Wojskowy Instytut Medycyny Lotniczej w Warszawie
p.o. Kierownika Kliniki: dr n. med. Jaromir Wasyluk

²Centrum Okulistyczne OPTIMUM w Warszawie
Kierownik medyczny: dr n. med. Małgorzata Krajewska



HIGHLIGHTS

Posterior chamber iris-claw aphakic IOL can be used for a wide range of indications in aphakic eyes without adequate capsule support, providing good visual outcomes.

ABSTRACT

Background: Implantation of posterior chamber iris-claw intraocular lenses (IOLs) is often used in the surgical management of aphakia with inadequate capsular support. The purpose of the study was to evaluate the anatomical and functional outcomes and complication rate after implantation of a posterior chamber iris-claw aphakic IOL in eyes with insufficient capsular support.

Methods: This retrospective observational study comprised patients without adequate capsular support undergoing posterior iris-claw aphakic IOL implantation between 2016 and 2018.

Results: The study comprised 44 eyes of 44 patients. The mean follow-up was 12 months (range from 1 to 24 months). The IOLs were inserted during primary lens surgery in five eyes (11.36%), during a posterior chamber IOL exchange procedure in 24 eyes (54.55%), and as a secondary procedure in 15 aphakic eyes (34.09%). The final mean best corrected visual acuity (BCVA) was significantly better than preoperatively (0.49 ± 0.33 vs 0.36 ± 0.26 , Snellen decimals) ($P < 0.05$). The most common complication after surgery was transient elevated intraocular pressure (10 eyes; 22.73%).

Conclusions: The posterior chamber iris-claw aphakic IOLs provided good anatomical and functional outcomes and can be used for a wide range of indications in eyes without adequate capsular support.

Key words: iris-claw, aphakia, insufficient capsular support

BACKGROUND

Iris fixated (iris-claw) intraocular lenses (IOLs), originally designed for myopia correction during intraocular refractive surgery, have been used for many years in the correction of aphakia without sufficient capsule support [1]. They are used in patients requiring the replacement of a subluxated posterior chamber implant, during cataract surgery with damaged lens zonular apparatus. They are also used during reoperations after cataract removal complicated by the damage to the posterior capsule without the possibility to insert a classic posterior chamber IOL. Depending on the course of surgery, they are implanted simultaneously or afterwards, usually 2-3 months after cataract removal [2]. Currently, the most common iris-claw IOLs used in treating postoperative aphakia are Artisan Aphakia® (Ophtec) and Verisyse Aphakia® (AMO) implants. They can be fixed in both the anterior and posterior chambers. When choosing the implant location, it is recommended to take into account the depth of the anterior chamber, and the density of corneal endothelial cells [3]. Currently, the main alternative to iris-claw IOLs in the correction of aphakia without sufficient capsule support is the intrascleral fixation of the implant by suturing it to the tissue or by using different sutureless techniques [4-8]. These procedures ensure implant location similar to the physiological position of the patient's own lens; moreover, they can be performed in cases of severe damage to the iris. Both the iris-claw lenses and implants fixated to the sclera have been described; the postoperative complications include displacement of the implant, increased intraocular pressure, vitreous hemorrhage, cystoid macular edema (CME) or retinal detachment [9-14]. Due to the uncomplicated technique and relatively short procedure time, many surgeons prefer iris-claw IOLs for aphakia with damaged ciliary zonules or posterior capsule [15, 16]. The aim of our study was the retrospective analysis of anatomical and functional results and complications observed after the implantation of an iris-claw IOL implant into the posterior chamber, carried out in the Department of Ophthalmology of the Military Institute of Aviation Medicine in Warsaw, Poland, between 2016-2018.

MATERIAL AND METHODS

Patients were included in the retrospective study after an observation period of at least one month. The following medical data were analyzed in the study: the indication for iris-claw lens implantation, age and sex of the patient, eye axial length, previous surgical procedures and injuries of the eyeball, concomitant eye and systemic diseases. In all patients, an IOL made of polymethyl methacrylate Artisan Aphakia (Ophtec BV, The Netherlands), with a total length of 8.5 mm and an optical part diameter of 5.4 mm, was implanted (Fig. 1). The optical power of the implant was cal-

culated using the SRK/T formula with the IOL Master 500 optical biometer (Carl Zeiss Meditec AG). Due to the fact that the lens was implanted into the posterior chamber, the A-constant of 116.9 was used (Fig. 2).

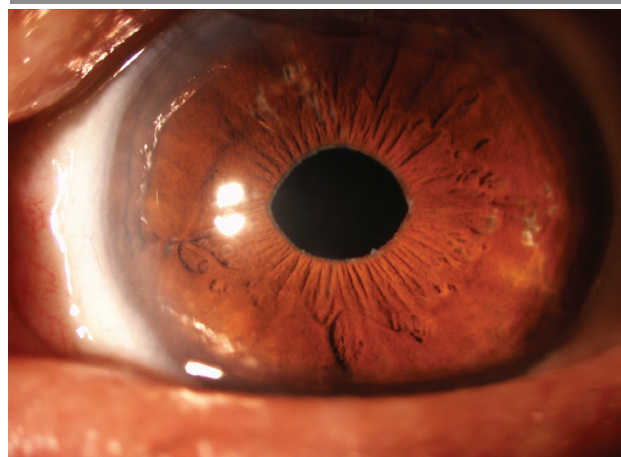
FIGURE 1

Iris-claw Artisan Aphakia 205 IOL.



FIGURE 2

89-year-old patient 24 months after the left eye posterior chamber iris-claw IOL implantation.



Pre- and postoperative Snellen's best corrected visual acuity (BCVA, best-corrected visual acuity), intraocular pressure (IOP), endothelial cell density, spherical equivalent (SE) and refractive error, defined as the difference between the achieved (spherical equivalent) and attempted refraction were evaluated in the study. The occurrence of intra- and postoperative complications were also reported. Intraocular pressure was measured using non-contact tonometer CT-800 (Topcon, Japan). Corneal endothelial cell density was calculated using CellChek SL mirror microscope (Konan, USA). For the measurement of spherical equivalent, the KR-800 auto kerato-refractometer (Topcon, Japan) was used. The refractive error was calculated as the difference between the refraction achieved (spherical equivalent) at the end of the observation period, and the target refraction determined by optical biometer.

All implantation procedures of the iris-claw IOL were performed under periocular anesthesia by three experienced surgeons using the same surgical technique. The main stages of the procedure included the anterior chamber opening in the limbus from 11.00 to 1.00, followed by making two side tunnel ports at 2.00 and 10.00-injection of the viscoelastic into the anterior chamber and inserting the IOL –patients were included in the study–“upside down” into the anterior chamber, IOL insertion into the posterior chamber, and iris encapsulation at 3.00 and 9.00. The next stages consisted in performing basal iridectomy at 12.00, suturing of the cornea in the limbus with single or continuous Nylon 10-0 sutures, and removing the viscoelastic material with aspiration and irrigation system. The procedure was concluded with the administration of Cefuroxime 1 mg/1 ml into the anterior chamber, and subconjunctival injection of dexamethasone. Corneal limbal sutures were removed on average 3 months after the procedure.

Between 2016-2018, in the Department of Ophthalmology of the Military Institute of Aviation Medicine, iris-claw lens implantation into the posterior chamber was performed in 48 eyes of 48 patients. Two eyes were not included in the study due to an insufficient observation period (< 1 month). Two eyes were excluded from the study because iris-claw IOL implantation was performed simultaneously with trabeculectomy (1 eye) or pars plana vitrectomy with administration of silicone oil (1 eye). Finally, 44 eyes of 44 patients who underwent iris-claw IOL implantation into the posterior chamber were included for retrospective study. The average observation time in patients qualified for the study was 12.11 ± 6.02 months (minimum: 1 month, maximum: 24 months). Table 1 shows the medical data and the ophthalmic and systemic diseases.

TABLE 1

Medical data of the patients and the presence of coexisting ophthalmic and systemic diseases.

n	44
Women/men	24/20
Average age \pm SD (years)	72,50 \pm 20,50
Minimum-Maximum	18–95
Average eyeball length \pm SD (mm)	23,40 \pm 1,77
minimum-maximum	20,40–31,03
Glaucoma	13 (29,55%)
Pseudo-exfoliation syndrome	7 (15,91%)
Macular degeneration	5 (11,36%)
Blunt trauma to the eyeball	6 (14,63%)
Diabetes mellitus	9 (20,45%)
Marfan syndrome	2 (4,55%)

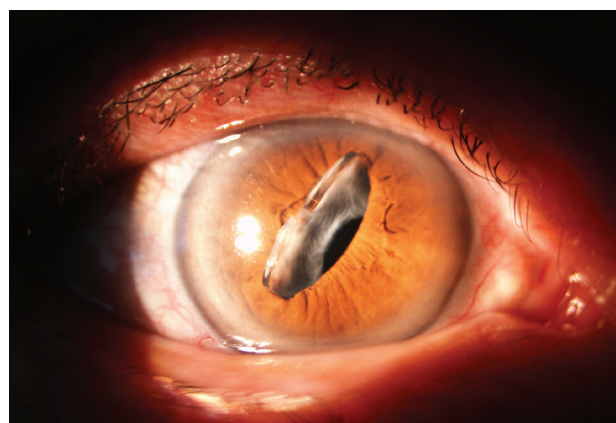
SD (standard deviation)

In twenty-four eyes (54.55%), the posterior chamber IOL was exchanged with an iris-claw IOL in one session. In 15 eyes (34.09%) with aphakia without sufficient capsule support, a secondary iris-claw IOL was implanted. In 5 eyes (11.36%), the procedure of removal of a subluxated or luxated cataract with primary iris-claw IOL was performed. The procedure of iris-claw implantation was combined with the performance of pars plana vitrectomy in 4 eyes, and intracapsular lens extraction in 1 eye.

Indications for the replacement of the implant included the dislocation of the posterior chamber IOL in 22 eyes, the dislocation of the posterior chamber-to the vitreous in 1 eye and calcified membrane on the IOL in 1 eye (Fig. 3). The posterior chamber IOL dislocation was observed in 20 eyes with intracapsular IOL implantation, and 2 eyes with intrascleral fixation of the IOL. The average time between the intracapsular IOL –implantation and its replacement with an Artisan lens was 10.49 ± 7.03 years (minimum 5.53 months – maximum 27.62 years). In two cases of the displacement of the-IOL with intrascleral fixation, the time from the intrascleral fixation of the IOL to iris-claw replacement was 11 years and 6 months and 12 years and 11 months respectively.

FIGURE 3

83-year-old female patient 5 years after surgical right eye posterior chamber IOL cataract surgery, with spontaneous subluxation transfer of the implant into the anterior chamber. The exchange of subluxated IOL to the posterior chamber iris-claw IOL was performed.



Aphakia was the result of a complicated procedure of phacoemulsification of a senile cataract in 12 eyes, removal of a post-traumatic cataract in 2 eyes, and phacoemulsification of a subluxated senile cataract in 1 eye. In patients with aphakia, the average time from the removal of the senile

cataract to iris-claw IOL implantation was 80.38 ± 72.84 days (minimum 12 days, maximum 288 days).

The initial iris-claw implantation was performed after the removal of subluxated cataract in 3 eyes, and in 2 eyes it was done due to post-traumatic dislocation of the opacified lens to the vitreous body.

Statistica 13.3 (Statsoft Polska) was used for statistical analyses. The descriptive statistics module and Wilcoxon signed-rank-test were used and the result was statistically significant for $p < 0.05$.

RESULTS

The best corrected visual acuity at the end of the observation period improved in 26 eyes (59.10%), decreased in 9 eyes (20.45%), and remained unchanged also in 9 eyes (20.45%). There was no statistically different change in the endothelial cell density (cells/mm²) at the end of the follow-up period. Table 2 shows the mean values of the best corrected visual acuity, spherical equivalent, intraocular pressure and endothelial cell density before and after the procedure of iris-claw implantation in 44 examined eyes. The average SE value in the group of 24 eyes in which the posterior chamber IOL was replaced with an iris-claw IOL

was 1.56 ± 3.21 Dsph before the procedure, and 0.45 ± 1.74 Dsph after the procedure. In the group of 15 eyes operated for postoperative aphakia correction, the mean value of SE before surgery was 12.15 ± 1.81 Dsph, and 0.23 ± 1.41 Dsph after surgery. In the remaining five cases, where iris-claw IOL implantation was performed, the mean value of SE before surgery was 5.88 ± 2.92 Dsph, and 0.70 ± 0.86 Dsph after surgery. Table 3 presents average BCVA values before and at the end of the observation period in the three groups of indications for the procedure described. In 40 eyes (90.91%) the refraction error (difference between achieved and attempted refraction) at the end of the observation period was within ± 2 Dsph.

No intraoperative complications were reported during iris-claw lens implantation. Postoperative complications included: pupil ovalization in 10 eyes (22.73%), local atrophy of the iris in 2 eyes (4.55%), iritis in 2 eyes (4.55%), pigment presence on the IOL implant in 3 eyes (6.82%), transient intraocular pressure increase > 25 mmHg in 10 eyes (22.73%), hypotony in 2 eyes (4.55%), iris-claw IOL displacement in 2 eyes (4.55%), cystoid macular edema in 6 eyes (13.64%), retinal detachment in 2 eyes (4.55%), vitreous hemorrhage in 1 eye (2.27%), retinal central vein thrombosis in 1 eye (2.27%), trophic keratitis in 1 eye (2.27%).

TABLE 2

Results of ophthalmic examinations in 44 eyes before and after the surgery of posterior chamber iris-claw IOL implantation .
The p-value for the Wilcoxon signed-rank test.

	Before the procedure	At the end of the observation period	p
BCVA \pm SD (Snellen Table)	$0,36 \pm 0,26$	$0,49 \pm 0,33$	0,04
Minimum-Maximum	rrpo – 1,0	rrpo – 1,0	
Spherical equivalent \pm SD (spherical dioptres)	$5,66 \pm 5,61$	$-0,19 \pm 1,58$	0,00
Minimum; maximum	-5,75; 15,25	-4,75; 3,75	
Intraocular pressure \pm SD (mmHg)	$15,36 \pm 4,87$	$15,07 \pm 4,10$	0,82
Minimum-Maximum	7–31	6–25	
Endothelial cell density \pm SD (mm ²)	$2195,91 \pm 505,05$	$2090,52 \pm 478,39$	0,07
Minimum-Maximum	1532–3311	1489–3257	

BCVA (best-corrected visual acuity)

TABLE 3

Average BCVA values in the three groups of indications for surgery.

	Posterior chamber implant exchange	Postoperative aphakia	Subluxated/luxated cataract
BCVA \pm SD before surgery	$0,37 \pm 0,25$	$0,34 \pm 0,27$	$0,40 \pm 0,32$
Minimum-Maximum	0,02 – 1,0	rrpo – 0,7	rrpo – 0,8
BCVA \pm SD at the end of the observation period	$0,44 \pm 0,32$	$0,47 \pm 0,34$	$0,78 \pm 0,19$
Minimum-Maximum	rrpo – 1,0	rrpo – 1,0	0,5–1,0

DISCUSSION

Among many surgical procedures performed to correct aphakia without sufficient capsule support, the main ones used nowadays are intrascleral fixation of the posterior chamber IOL and iris-claw IOLs implanted in the anterior or posterior chamber of the eye [17]. The possibility of choice of iris-claw implants enables the surgeon to perform the procedure in a shorter time compared to the intrascleral fixation of the IOL, which may result in lower traumatization of eye tissues, and thus, a better procedure safety profile [18, 19]. However, Wu Jing et al., in their meta-analysis comparing the effects of iris-claw IOLs and intrascleral fixation of the posterior chamber IOL in aphakia without sufficient capsule support did not show statistically significant differences in postoperative visual acuity and incidence of postoperative complications between the two techniques [17]. In order to limit the loss of corneal endothelial cells, many researchers prefer the enclavation of the iris-claw IOLs in the posterior chamber due to the longer distance of the implant from the corneal endothelium than in the anterior chamber enclavation [20-22]. However, the results of recently published papers do not confirm that the encapsulation of an iris-claw IOL in the anterior chamber of the eye is associated with significantly higher loss of corneal endothelial cells than fixation in the posterior chamber [3, 23].

In our study, the best corrected visual acuity until the end of the observation period improved in 26 eyes (59.10%), and in 40 eyes (90.91%) the refraction error at the end of the observation period was within ± 2 Dsph. Similar results were described by other researchers in retrospective analyses of the effects of iris-claw implantation into the posterior chamber of the eye [16, 20, 24]. We observed deterioration of BCVA at the end of the observation period in 9 eyes (20.45%), and no change in BCVA also in 9 eyes (20.45%). The causes of worse BCVA at the end of the observation period in our study were: cystoid macular edema (3 eyes), retinal detachment (2 eyes), progression of age-related macular degeneration (1 eye), central retinal vein occlusion (1 eye), trophic keratitis (1 eye) and uveitis (1 eye).

The incidence of CME after surgery with an iris-claw implant into the posterior chamber of the eye is described by researchers in the range of 2.1-25%, depending on the indications for surgery and past eye surgeries [3, 12, 20, 23, 25]. In our study, postoperative CME developed in 6 eyes (13.64%). In four cases, the anti-VEGF (vascular endothelial growth factor) was injected into the vitreous. Two patients did not agree to this treatment, which was the reason for worse BCVA at the end of observation period than before the procedure. Despite the injection of anti-VEGF in one of the four treated patients, no response to the treatment was

obtained, and the final BCVA was worse than before the procedure. In the remaining three treated patients, CME resolved after the intravitreal injection of anti-VEGF. In these three cases BCVA at the end of the observation period, compared to BCVA before the procedure, improved (2 eyes) or did not change (1 eye).

Retinal detachment in our study occurred in two patients, one month and one year after the iris-claw implantation, respectively. The incidence of this complication after posterior chamber implantation of iris-claw IOLs is described by researchers in the range of 0.3-3.2% [15, 23, 26, 27].

After 18 months of observation of a 94-year-old patient, BCVA was worse than before, due to the progression of age-related dry macular degeneration. Optical coherence tomography of the retina showed a widening of the atrophy zone of outer retinal layers in the subfoveal area of the retina. In our opinion, the described changes were not associated with iris-claw IOL implantation. We did not observe any postoperative complications in the patient.

In one patient, a central retinal vein occlusion with macular edema developed one month after the iris-claw implantation. The complication occurred in the eye with high hyperopia, narrow angle primary glaucoma and nonproliferative diabetic retinopathy. Despite the treatment of macular edema with intravitreal anti-VEGF injection, no improvement in visual acuity was achieved.

Trophic keratitis occurred in an 89-year-old patient with recurrent trophic keratitis in the operated eye in the past. The treatment included preparations supporting corneal regeneration, therapeutic contact lenses and eye patching. Due to the formation of post-inflammatory corneal epithelium and stroma opacification, BCVA at the end of the observation period was worse than before the surgery. In our study, inflammation of the anterior part of the choroid occurred in 2 eyes. After application of local steroids, the inflammation subsided in one patient. The second patient developed chronic inflammation of the anterior part of the choroid, which was the reason why the final BCVA was worse than the visual acuity before the procedure. This complication was also described by other researchers [20, 23].

The loss of corneal endothelial cells at the end of the observation period in our study was 4.80% on average. Compared to data from before the surgery, this difference was not statistically significant. Gonnermann et al., in a retrospective study of patients after posterior chamber iris-claw implantation, described endothelial cell loss at 5.5% over the observation period of 34 months [25]. The results of the majority of studies indicate that there is no statisti-

cally significant difference in endothelial cell density before and after the enclavation of iris-claw IOL into the posterior chamber of the eye [21, 22, 26, 27].

In 10 eyes (22.73%), a slight horizontal pupil ovalization at the end of the observation period was observed. This complication, also described by other researchers, may result from asymmetric enclavation of the haptics of the IOL into the iris stroma [20]. The permanent contact of haptics with the iris may be associated with the release of pigment from the stroma, which, when deposited on the IOL surface, may lead to decreased visual acuity [21]. The subconjunctival injection of dexamethasone at the end of surgery may reduce the pigment release from the iris [28]. Schallenberg et al. also described the atrophy of the iris stroma at the site of the enclavation of the haptics in 12.9% of patients [15]. In our study, local atrophy of the iris stroma occurred only in 2 eyes (4.88%), and the presence of pigment dispersion on the implant surface was observed in 3 eyes during the last control visit.

Postoperative IOP elevation higher than >25 mmHg was observed in 10 eyes (22.73%), similarly to the study carried out by Mora et al. [23]. After the use of hypotensive drugs in the form of eye drops, IOP normalized in 8 eyes; in two cases, trabeculectomy was necessary to perform due to persistently high IOP. In Both patients have been treated for many years for narrow angle glaucoma, and additionally 1 eye had high hyperopia. The incidence of postoperative hypotony after posterior chamber iris-claw IOL implantation is described in the literature in the range of 1.63-5.1% [20, 25, 29]. In our study, a temporary IOP decrease < 7 mmHg occurred after surgery in 1 eye (2.44%).

In 2 eyes (4.88%), a dislocation of the iris-claw IOL to the vitreous was observed. In the first patient, this complication occurred in an 18-year-old patient 10 months after the sur-

gery. The implantation of the iris-claw IOL in this patient case was performed due to the dislocation of the posterior chamber IOL, which was implanted after the removal of the traumatic cataract. In the second case, the intravitreal dislocation of the iris-claw IOL occurred one month after the surgery. The complication appeared in an amblyopic eye with nystagmus and high myopia. The implantation of the iris-claw lens was performed in this patient due to the dislocation of the posterior chamber IOL, which was implanted after removal of the congenital cataract. The frequency of displacement of the posterior chamber iris-claw implant is described by other researchers as 0-10% [14, 16, 20, 26].

Rüfer et al. described the incidence of intravitreal hemorrhages at 10% in patients after posterior chamber fixation of the iris-claw IOLs [14]. However, this complication has not been reported in other studies [16, 23, 26]. In our study, the vitreous hemorrhage occurred in one eye of the patient after endophthalmitis, which took place 10 years before implantation. After the application of vasoconstricting drugs, blood resorbed completely without leaving permanent consequences. We did not report any cases of postoperative wound leakage or intraocular inflammation, which were described by other researchers [20].

SUMMARY

The main limitations of our study are the short period of observation and the small number of analyzed cases. Although iris-claw implants are now commonly used for the correction of aphakia without sufficient capsule support, there is still no consensus as to whether they are a safer surgical procedure than intraocular fixation of the implant, especially in terms of postoperative macular edema. The functional results and complications after iris-claw implantation described by us provide information helpful in qualifying patients for this type of procedure.

CORRESPONDENCE:

lek. Ilona A. Kaczmarek

Klinika Okulistyki,
Wojskowy Instytut Medycyny Lotniczej
01-755 Warszawa, ul. Krasińskiego 54/56
e-mail: ikaczmar@wiml.waw.pl

ORCID:

Ilona A. Kaczmarek – ID – <https://orcid.org/0000-0003-0354-8437>

References

1. Worst JG, Massaro RG, Ludwig HH. The introduction of an artificial lens into the eye using Binkhorst's technique. *Ophthalmologica*. 1972; 164(5): 387-91.
2. Jezierski M, Kaczmarek I, Prost ME. Zastosowanie implantów soczewek wewnątrzgałkowych typu iris-claw u pacjentów z bezsoczewkowością. *Ophtha Therapy*. 2014; 4(4): 1-5.
3. Toro MD, Longo A, Avitabile T et al. Five-year follow-up of secondary iris-claw intraocular lens implantation for the treatment of aphakia: Anterior chamber versus retropupillary implantation. *PLoS ONE* 2019; 14(4): e0214140.
4. Stem MS, Todorich B, Woodward MA et al. Scleral-Fixated Intraocular Lenses: Past and Present. *J Vitreoretin Dis*. 2017; 1(2): 144-52.
5. Walia S, Kashyap S, Bhaisare V et al. Novel technique of sutureless glueless scleral fixated intraocular lens (SFIOL). *Indian J Ophthalmol*. 2019; 67(1): 64-8.
6. Can E. Flapless and sutureless intrascleral fixation of posterior chamber intraocular lens for correction of aphakia. *J Cataract Refract Surg*. 2018; 44(8): 929-31.
7. Dinc E, Vatansever M, Dursun Ö et al. Scleral fixated intraocular lens implantation with a modified Z-suture technique. *Int Ophthalmol*. 2018; 38(6): 2357-61.
8. Saleh M, Heitz A, Bourcier T et al. Sutureless intrascleral intraocular lens implantation after ocular trauma. *J Cataract Refract Surg*. 2013; 39(1): 81-6.
9. Wallmann AC, Monson BK, Adelberg DA. Transscleral fixation of a foldable posterior chamber intraocular lens. *J Cat Refract Surg*. 2015; 41(9): 1804-9.
10. Obeng FK, Vig VK, Singh P et al. Posterior Chamber Scleral Fixation of Intraocular Lenses in Post-Vitrectomised Aphakic Eyes. *J Clin Diagn Res*. 2017; 11(3): NC09-13.
11. Yang C, Chao Y. Long-term outcome of combined vitrectomy and transscleral suture fixation of posterior chamber intraocular lenses in the management of posteriorly dislocated lenses. *J Chin Med Assoc*. 2016; 79(8): 450-5.
12. Jayamadhury G, Potti S, Kumar KV et al. Retropupillary fixation of iris-claw lens in visual rehabilitation of aphakic eyes. *Indian J Ophthalmol*. 2016; 64(10): 743-6.
13. De Silva SR, Arun K, Anandan M et al. Iris-claw intraocular lenses to correct aphakia in the absence of capsule support. *J Cataract Refract Surg*. 2011; 37(9): 1667-72.
14. Rüfer F, Saeger M, Nölle B et al. Implantation of retropupillar iris claw lenses with and without combined penetrating keratoplasty. *Graefes Arch Clin Exp Ophthalmol*. 2009; 247(4): 457-62.
15. Schallenberg M, Dekowski D, Hahn A et al. Aphakia correction with retropupillary fixated iris-claw lens (Artisan) – long-term results. *Clin Ophthalmol*. 2014; 8: 137-41.
16. Mohr A, Hengerer F, Eckardt C. Retropupillary fixation of the iris claw lens in aphakia. 1 year outcome of a new implantation techniques. *Ophthalmologe*. 2002; 99(7): 580-3.
17. Jing W, Guanlu L, Qianyin Z et al. Iris-Claw Intraocular Lens and Scleral-Fixated Posterior Chamber Intraocular Lens Implantations in Correcting Aphakia: A Meta-Analysis. *Invest Ophthalmol Vis Sci*. 2017; 58(9): 3530-6.
18. Teng H, Zhang H. Comparison of Artisan iris-claw intraocular lens implantation and posterior chamber intraocular lens sulcus fixation for aphakic eyes. *Int J Ophthalmol*. 2014; 7(2): 283-7.
19. Hara S, Borkenstein AF, Ehmer A et al. Retropupillary fixation of iris-claw intraocular lens versus transscleral suturing fixation for aphakic eyes without capsular support. *J Refract Surg*. 2011; 27(10): 729-35.
20. Gonnermann J, Klamann MK, Maier AK et al. Visual outcome and complications after posterior iris-claw aphakic intraocular lens implantation. *J Cataract Refract Surg*. 2012; 38(12): 2139-43.
21. Baykara M, Ozcetin H, Yilmaz S et al. Posterior iris fixation of the iris-claw intraocular lens implantation through a scleral tunnel incision. *Am J Ophthalmol*. 2007; 144(4): 586-91.
22. Gicquel JJ, Guigou S, Bejjani RA et al. Ultrasound biomicroscopy study of the Verisyse aphakic intraocular lens combined with penetrating keratoplasty in pseudophakic bullous keratopathy. *J Cataract Refract Surg*. 2007; 33(3): 455-64.
23. Mora P, Calzetti G, Favilla S et al. Comparative Analysis of the Safety and Functional Outcomes of Anterior versus Retropupillary Iris-Claw IOL Fixation. *J Ophthalmol*. 2018; 2018: 8463569.
24. Schmidt I, Langenbucher A, Moussa S et al. Retroiridale Implantation einer Verisyse™ Irisklauenlinse. Retroiridal implantation of a Verisyse™ iris claw lens. *Der Ophthalmol*. 2014; 112(3): 261-5.
25. Gonnermann J, Amiri S, Klamann M et al. Endothelial cell loss after retropupillary iris-claw intraocular lens implantation. *Klin Monbl Augenheilkd*. 2014; 231(8): 784-7.
26. Wolter-Roessler M, Küchle M. Correction of aphakia with retroiridally fixated IOL. *Klin Monbl Augenheilkd*. 2008; 225(12): 1041-4.
27. Forlini M, Soliman W, Bratu A et al. Long-term follow-up of retropupillary iris-claw Intraocular lens implantation: a retrospective analysis. *BMC Ophthalmol*. 2015; 15: 143.
28. Dick HB, Budo C, Malecaze F et al. Foldable Artiflex phakic intraocular lens for the correction of myopia: two-year follow-up results of a prospective European multicenter study. *Ophthalmology*. 2009; 116(4): 671-7.
29. Jayamadhury G, Potti S, Kumar KV et al. Retropupillary fixation of iris-claw lens in visual rehabilitation of aphakic eyes. *Indian J Ophthalmol*. 2016; 64(10): 743-6.

For non-commercial use only

Authors' contributions:

All authors contributed equally to the article.

Conflict of interest:

None.

Financial support:

None.

Ethics:

The content presented in the article complies with the principles of the Helsinki Declaration, EU directives and harmonized requirements for biomedical journals.